

## COURSE ON LIVER TUMORS

# Hepatocellular adenoma Focal nodular hyperplasia Bile duct adenoma

**Prof. Dr. ANNE HOORENS**

**BSP - Working Group Digestive Pathology – 3 DEC 2022**



# Hepatocellular adenoma

Let's start with a little bit of history

## Benign hepatocellular lesions: 1980s

- **Hepatocellular adenoma**
- **Focal nodular hyperplasia**

	<b>HCA</b>	<b>FNH</b>
Central scar	Absent	Present
Fibrous septa	Typically absent	Typically present
Nodular architecture	Absent	Present
Ductular reaction	Absent	Generally prominent
Clonality	Monoclonal	Polyclonal

## Benign hepatocellular lesions: 1980s

- **Hepatocellular adenoma**
- **Focal nodular hyperplasia**

	<b>HCA</b>	<b>FNH</b>
Central scar	Absent	Present
Fibrous septa	<del>Typically absent</del>	Typically present
Nodular architecture	Absent	Present
Ductular reaction	<del>Absent</del>	Generally prominent
Clonality	Monoclonal	Polyclonal

*Not always true*



## Benign hepatocellular lesions: 1990s

- **Hepatocellular adenoma**
- **Focal nodular hyperplasia**

### **Telangiectatic FNH**

Multiple focal nodular hyperplasia of the liver associated with vascular malformations of various organs and neoplasia of the brain: a new syndrome.

Wanless IR et al, Mod Pathol. 1989;2:456-62.

## Benign hepatocellular lesions: 2004

### ▪ Hepatocellular adenoma Telangiectatic HCA

**Telangiectatic focal nodular hyperplasia: a variant of hepatocellular adenoma.**

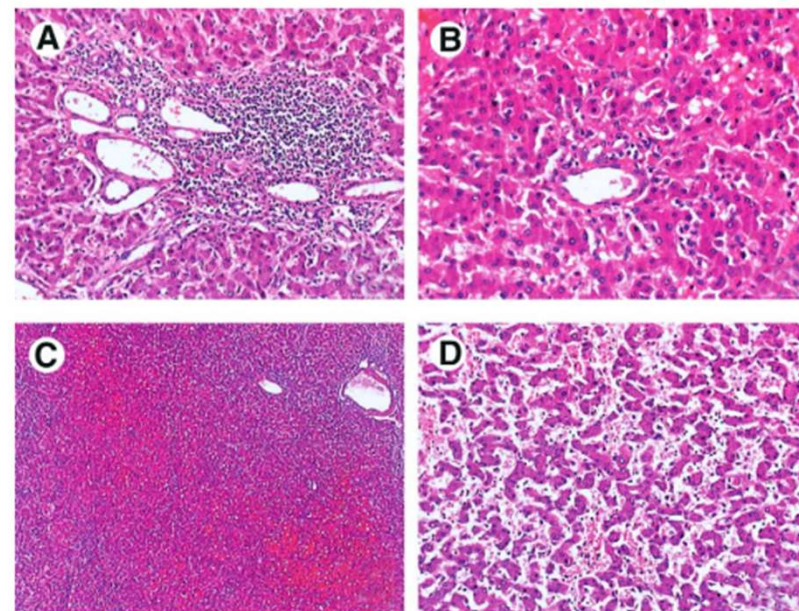
Paradis V et al. Gastroenterology. 2004;126:1323-9

- Clonality studies: monoclonal
- Protein profiling: cluster with adenoma
- Imaging: resembles adenoma

Reclassified as telangiectatic adenoma

- Ductular reaction
- Fibrous septa with dystrophic arterioles
- Telangiectasia, inflammatory infiltrate

### ▪ Focal nodular hyperplasia



## Benign hepatocellular lesions: 2006

### ▪ **Hepatocellular adenoma**

#### **Classification based on genetic changes**

### **Genotype–Phenotype Correlation in Hepatocellular Adenoma: New Classification and Relationship With HCC**

Jessica Zucman-Rossi,<sup>1</sup> Emmanuelle Jeannot,<sup>1</sup> Jeanne Tran Van Nhieu,<sup>2</sup> Jean-Yves Scoazec,<sup>3</sup> Catherine Guettier,<sup>4</sup> Sandra Rebouissou,<sup>1</sup> Yannick Bacq,<sup>5</sup> Emmanuelle Leteurtre,<sup>6</sup> Valérie Paradis,<sup>7</sup> Sophie Michalak,<sup>8</sup> Dominique Wendum,<sup>9</sup> Laurence Chiche,<sup>10</sup> Monique Fabre,<sup>11</sup> Lucille Mellotée,<sup>1</sup> Christophe Laurent,<sup>12</sup> Christian Partensky,<sup>3</sup> Denis Castaing,<sup>4</sup> Elie Serge Zafrani,<sup>2</sup> Pierre Laurent-Puig,<sup>13</sup> Charles Balabaud,<sup>12,14</sup> and Paulette Bioulac-Sage<sup>14,15</sup>

Hepatology 2006;43:515-24.

### ▪ **Focal nodular hyperplasia**

## Benign hepatocellular lesions: 2007

- **Hepatocellular adenoma**

**Classification based on genetic changes**

**Simple and robust immunohistochemistry for classification of hepatocellular adenomas**

### **Hepatocellular Adenoma Subtype Classification Using Molecular Markers and Immunohistochemistry**

Paulette Bioulac-Sage,<sup>\*1,2</sup> Sandra Rebouissou,<sup>\*3,4</sup> Cristel Thomas,<sup>3,4</sup> Jean-Frédéric Blanc,<sup>2,5</sup> Jean Saric,<sup>6</sup> Antonio Sa Cunha,<sup>6</sup> Anne Rullier,<sup>1,2</sup> Gaëlle Cubel,<sup>2</sup> Gabrielle Couchy,<sup>3,4</sup> Sandrine Imbeaud,<sup>7</sup> Charles Balabaud,<sup>2,5</sup> and Jessica Zucman-Rossi<sup>3,4</sup>

Hepatology 2007;46:740-8.

- **Focal nodular hyperplasia**

# Benign hepatocellular lesions: 2017

# TODAY

## ▪ Hepatocellular adenoma

**Revised molecular classification: 8 subgroups**

**Various HCA risk factors, risk for malignant transformation and bleeding**

### **Molecular Classification of Hepatocellular Adenoma Associates With Risk Factors, Bleeding, and Malignant Transformation**

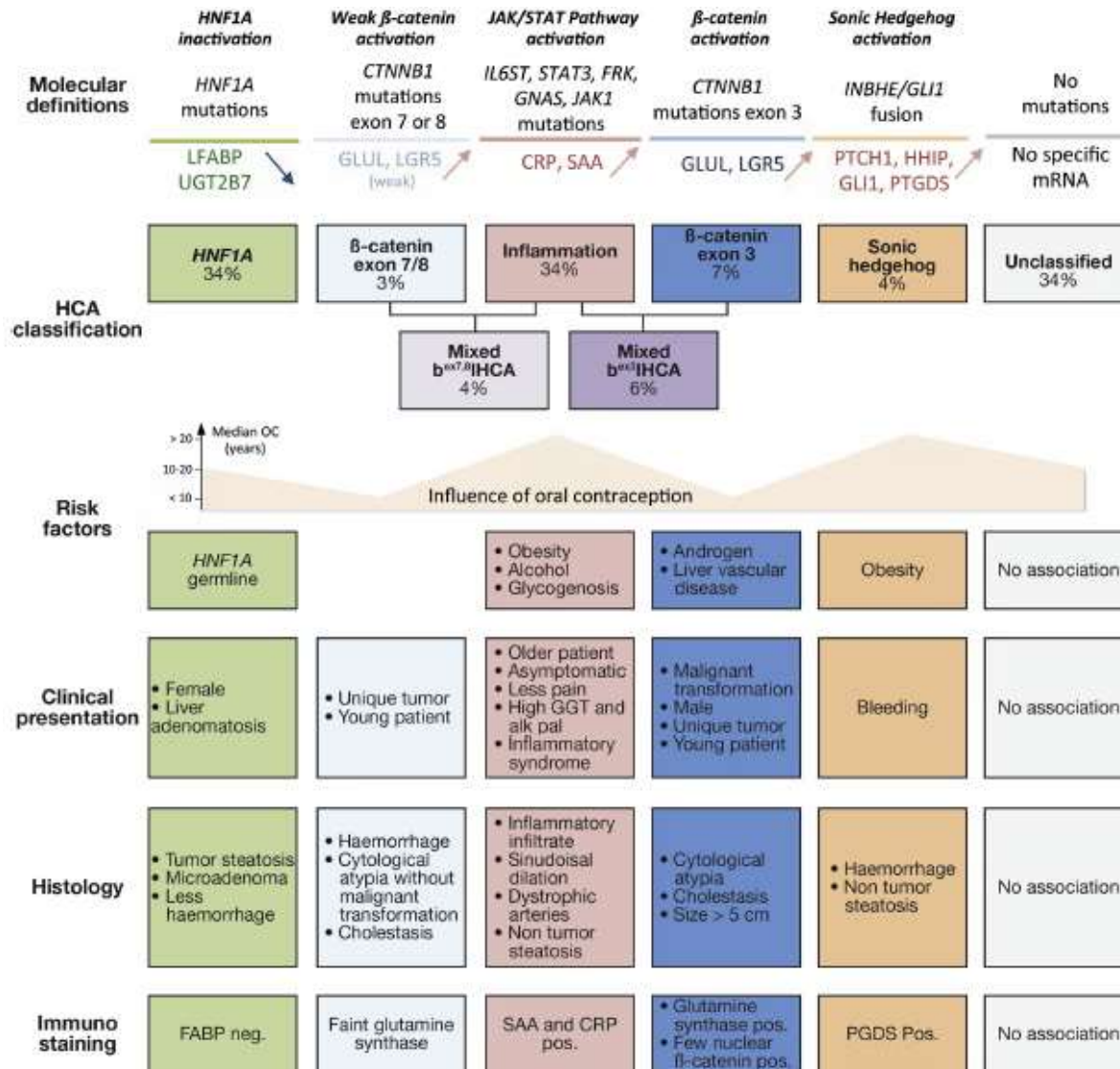


Jean-Charles Nault,<sup>1,2,3</sup> Gabrielle Couchy,<sup>1</sup> Charles Balabaud,<sup>4</sup> Guillaume Morcrette,<sup>1</sup>  
Stefano Caruso,<sup>1</sup> Jean-Frederic Blanc,<sup>4,5</sup> Yannick Bacq,<sup>6</sup> Julien Calderaro,<sup>1,7</sup> Valérie Paradis,<sup>8</sup>  
Jeanne Ramos,<sup>9</sup> Jean-Yves Scoazec,<sup>10</sup> Viviane Gnemmi,<sup>11</sup> Nathalie Sturm,<sup>12</sup>  
Catherine Guettier,<sup>13</sup> Monique Fabre,<sup>14</sup> Eric Savier,<sup>15</sup> Laurence Chiche,<sup>16</sup> Philippe Labrune,<sup>17</sup>  
Janick Selves,<sup>18</sup> Dominique Wendum,<sup>19</sup> Camilla Pilati,<sup>1</sup> Alexis Laurent,<sup>20</sup> Anne De Muret,<sup>21</sup>  
Brigitte Le Bail,<sup>4,22</sup> Sandra Rebouissou,<sup>1</sup> Sandrine Imbeaud<sup>1</sup>; GENTHEP Investigators,  
Paulette Bioulac-Sage,<sup>4,22</sup> Eric Letouzé,<sup>1</sup> and Jessica Zucman-Rossi<sup>1,23</sup>

*Gastroenterology* 2017;152:880-894.

## ▪ Focal nodular hyperplasia

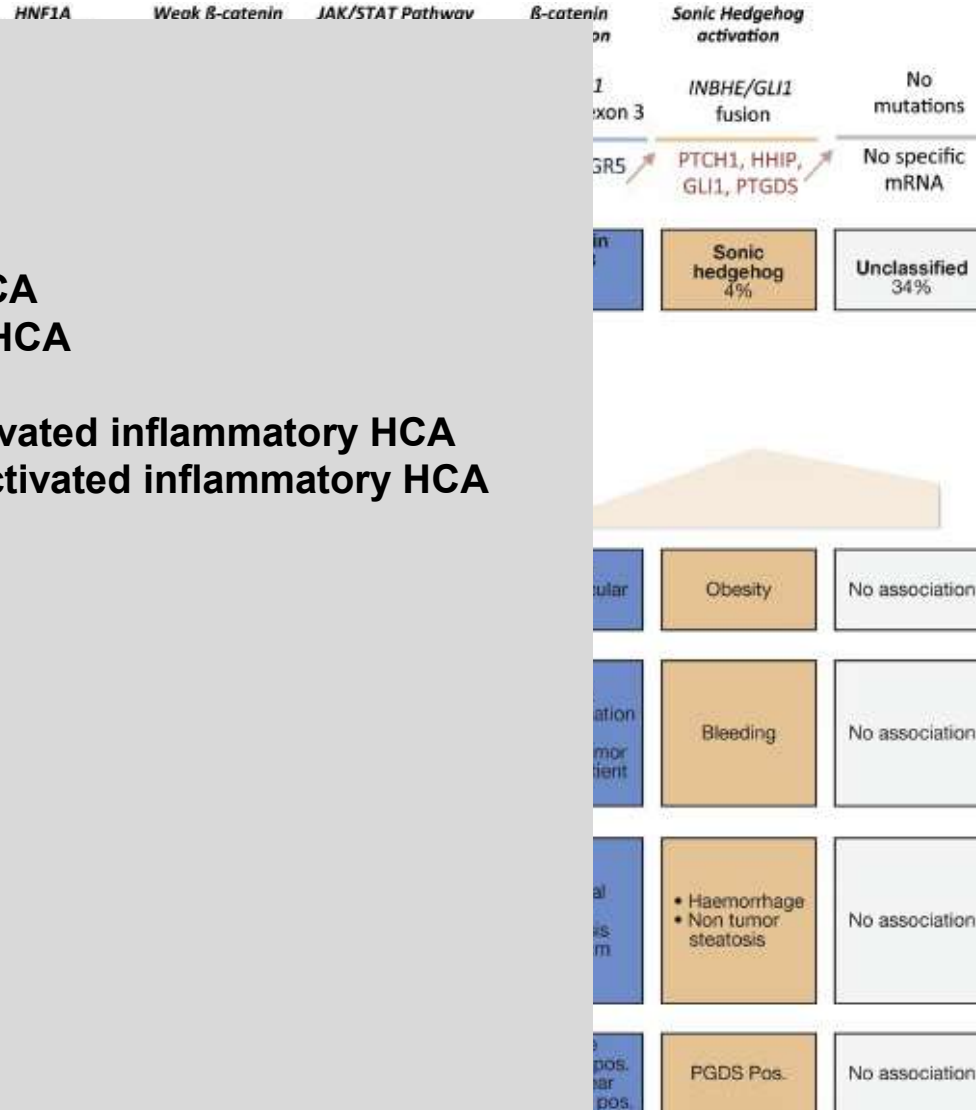




Gastroenterology 2017;152:880-894.

## Subtypes

- HNF1A-inactivated HCA
- $\beta$ -catenin-exon 3-activated HCA
- $\beta$ -catenin-exon 7/8-activated HCA
  - $\beta$ -catenin-exon 3-activated inflammatory HCA
  - $\beta$ -catenin-exon 7/8-activated inflammatory HCA
- Inflammatory HCA
- Sonic hedgehog HCA
- Unclassified HCA



## HCA epidemiology/clinical characteristics

- 3-4/100000 person-years in Europe/North America
- 85% in women of childbearing age  
Rare in children, men, and people aged >65y
- Most incidentally discovered on imaging  
Can present with abdominal pain, palpable mass, or hemorrhage
- Clinically significant hemorrhage (20-25%)  
Mainly in tumors >5 cm
- Transformation to HCC uncommon (4-8%)
- Single or multiple (if  $\geq 10$  adenomatosis)



## HCA etiology

- Oral contraception major risk factor
- Men using anabolic steroids for body building also at risk  
Patients taking anabolic steroids or androgens for aplastic anemia
- Other risk factors: glycogenosis type 1 and 3, galactosemia, tyrosinemia, FAP, PCO,  $\beta$ -thalassemia
- Recent increase attributed to obesity/metabolic syndrome

## HCA macroscopy

- Soft, poorly defined, no fibrous capsule
- Necrosis, hemorrhage, fibrosis possible
- Microscopic to >20 cm
  
- Non-cirrhotic liver
- Inflammatory HCA (IHCA) described in ASH/NASH cirrhosis

## HCA histopathology

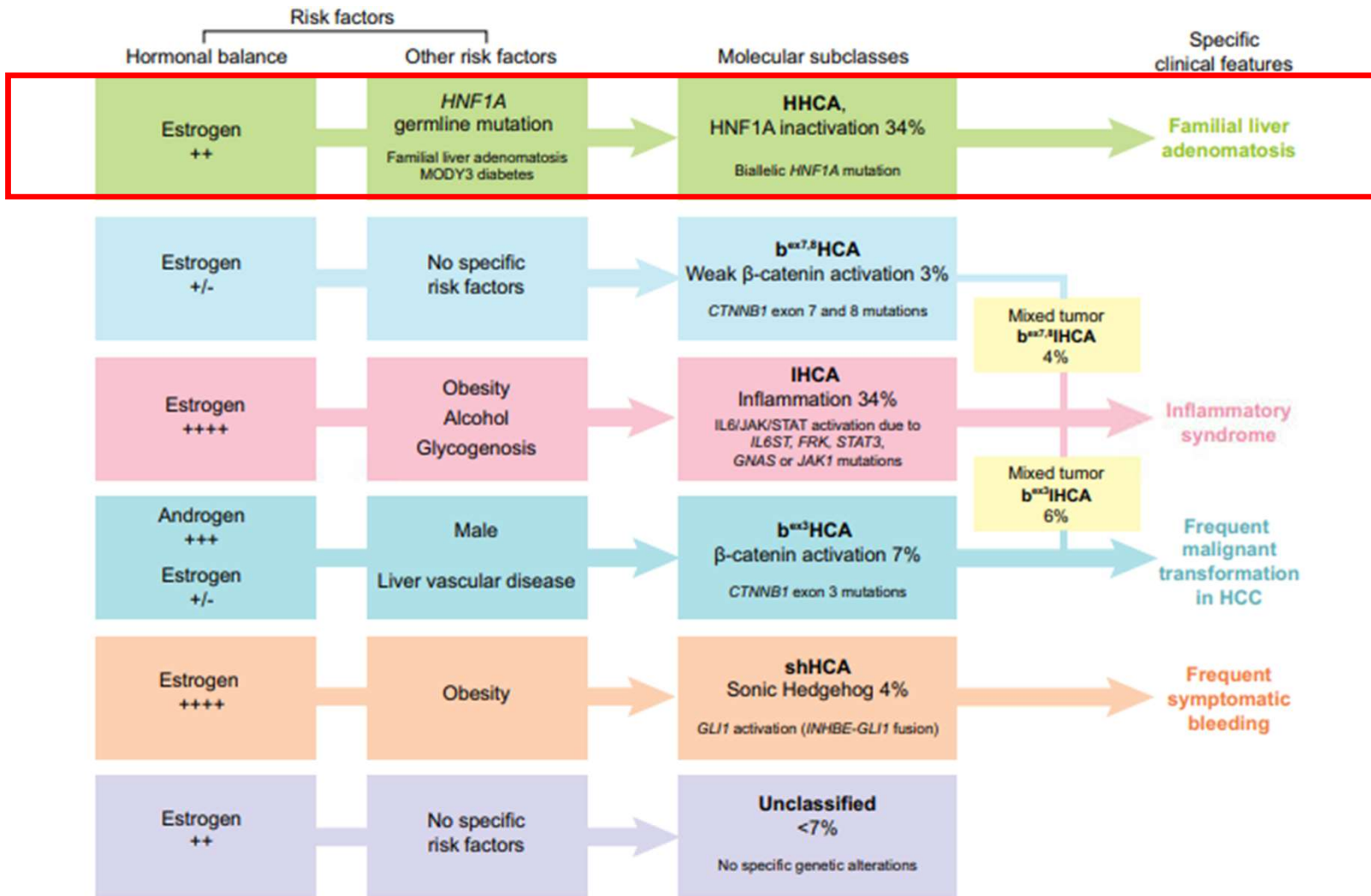
- Hepatocytes arranged in 1-2 cells thick plates  
Occasional pseudoglands
- No portal tracts
- Isolated arteries
- Cytoplasm normal, clear, or steatotic  
Can contain pigment (lipofuscin, bile)
- Mild nuclear atypia (may be related to ischemic changes)
- Mitoses unusual

## HCA pathogenesis

- Clonal tumors
- Classified into several molecular subtypes, which have important consequences for patient management
  - Each molecular subtype has morphological hallmarks
- **Different molecular subtypes can occur in same liver**

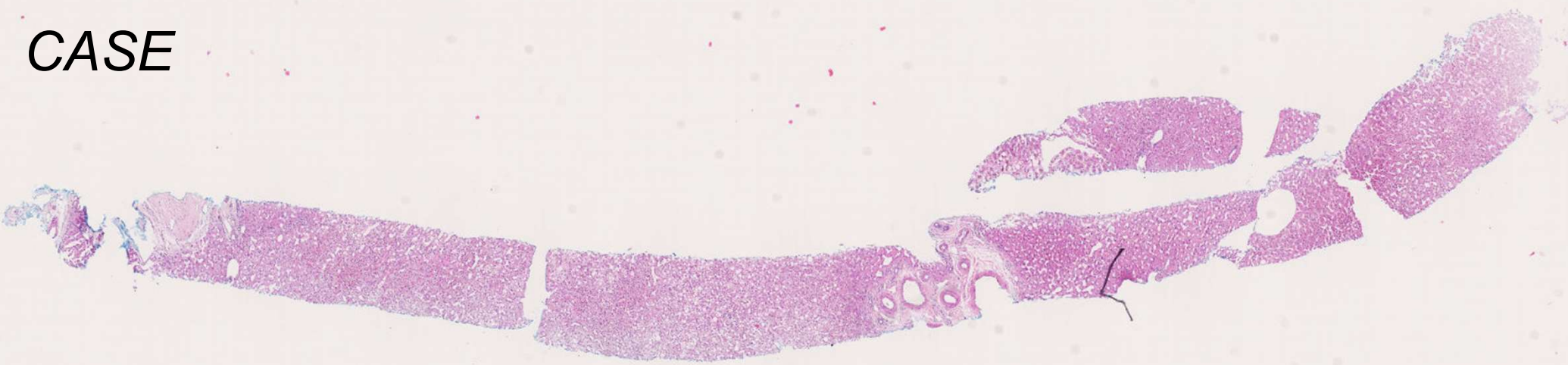
## HNF1A-inactivated HCA (HHCA) 30-35% of all HCAs

- Diffuse steatosis, ballooned cells, occasional pseudoglands  
Microadenomas often present in background liver  
Some atypical cases have no/minor steatosis, rarely a myxoid stroma
- Biallelic inactivation of HNF1A gene coding for fatty-acid binding protein
- FABP is expressed in cytoplasm of normal hepatocytes and downregulated in HHCA  
Lack of FABP expression by IHC useful diagnostic marker




**Fig. 2. The genotype/phenotype classification of hepatocellular adenomas (HCAs).** The main molecular subtypes of HCA linked with specific risk factors, clinical features and risk of complications were represented. Mixed forms between inflammatory HCA (IHCA) and  $\beta$ -catenin exon 3 mutated HCA, and between IHCA and  $\beta$ -catenin mutated HCA exon 7/8 have been described.

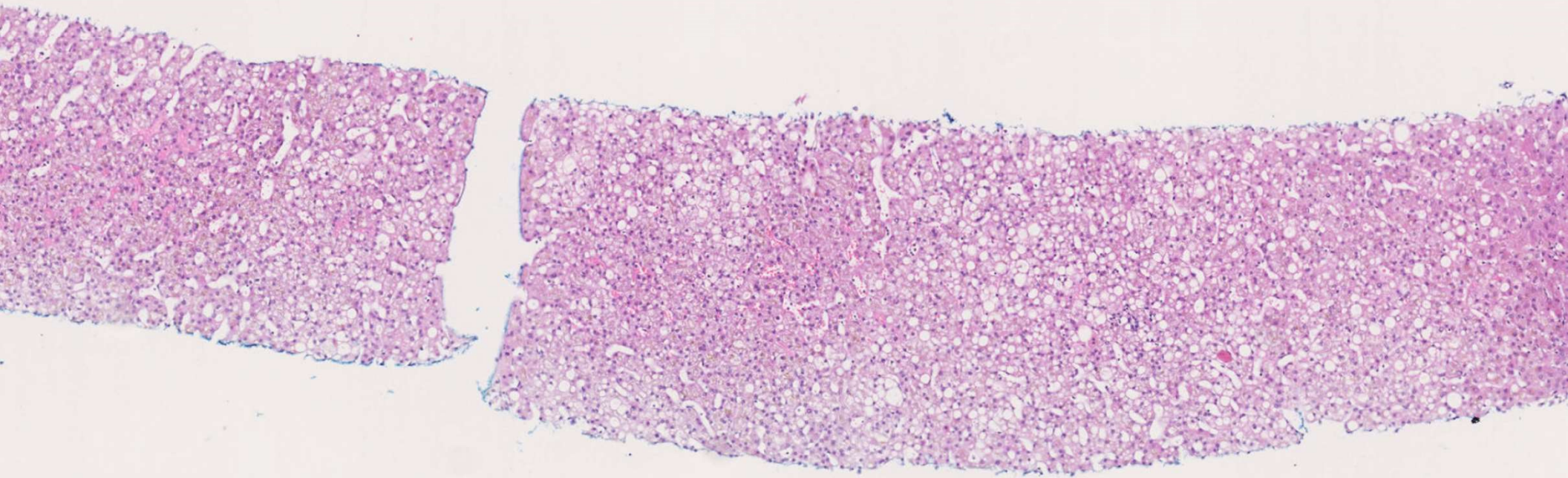
**CASE**



2,5 mm

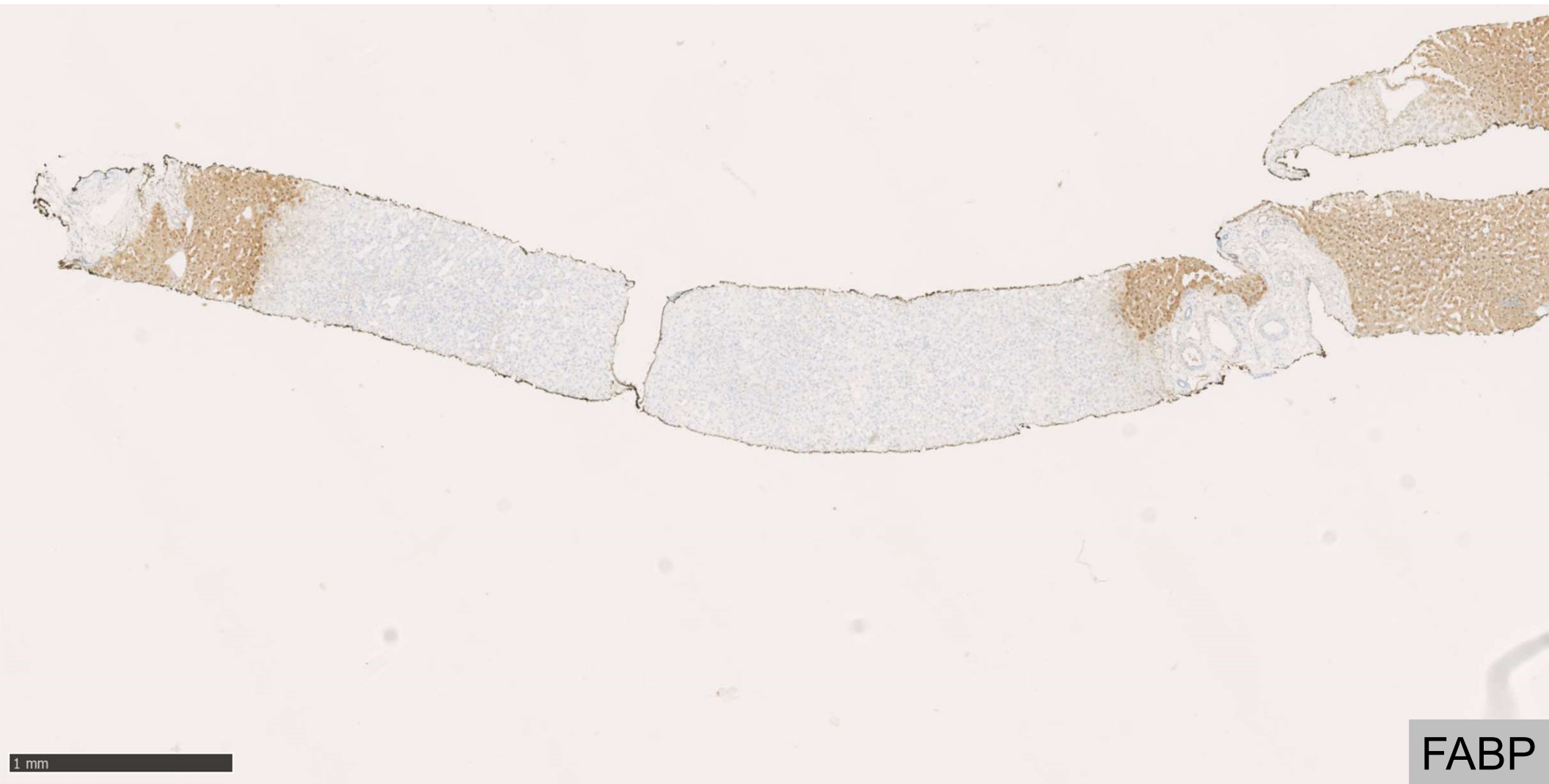



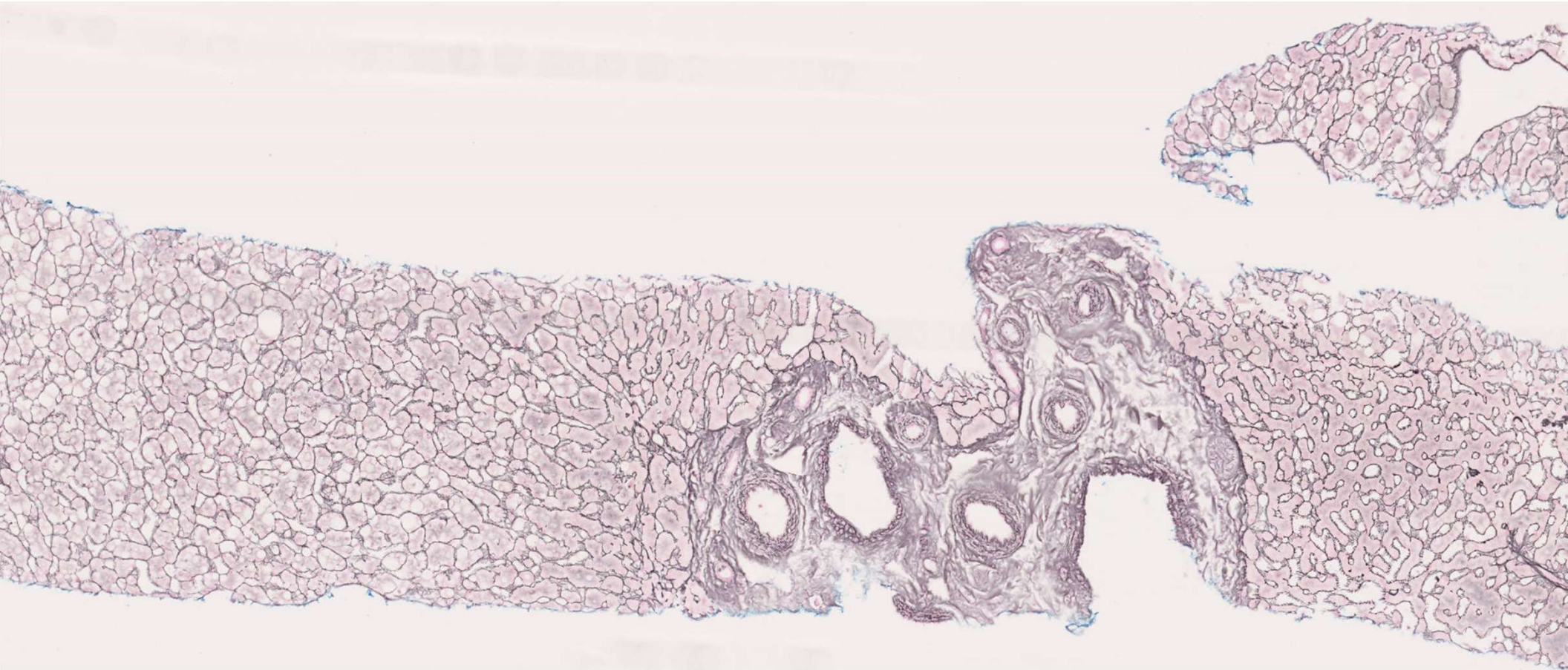


500  $\mu$ m





FABP



500  $\mu\text{m}$

# *Diagnosis*

- HHCA
- NGS
  - HNF1A 2x putative pathogenic variant
  - No variants in CTNNB1 (exon 3, 7, 8), TERT promoter, IL6ST, STAT3, FRK, GNAS, JAK1



Available online at  
**ScienceDirect**  
[www.sciencedirect.com](http://www.sciencedirect.com)

Elsevier Masson France  
**EM|consulte**  
[www.em-consulte.com/en](http://www.em-consulte.com/en)



CASE REPORT

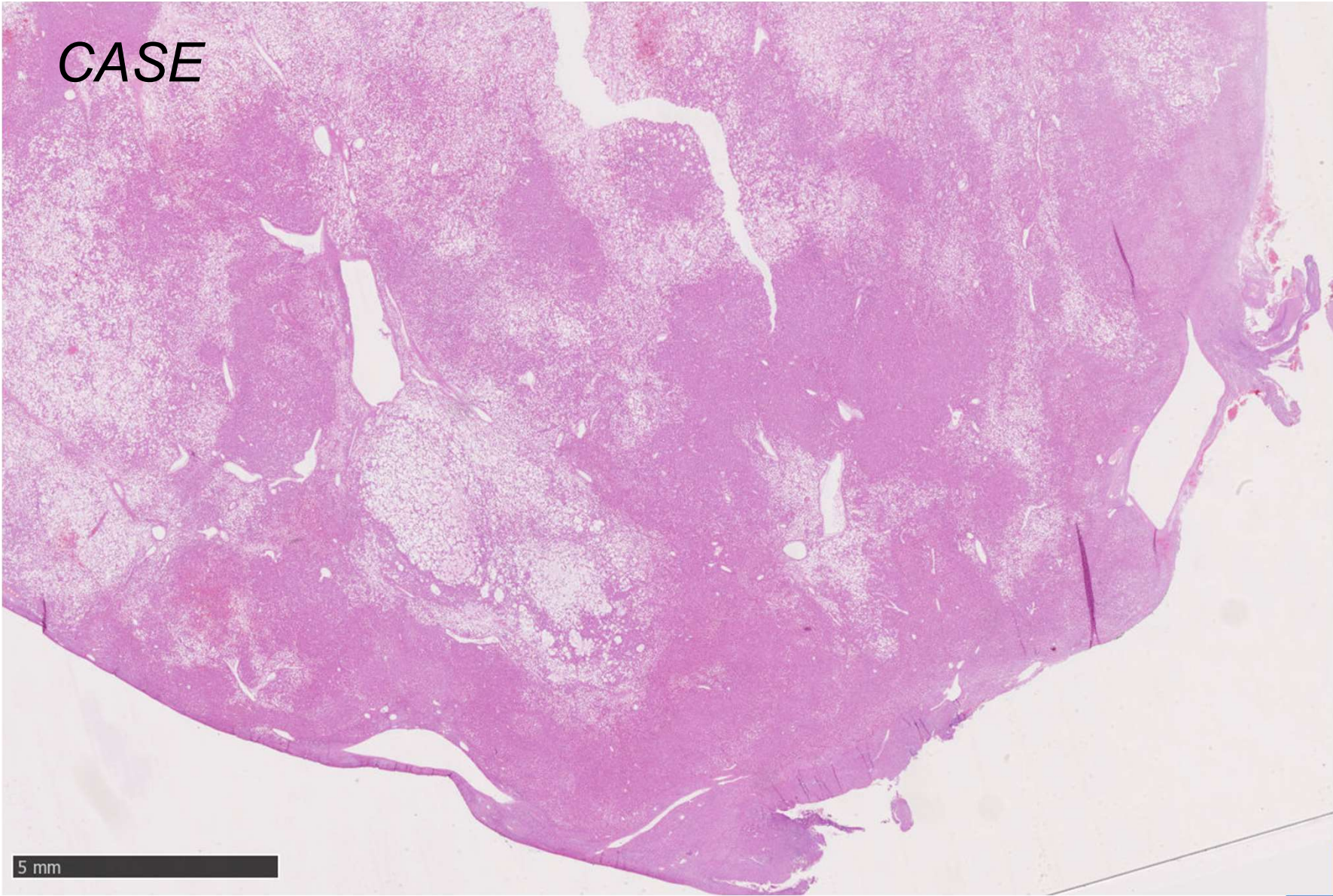
## Myxoid hepatocellular adenoma, a rare variant of hepatocellular adenoma with distinct imaging features: A case report with immunohistochemical and molecular analysis and literature review



Nicolas De Vos<sup>a</sup>, Joni Van der Meulen<sup>b</sup>,  
Malaïka Van Der Linden<sup>c</sup>, Kathleen Claes<sup>b</sup>,  
Ann-Sophie Candaele<sup>c</sup>, Aude Vanlander<sup>d</sup>,  
Roberto Ivan Troisi<sup>e,1</sup>, Hans Van Vlierberghe<sup>f</sup>, Peter Smeets<sup>a</sup>,  
Jo Van Dorpe<sup>c</sup>, Anne Hoorens<sup>c,4</sup>

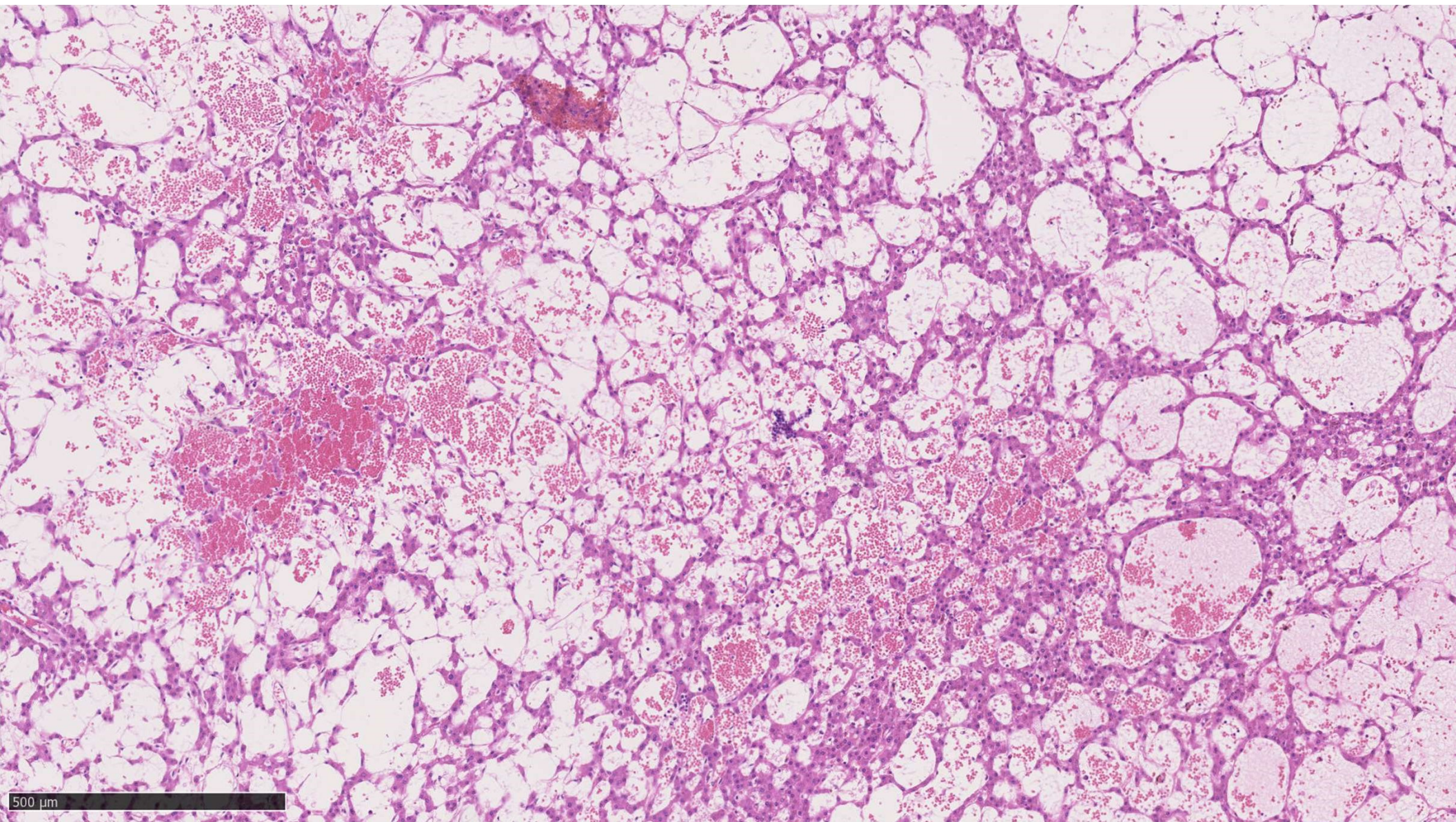


**CASE**



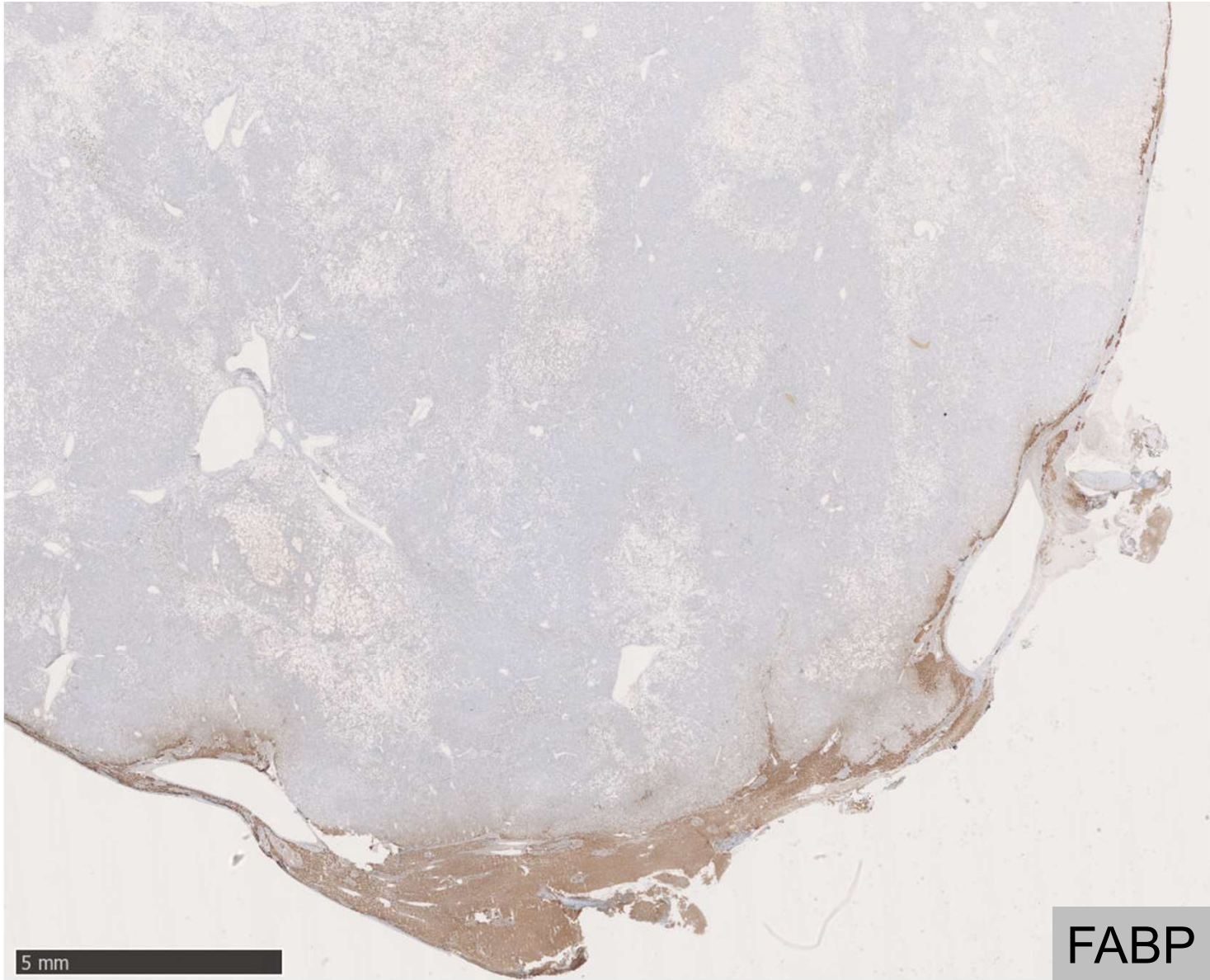
5 mm





500 μm





5 mm

FABP

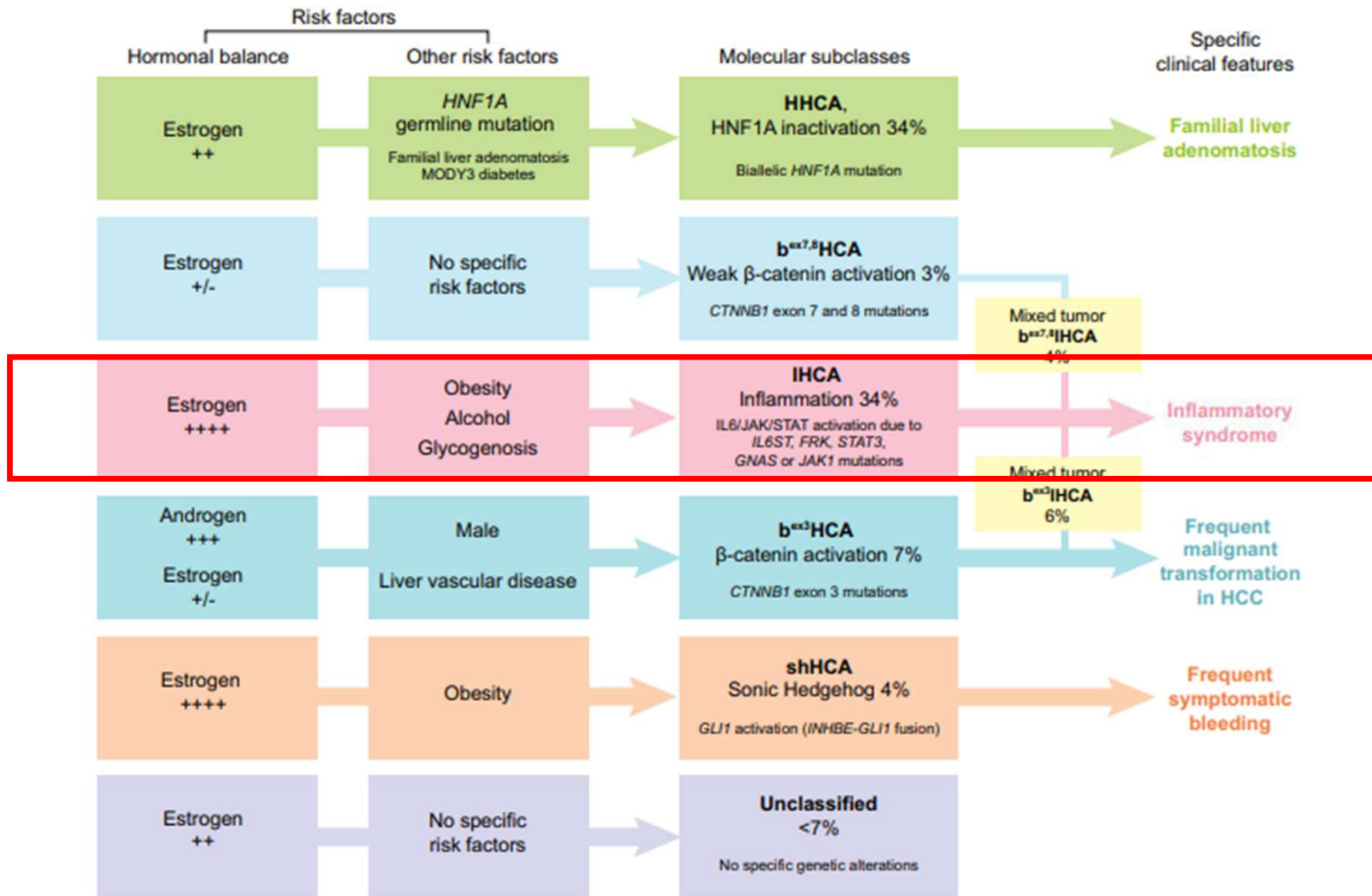
## *Diagnosis*

- HHCA
  
- NGS
  - HNF1A putative pathogenic variant
  - No variants in CTNNB1 (exon 3, 7, 8), TERT promoter, IL6ST, STAT3, FRK, GNAS, JAK1



## Inflammatory-HCA (IHCA) 35-40% of all HCAs

- Sinusoidal dilatation, foci of inflammation, thick arteries, ductular reaction leading to aspect of pseudoportal tracts “*telangiectatic HCA*”  
Focal steatosis not rare  
Fibrotic bands/nodular organization due to remodeling (can be misleading)
- Somatic activating mutations in genes involved in IL-6/JAK/STAT3 pathway  
IL6ST (gp130), FRK, STAT3, GNAS or JAK1 mutations
- Increased expression of inflammation-associated proteins  
Serum amyloid A (SAA) and/or C-reactive protein (CRP)



**Fig. 2. The genotype/phenotype classification of hepatocellular adenomas (HCAs).** The main molecular subtypes of HCA linked with specific risk factors, clinical features and risk of complications were represented. Mixed forms between inflammatory HCA (IHCA) and  $\beta$ -catenin exon 3 mutated HCA, and between IHCA and  $\beta$ -catenin mutated HCA exon 7/8 have been described.

**$\beta$ -catenin-activated HCA (bHCA) 10% of all HCAs**

- Some have atypia, pseudoglands, pigments (lipofuscin, bile)
- Mutation/deletion of CTNNB1 (encoding  $\beta$ -catenin) results in activation of WNT/ $\beta$ -catenin signaling pathway
- Nuclear  $\beta$ -catenin can be identified by IHC  
Can be focal or even absent (low sensitivity)!!!

CTNNB1 mutations induce nuclear translocation of  $\beta$ -catenin



Acts as a co-transcription factor with T cell factor (TCF)



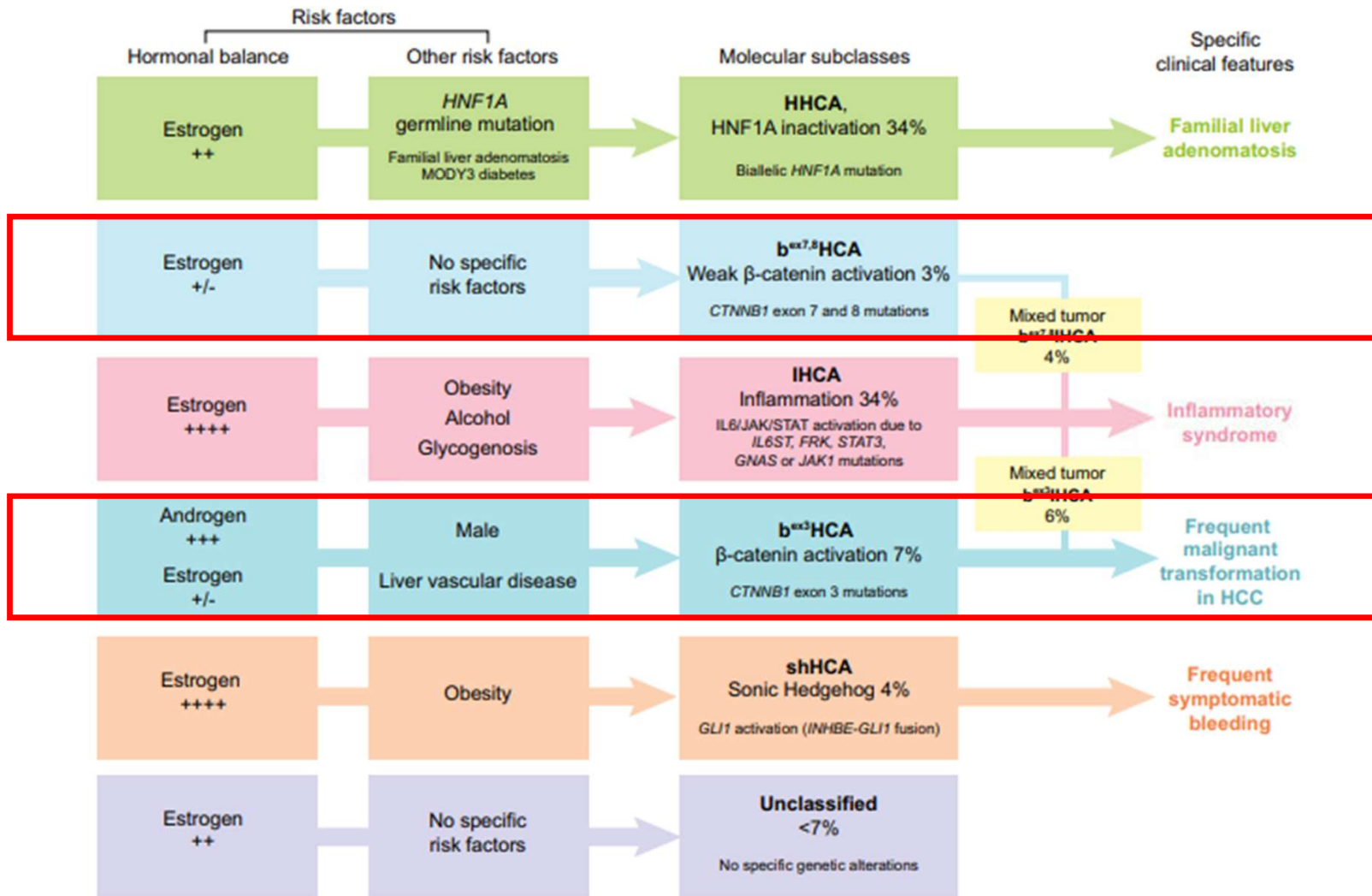
Strong induction of expression of WNT/ $\beta$ -catenin target genes  
e.g. glutamate-ammonia ligase (GLUL)



GLUL codes for **glutamine synthase (GS)**

- Mutations leading to strong  $\beta$ -catenin activation  
Large deletions + most hotspot mutations in exon 3  
→ Diffuse homogeneous GS staining
- Mutations leading to moderate  $\beta$ -catenin activation  
e.g., exon 3 S45 mutation  
→ Tends to diffuse heterogeneous GS staining (starry-sky pattern)
- Mutations leading to weak  $\beta$ -catenin activation  
Most mutations in exon 7/8  
→ Weak patchy GS staining
- Exon 3 S45 and exon 7/8 mutation  
Can show strong peripheral border GS staining  
CD34 is usually diffusely expressed except at border

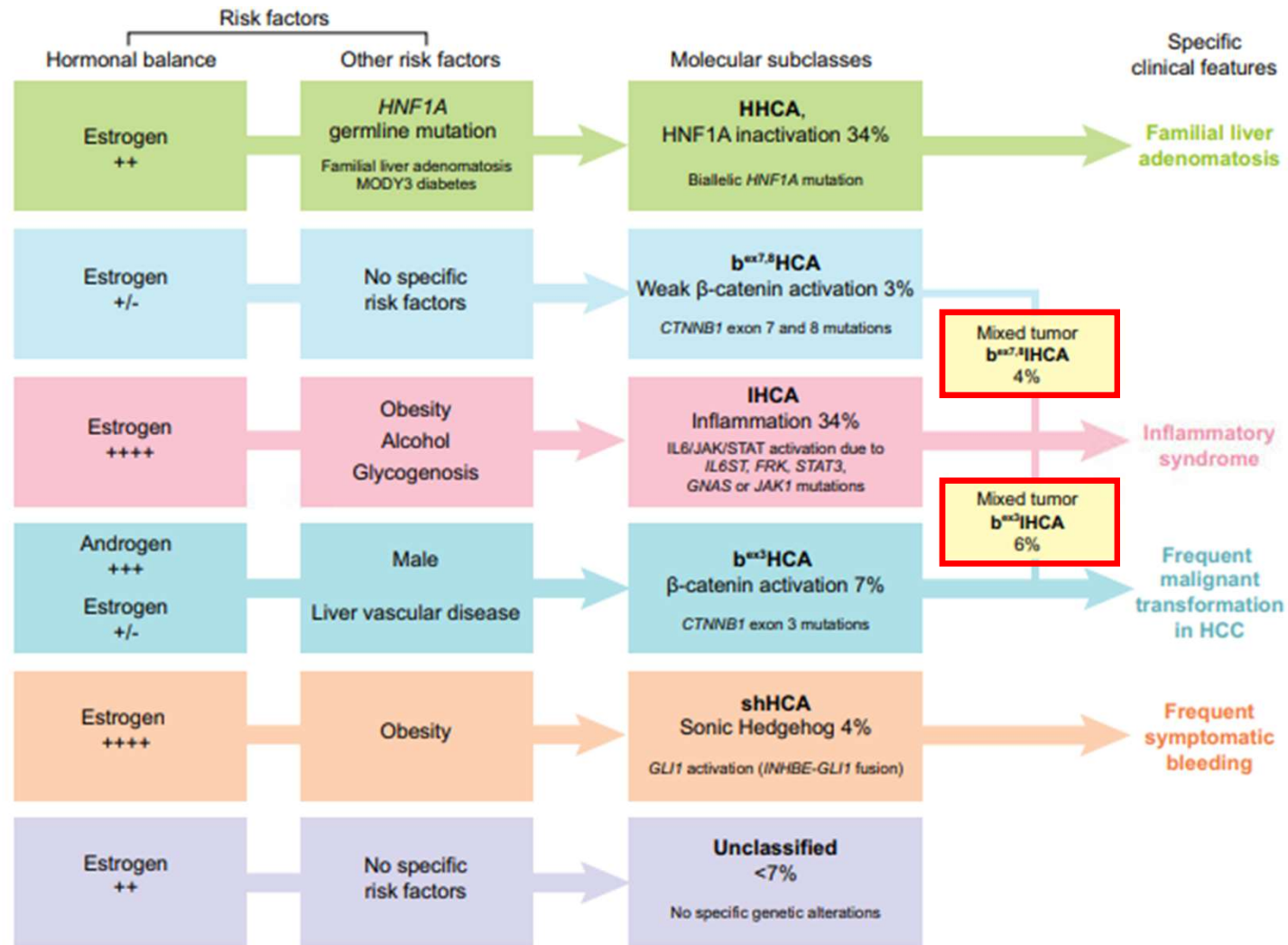
**GS IHC good surrogate marker to identify different CTNNB1 mutations**



**Fig. 2. The genotype/phenotype classification of hepatocellular adenomas (HCAs).** The main molecular subtypes of HCA linked with specific risk factors, clinical features and risk of complications were represented. Mixed forms between inflammatory HCA (IHCA) and β-catenin exon 3 mutated HCA, and between IHCA and β-catenin mutated HCA exon 7/8 have been described.

**$\beta$ -catenin-activated IHCA (bIHCA) 10-15% of all HCAs**

- Have features of both IHCA and bHCA
- Same risk of malignant transformation as bHCAs with exon 3 mutations



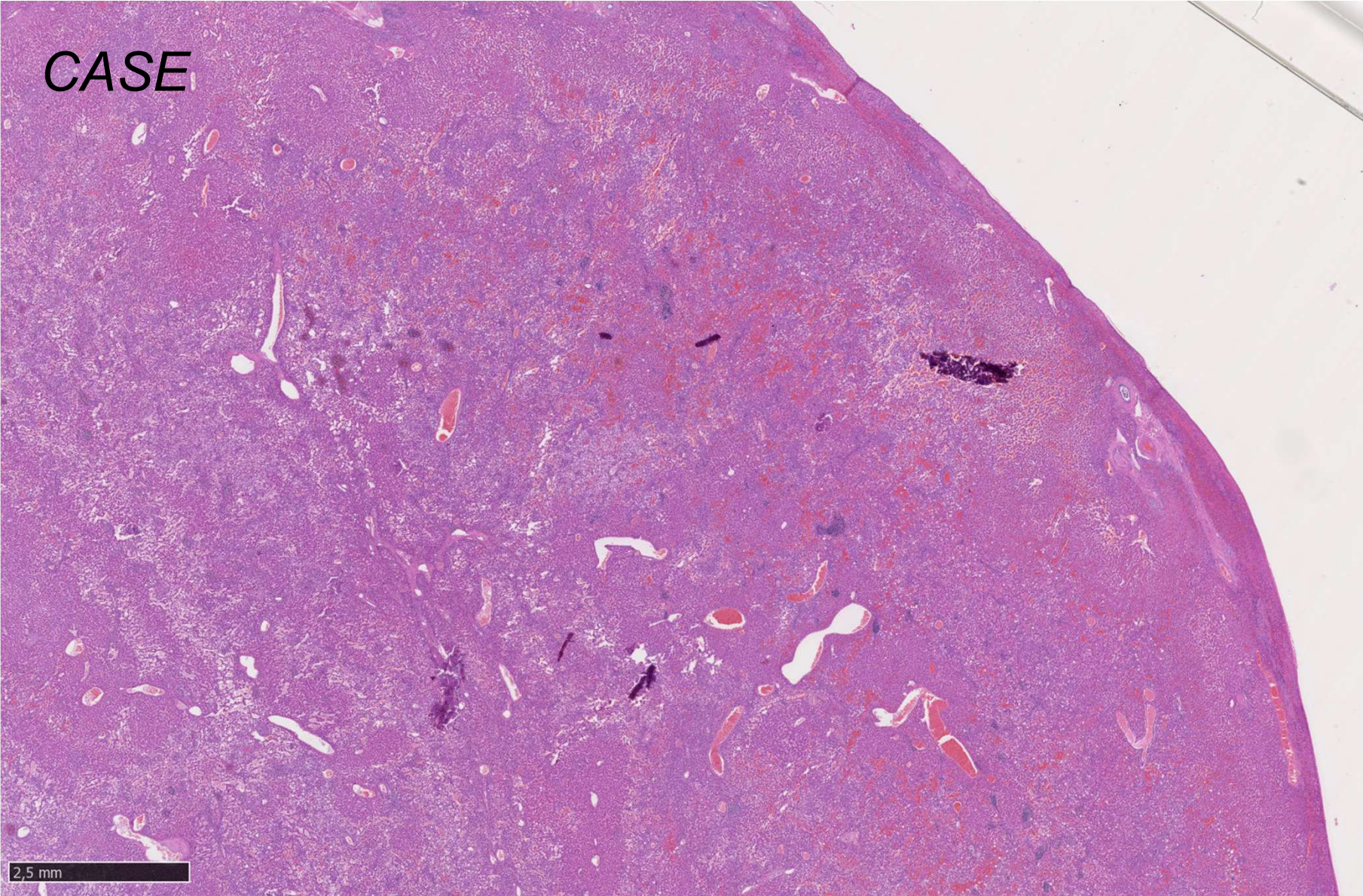
**Fig. 2. The genotype/phenotype classification of hepatocellular adenomas (HCAs).** The main molecular subtypes of HCA linked with specific risk factors, clinical features and risk of complications were represented. Mixed forms between inflammatory HCA (IHCA) and  $\beta$ -catenin exon 3 mutated HCA, and between IHCA and  $\beta$ -catenin mutated HCA exon 7/8 have been described.



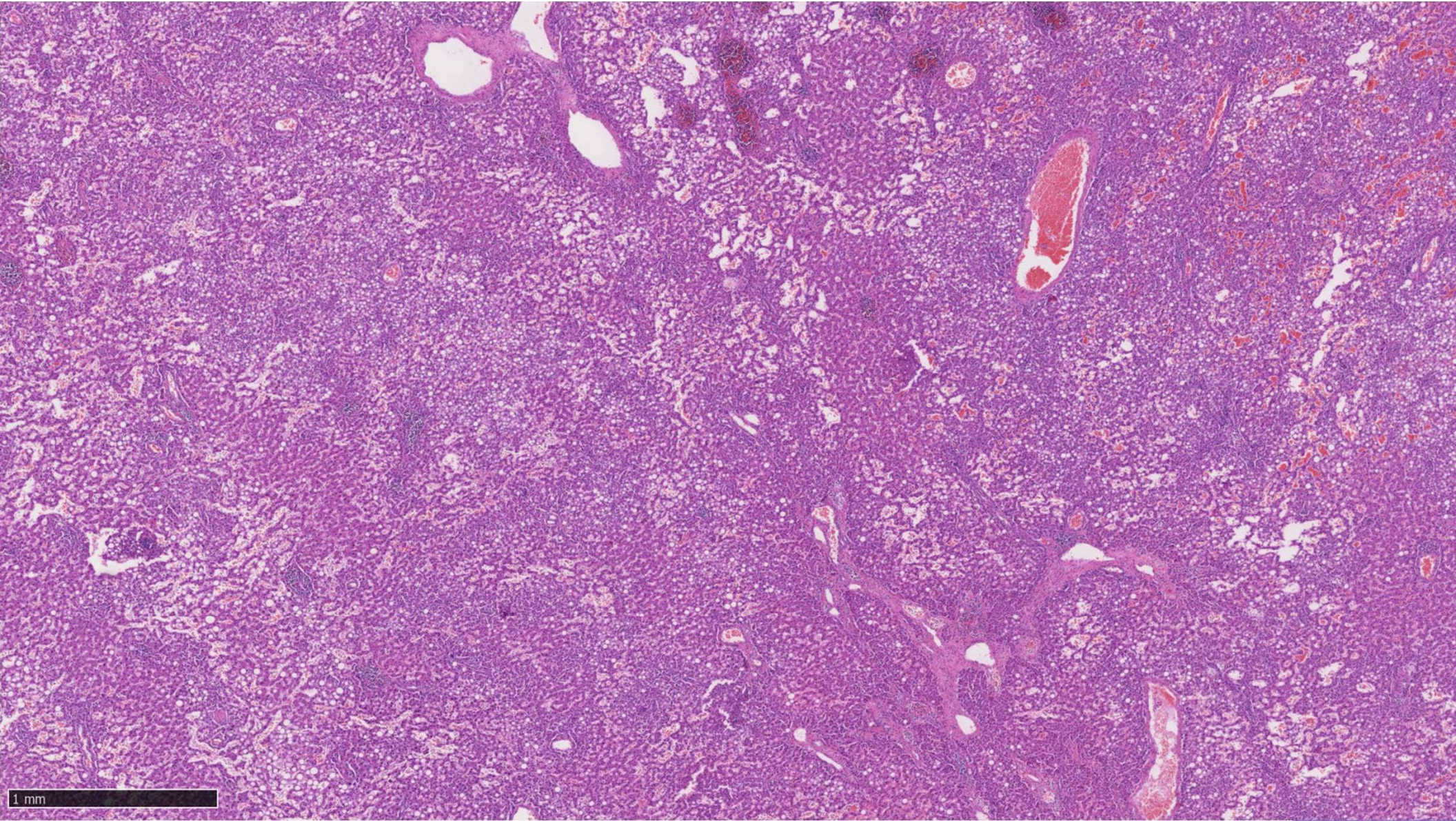
## $\beta$ -catenin-activated HCA (bHCA) borderline lesions

- “**Borderline lesion**” used for bHCA with focal cytoarchitectural atypia and/or reticulin abnormalities (but insufficient for definitive diagnosis of HCC)
- Other proposed term “**atypical hepatocellular neoplasm**” for all bHCA (except exon 7/8 mutation), irrespective of cytoarchitectural atypia, in view of high associated risk of HCC
- Molecular/cytogenetic changes typical of HCC, such as TERT promoter mutations, more common in bHCA/bIHCA with malignant transformation

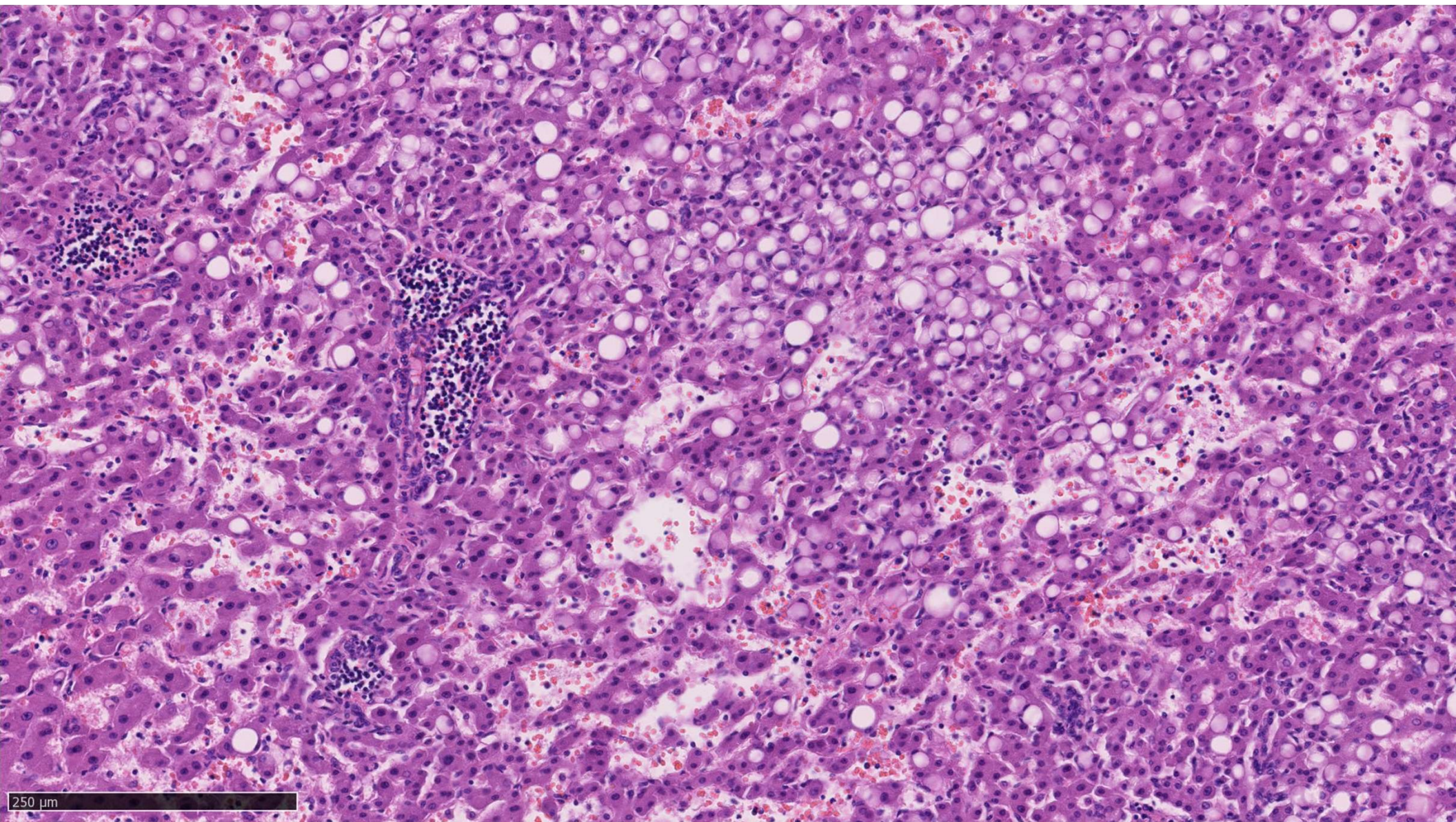
CASE





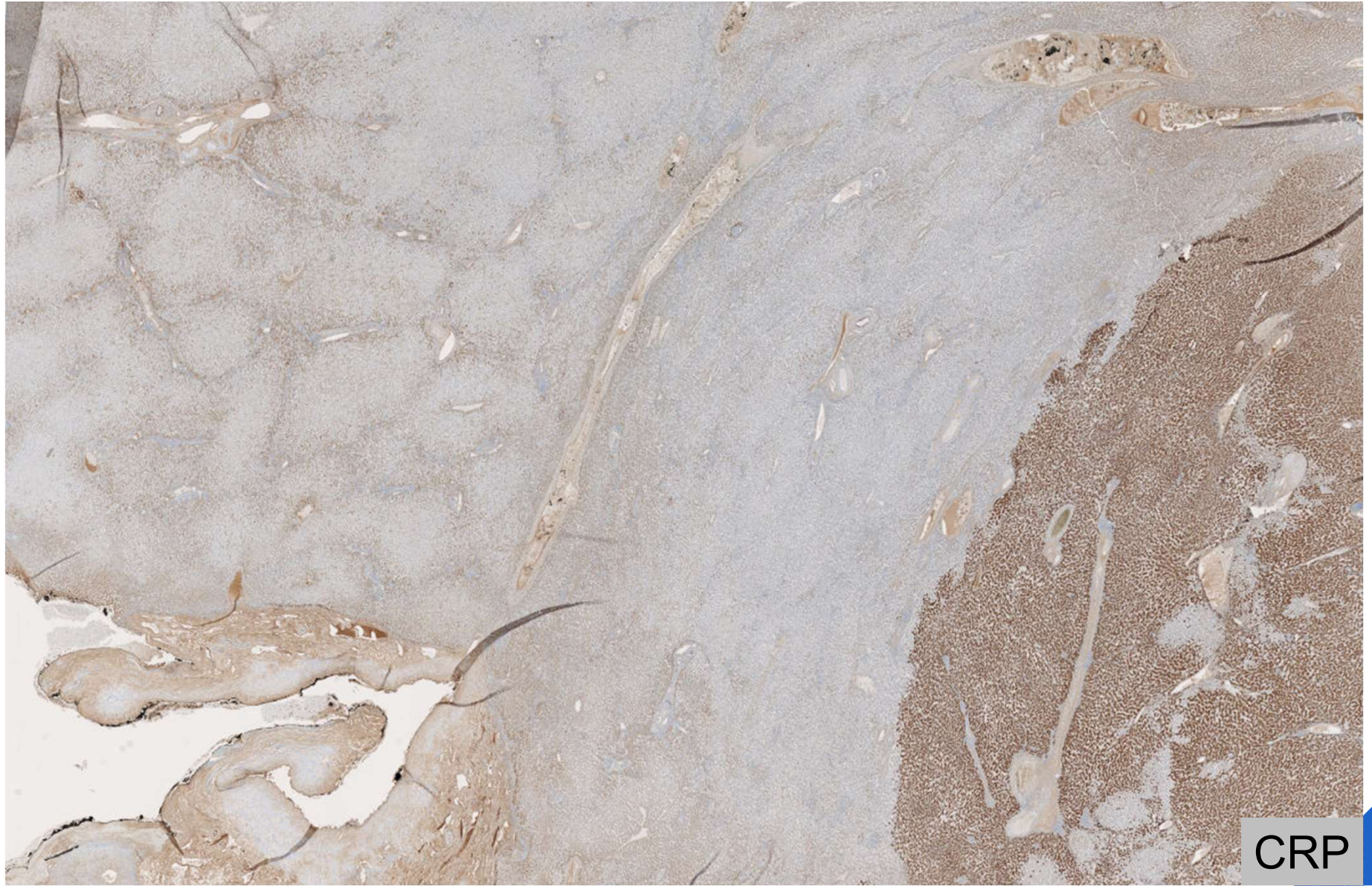






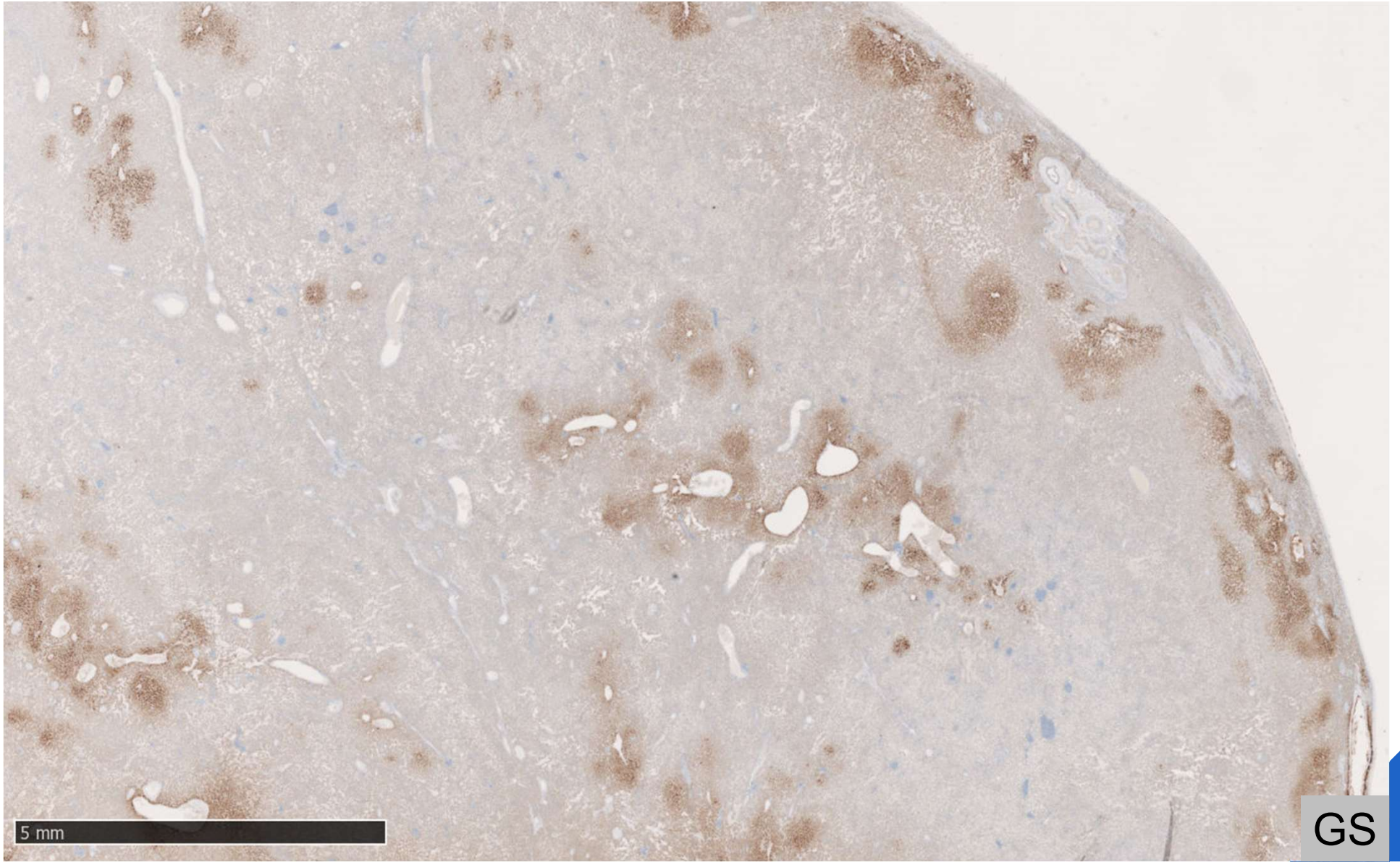
250  $\mu$ m





CRP





5 mm

GS



# *Diagnosis*

- IHCA
- NGS
  - No variants in CTNNB1 (exon 3, 7, 8), TERT promoter, IL6ST, STAT3, FRK, GNAS, JAK1, HNF1A

Hemorrhage induces inflammation and thus slight increase in SAA/CRP expression (without genomic driven activation of IL6/JAK/STAT pathway)

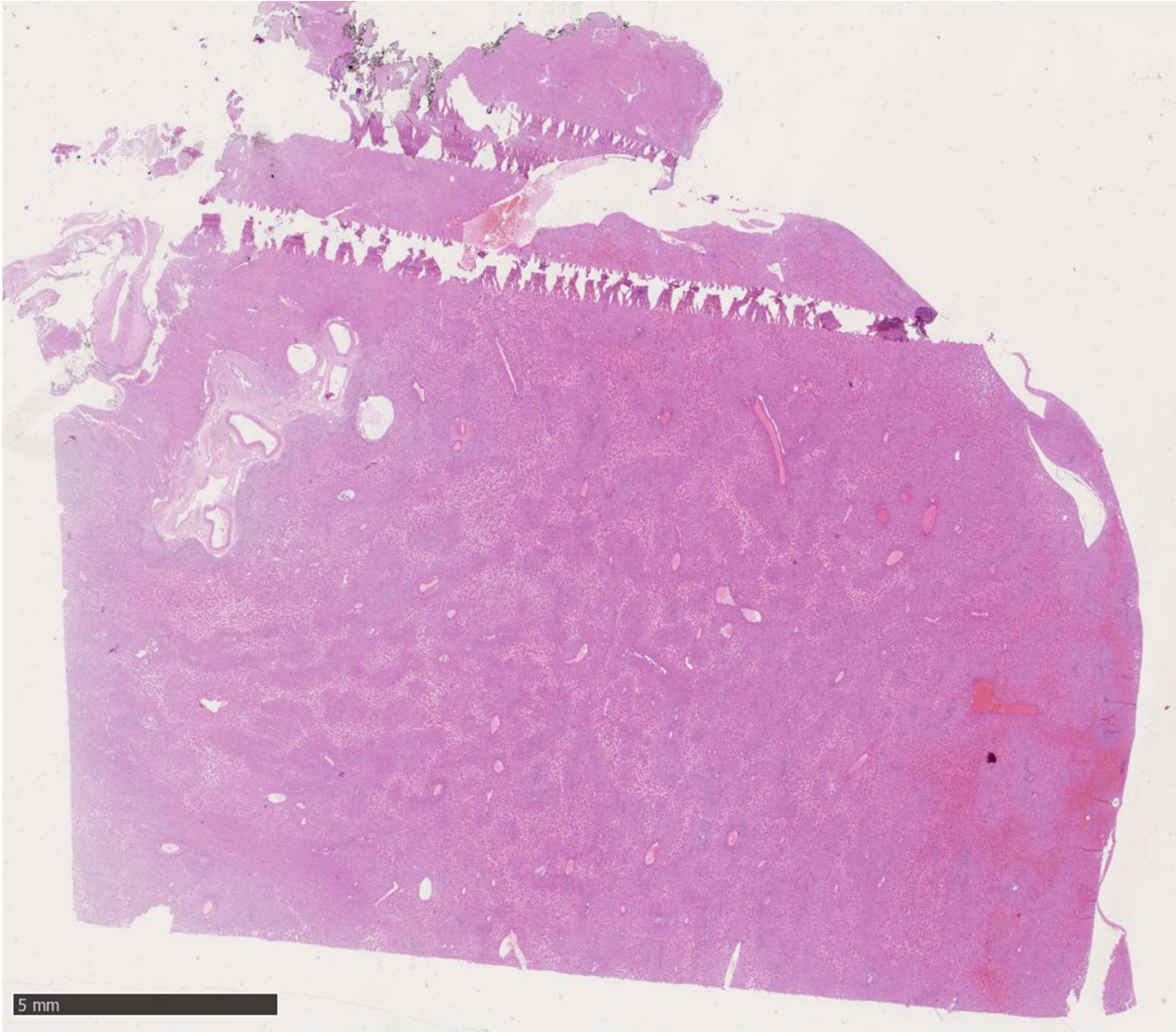
ORIGINAL RESEARCH

## Recurrent chromosomal rearrangements of *ROS1*, *FRK* and *IL6* activating JAK/STAT pathway in inflammatory hepatocellular adenomas

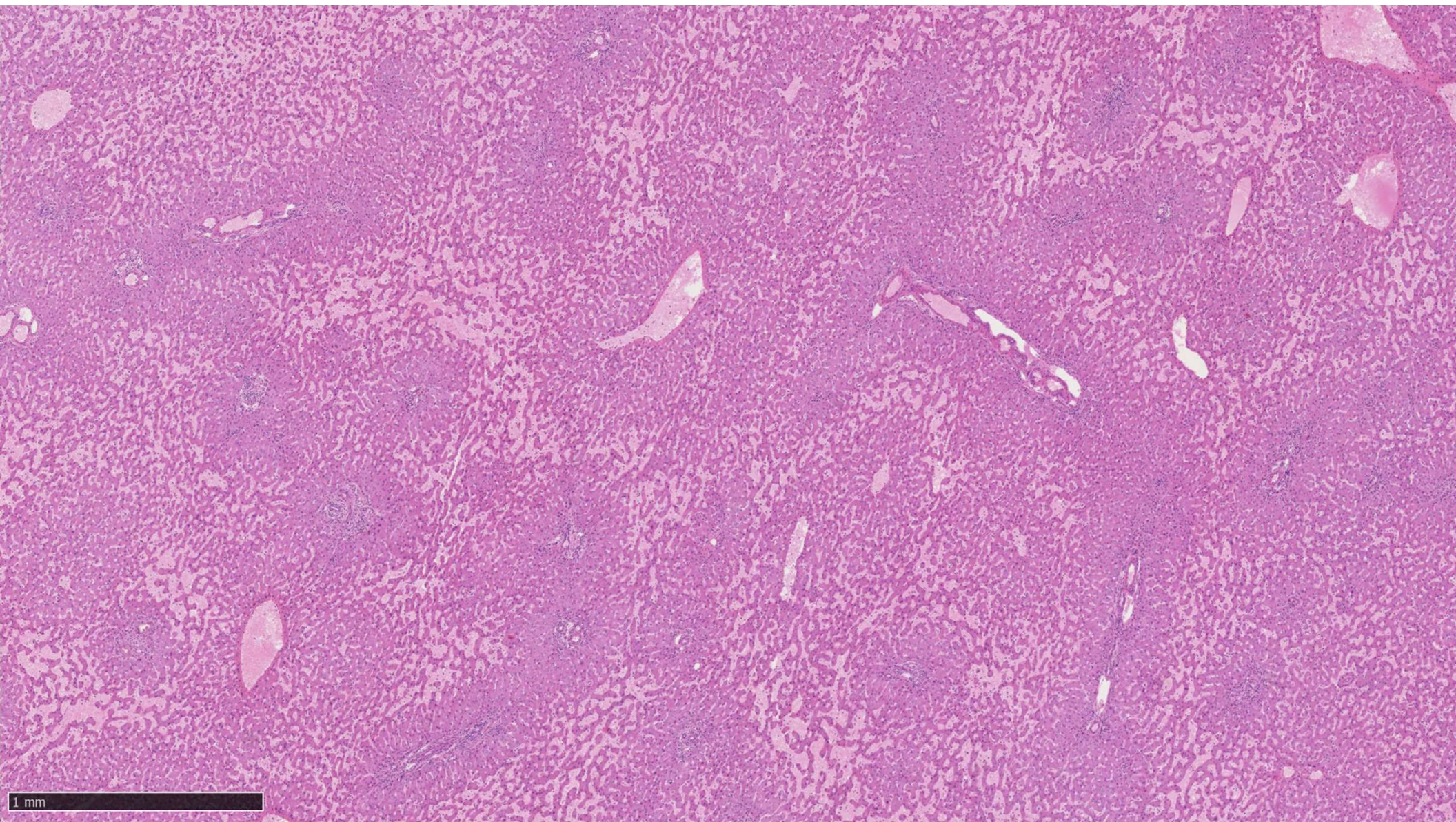
Quentin Bayard,<sup>1</sup> Stefano Caruso,<sup>1</sup> Gabrielle Couchy,<sup>1</sup> Sandra Rebouissou,<sup>1</sup> Paulette Bioulac Sage,<sup>2,3</sup> Charles Balabaud,<sup>3</sup> Valerie Paradis,<sup>4,5</sup> Nathalie Sturm,<sup>6</sup> Anne de Muret,<sup>7</sup> Catherine Guettier,<sup>8</sup> Benjamin Bonsang,<sup>9</sup> Christiane Copie,<sup>9</sup> Eric Letouzé,<sup>1</sup> Julien Calderaro,<sup>9</sup> Sandrine Imbeaud ,<sup>1</sup> Jean-Charles Nault ,<sup>1,10,11</sup> Jessica Zucman-Rossi<sup>1,12</sup>



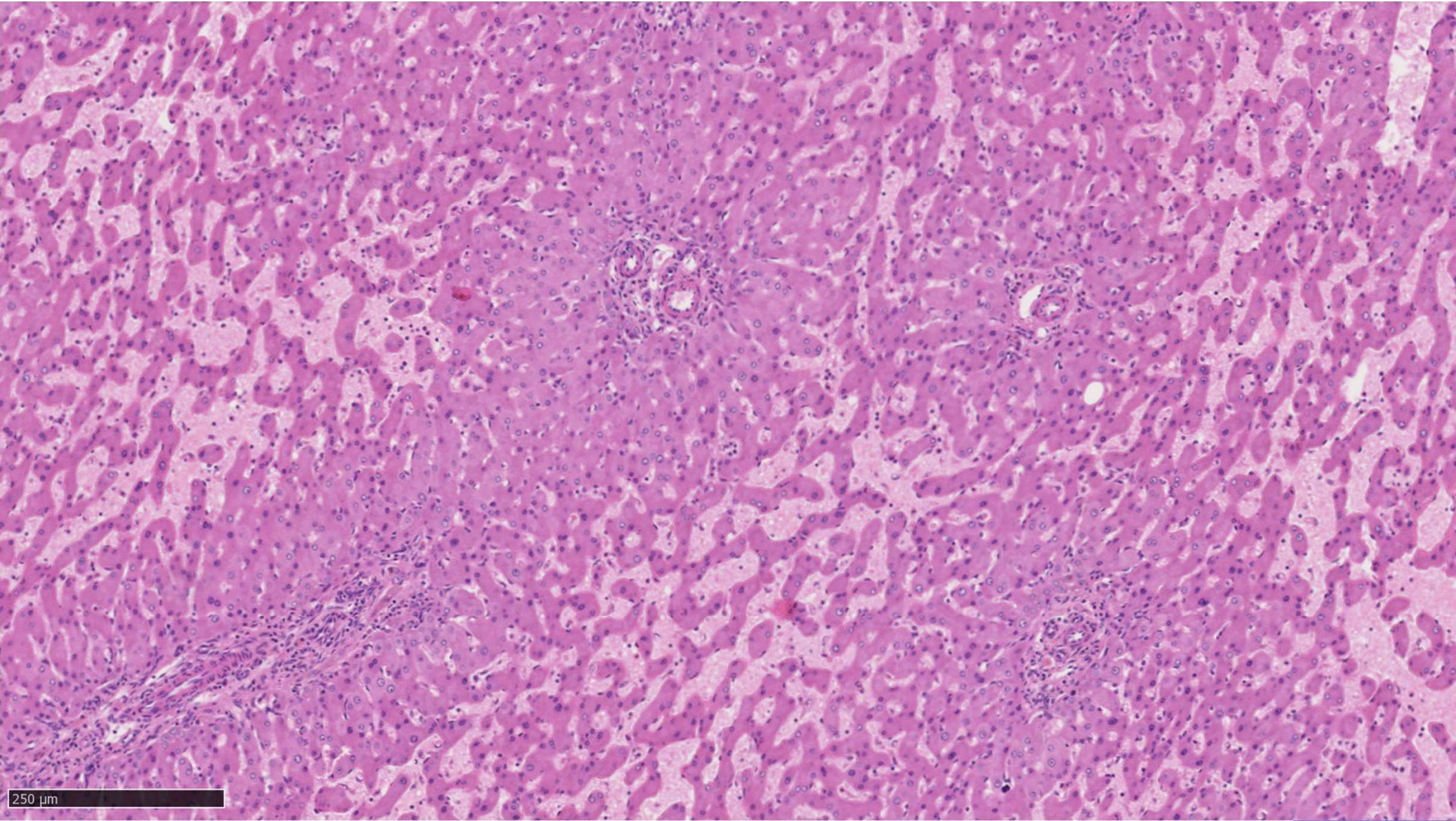
*CASE*





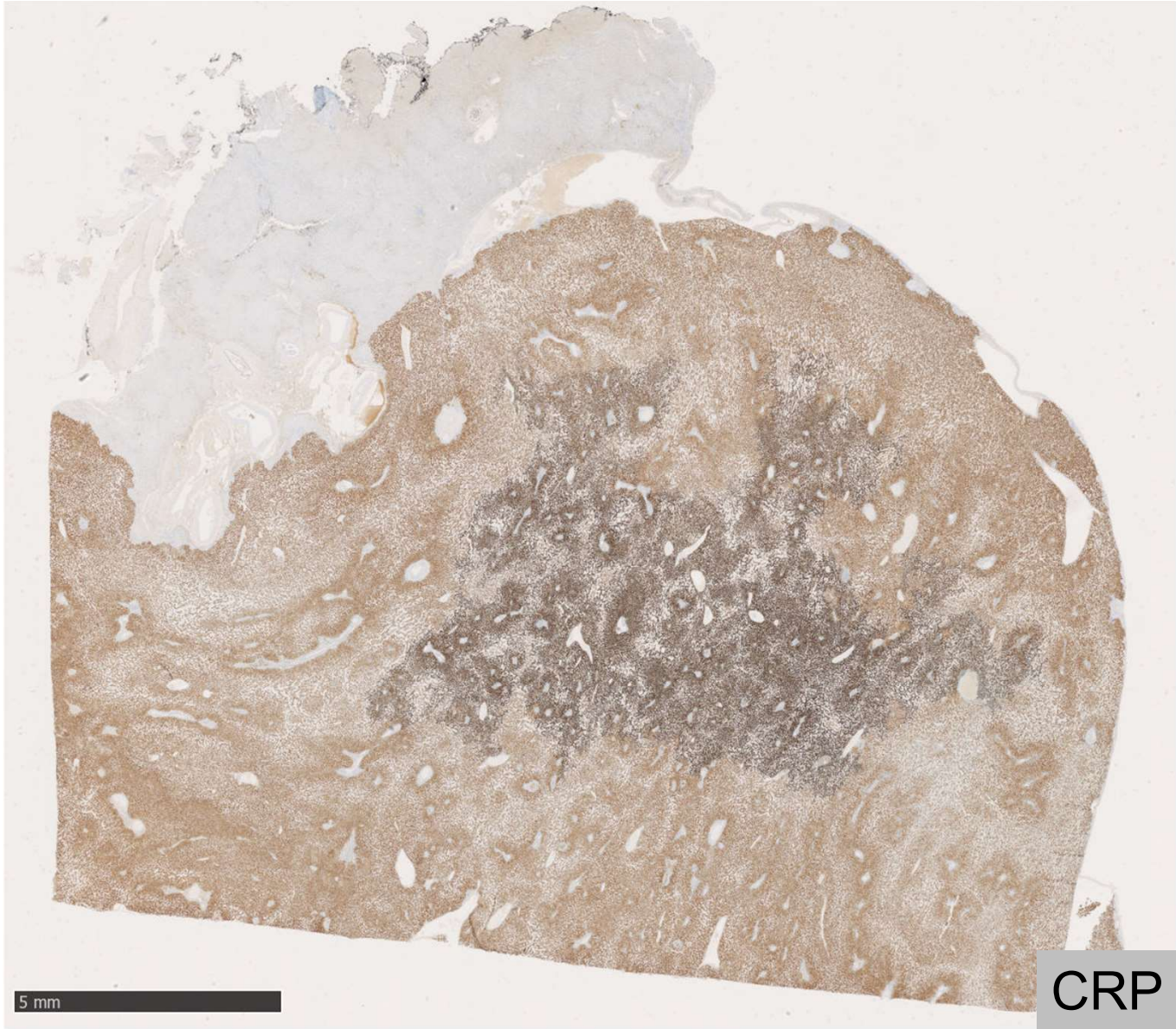






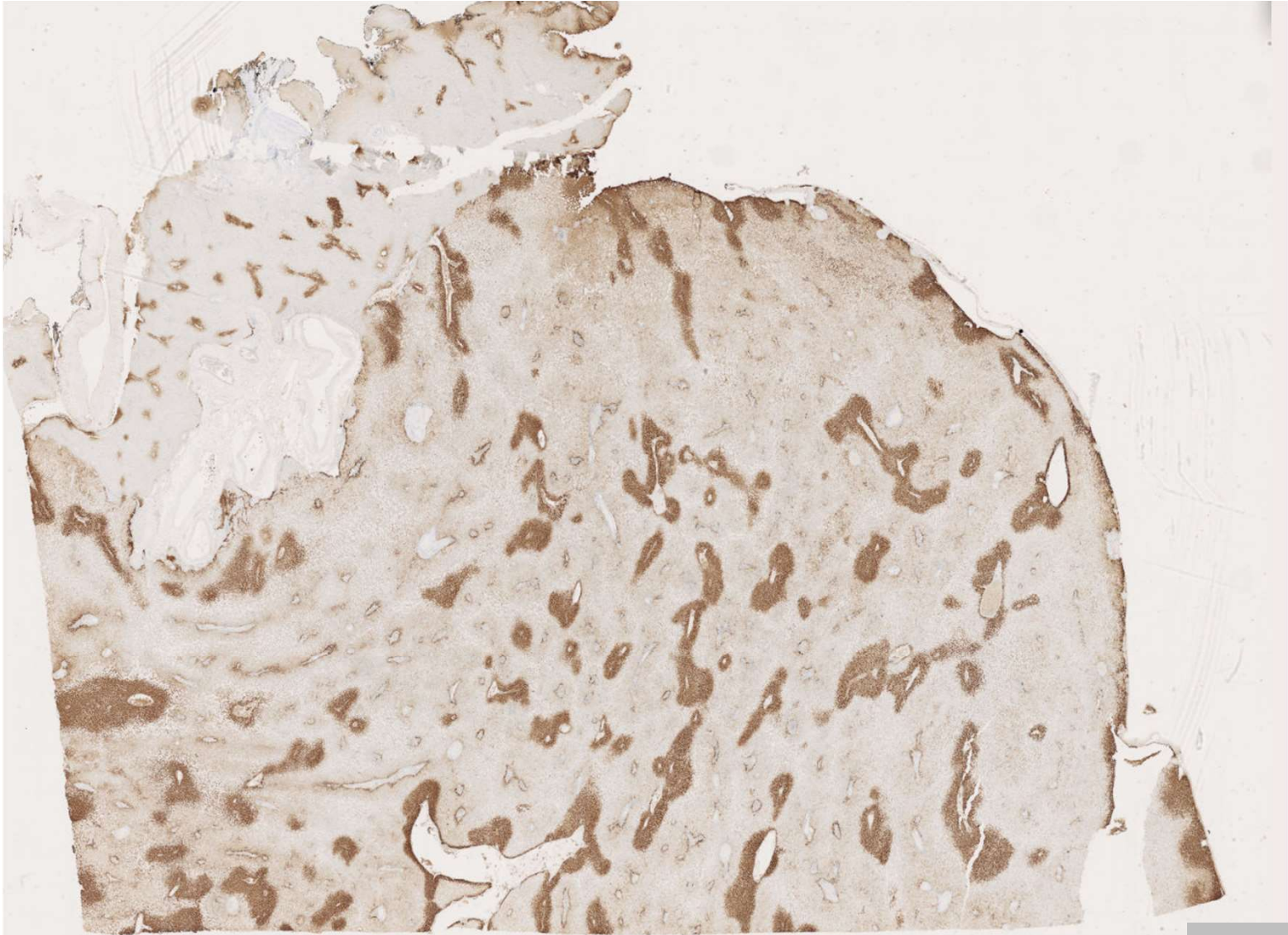
250  $\mu$ m





5 mm

CRP

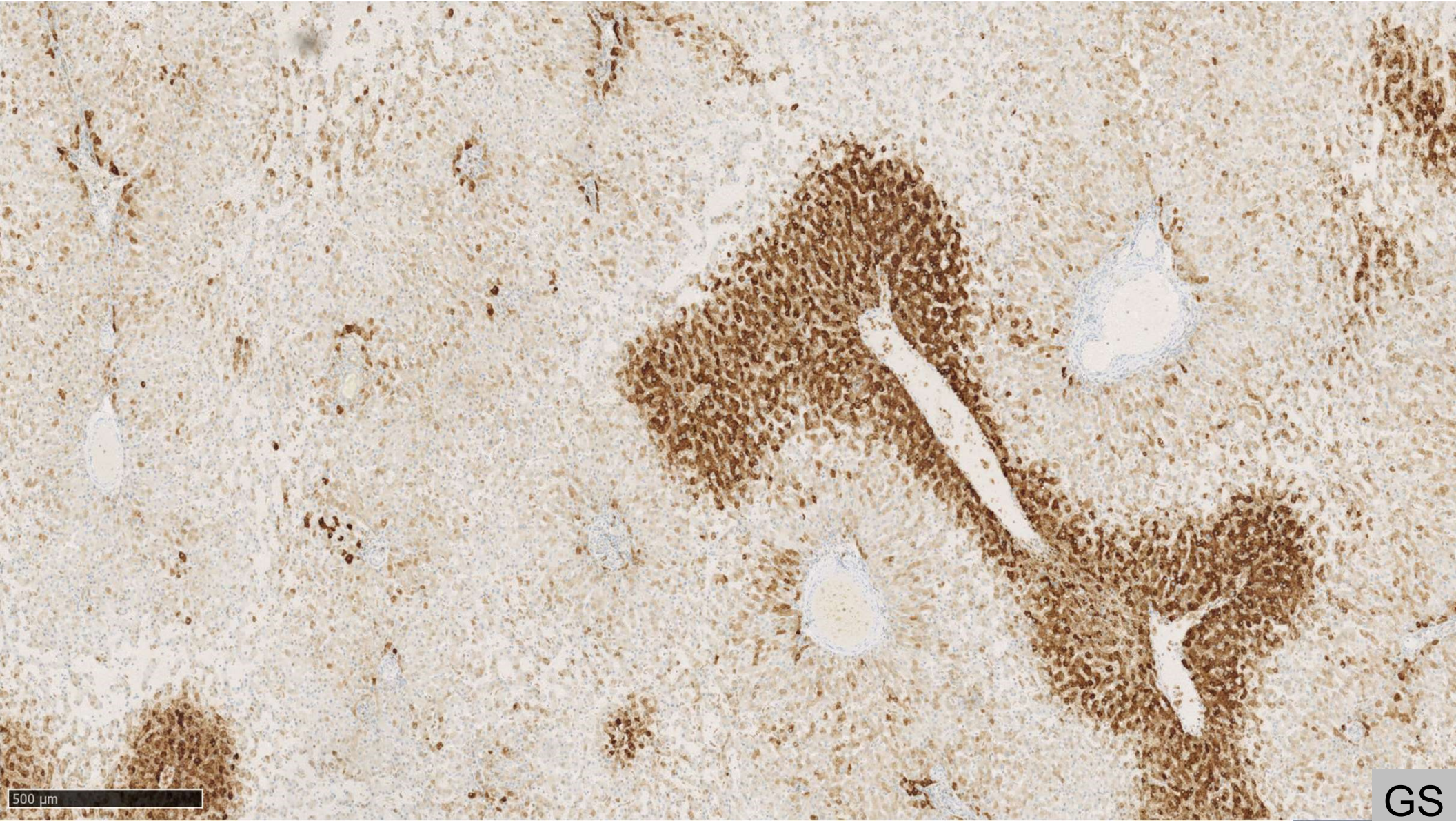


5 mm

GS







500 μm

GS



# *Diagnosis*

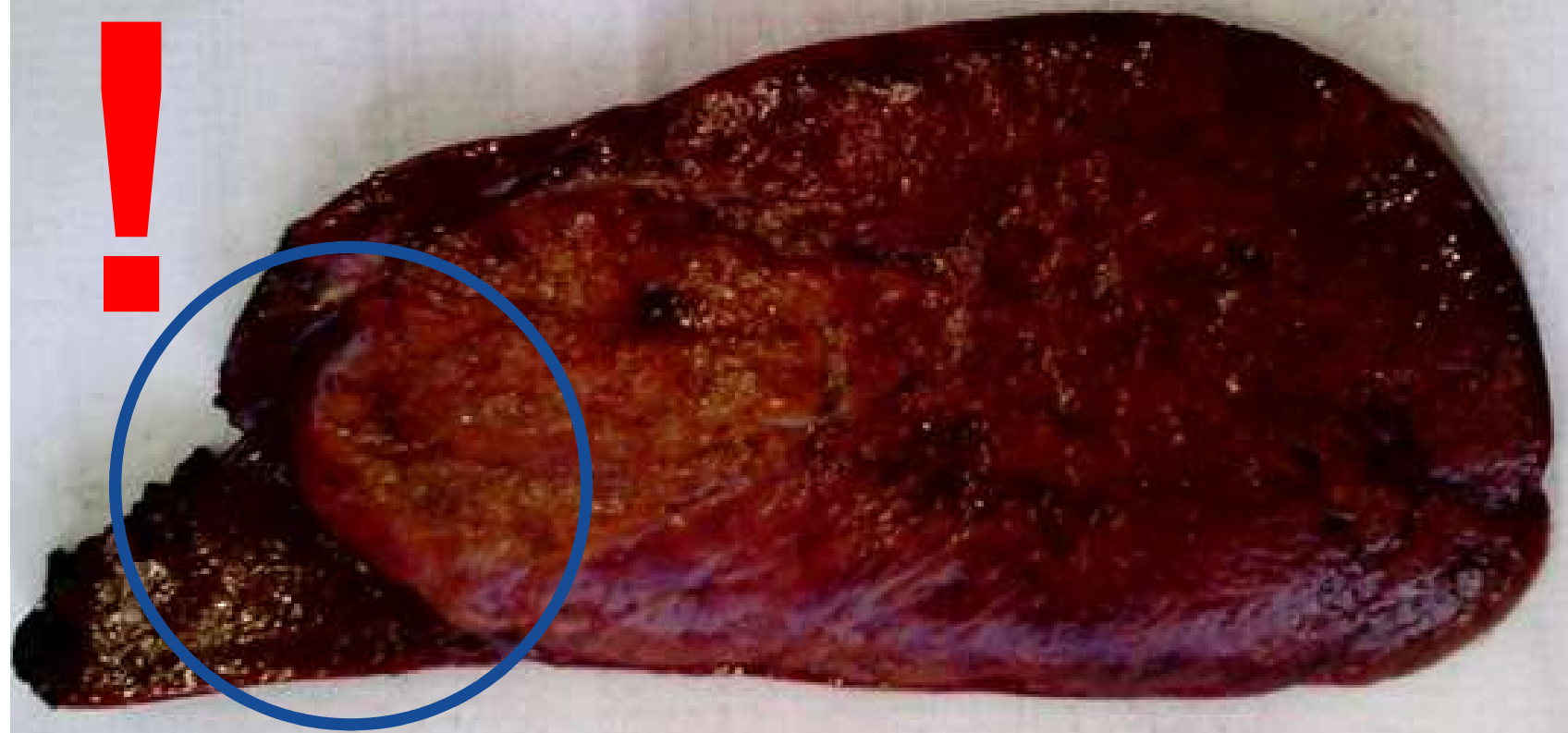
- bIHCA (exon 7/8?)
- NGS
  - CTNNB1 exon 7 putative pathogenic variant
  - IL6ST putative pathogenic variant



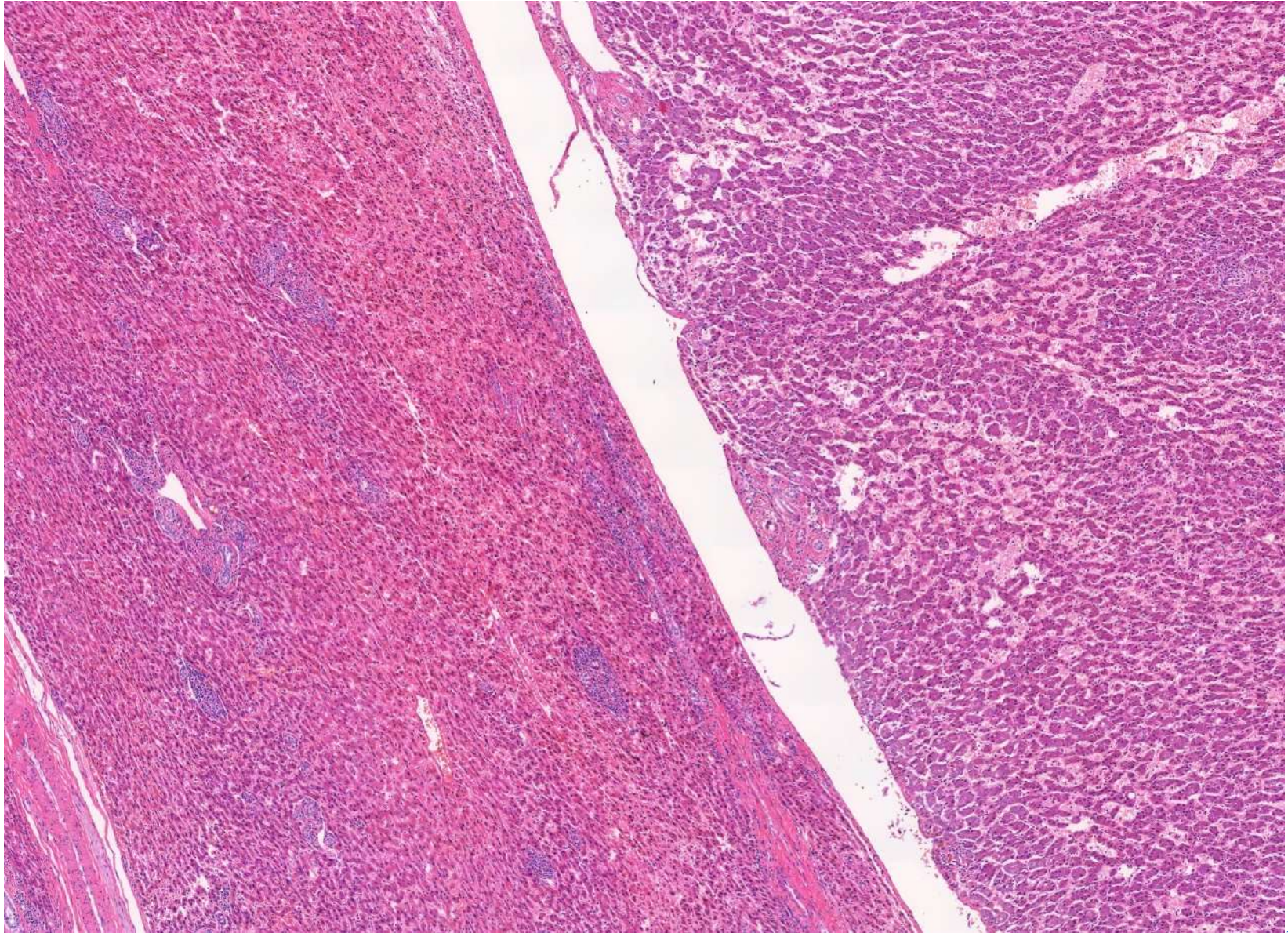
JZ Gent Pathology Department



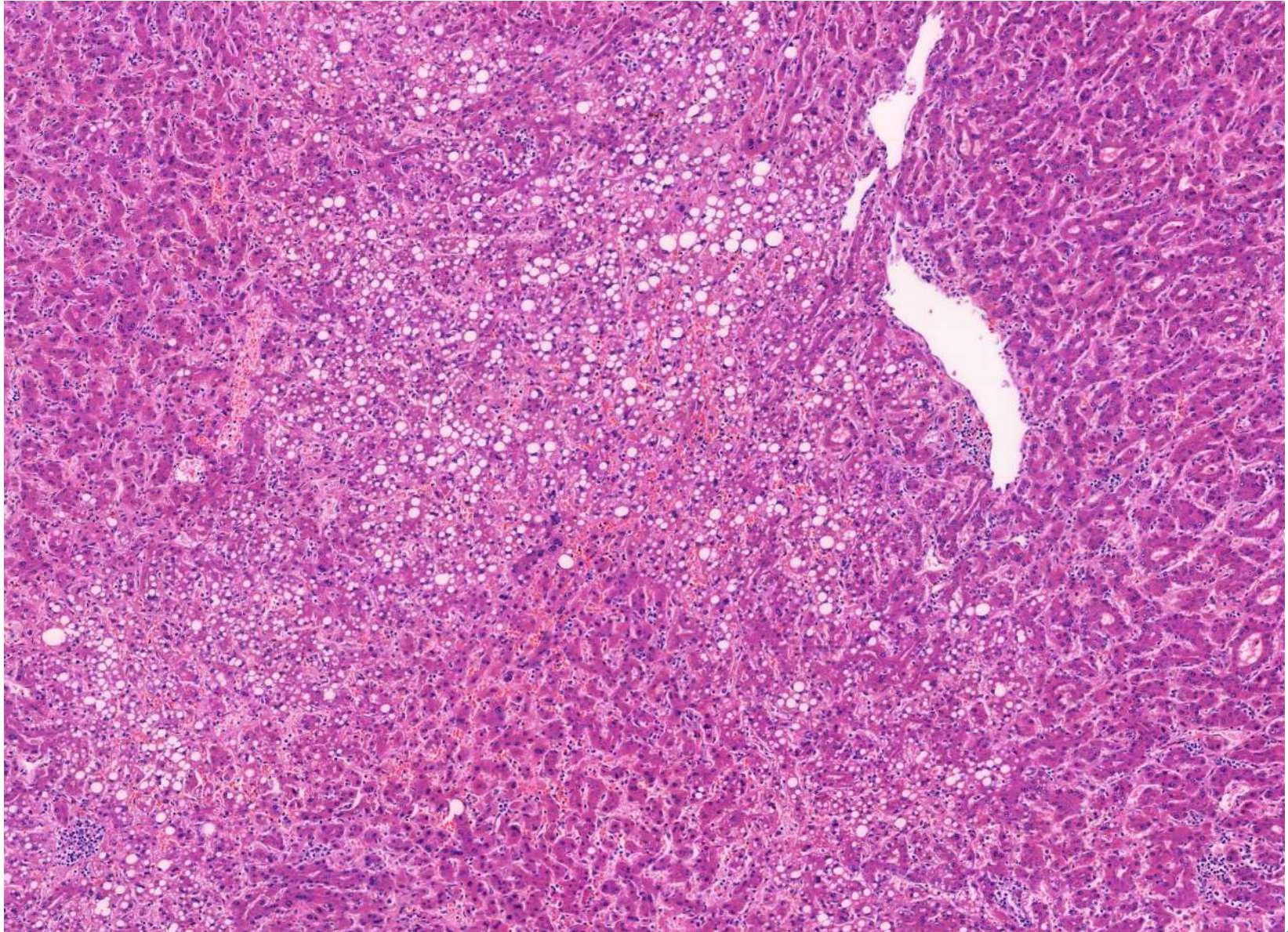
*CASE*









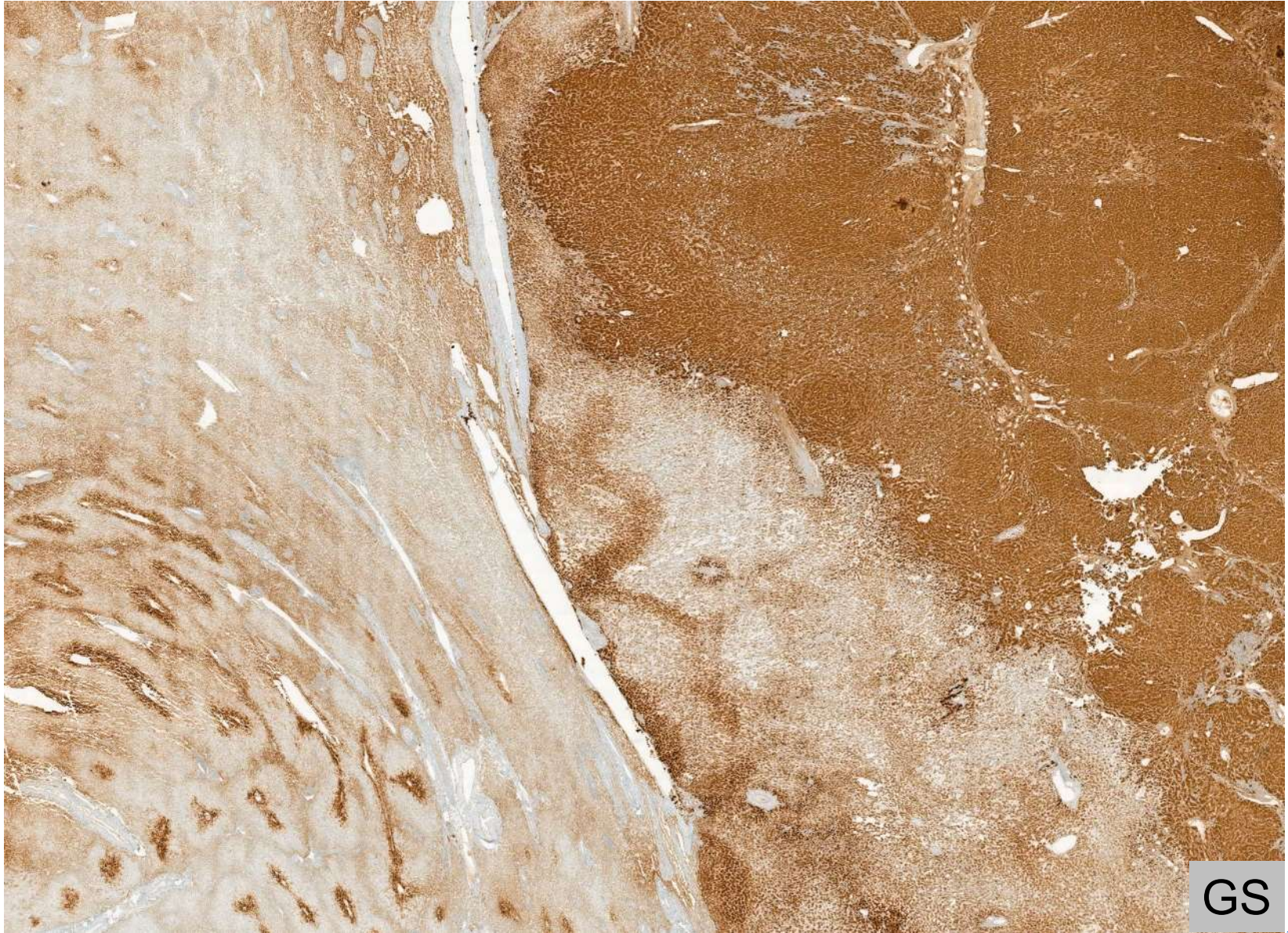






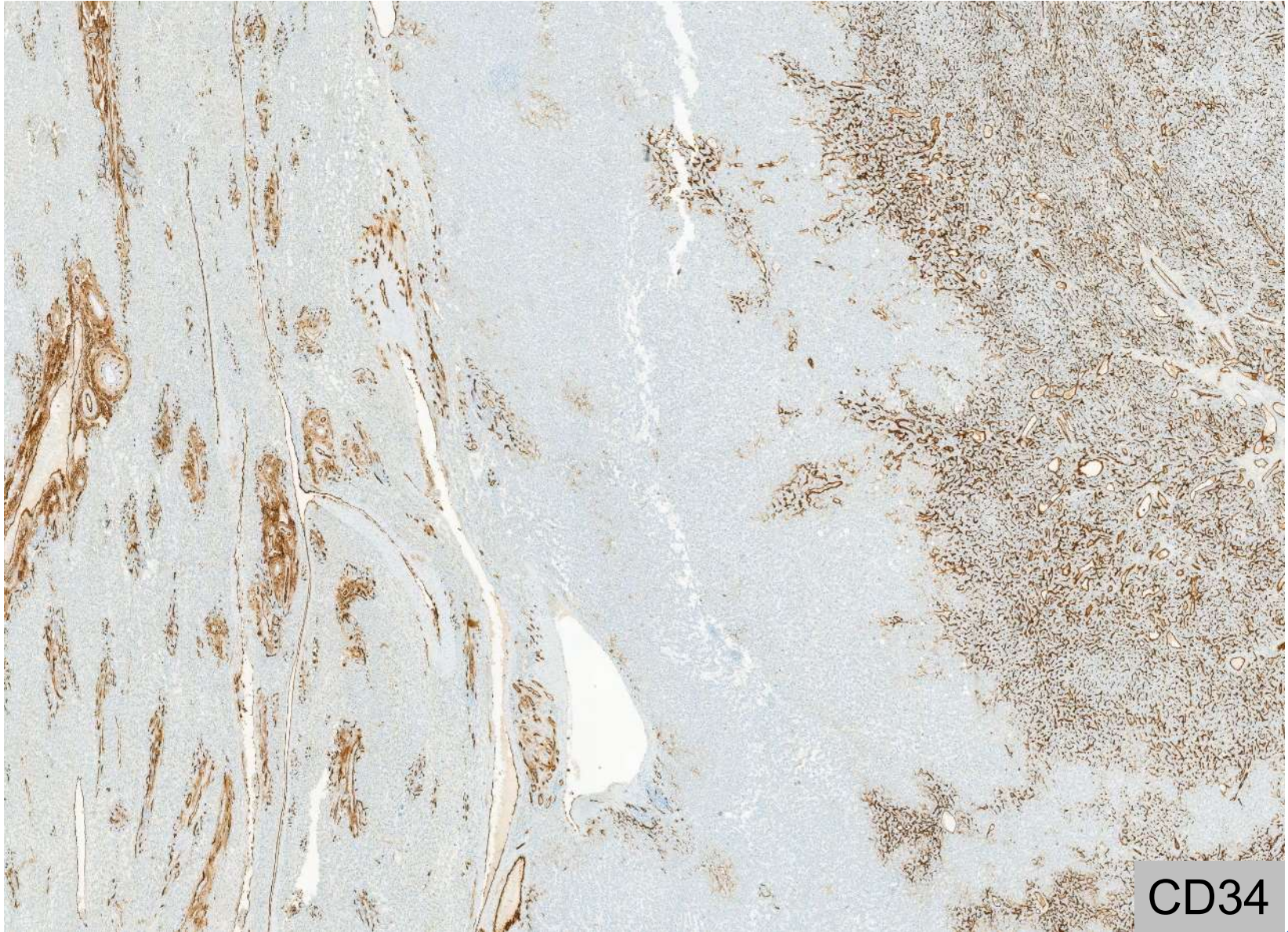
CRP





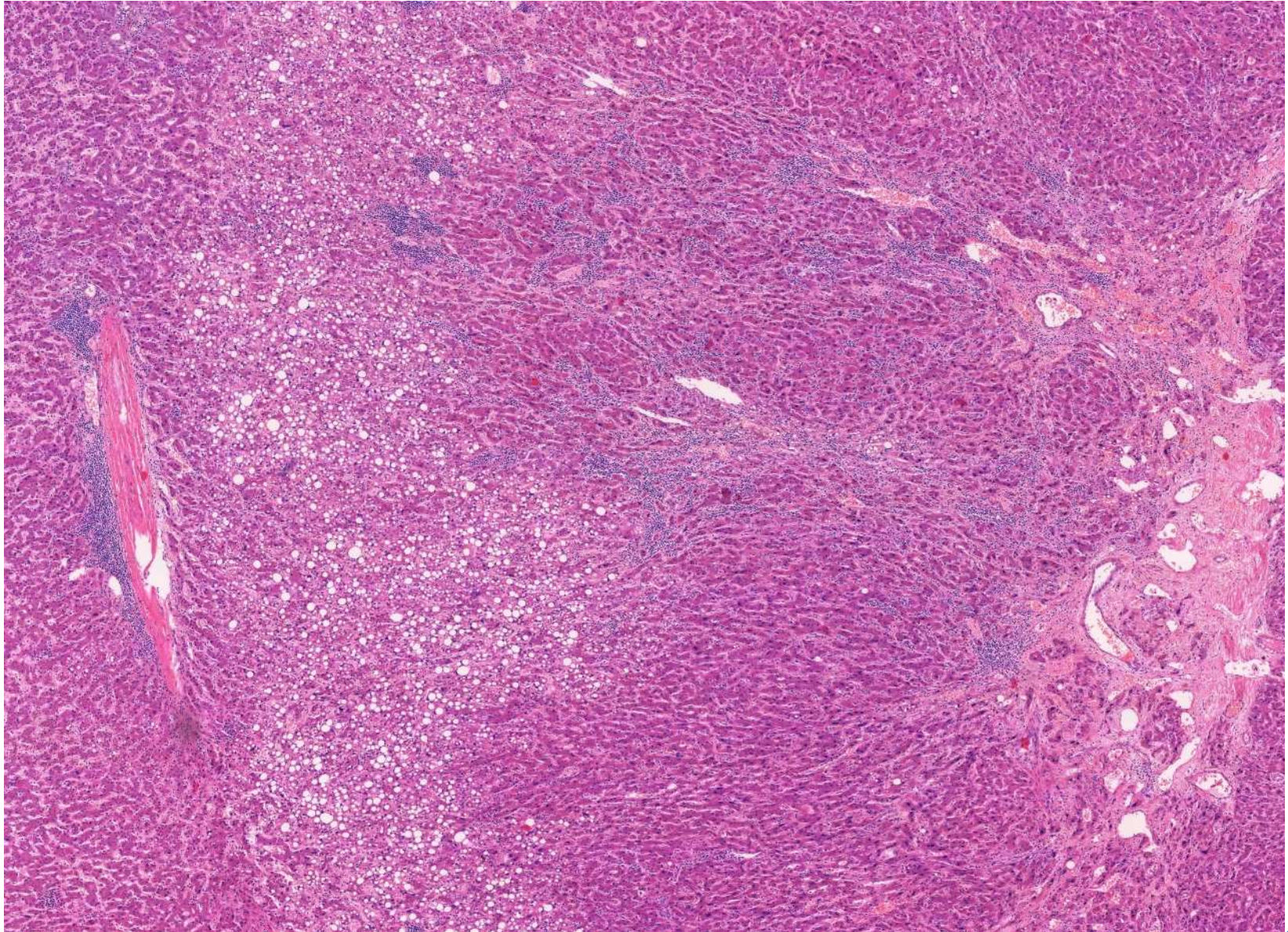
GS



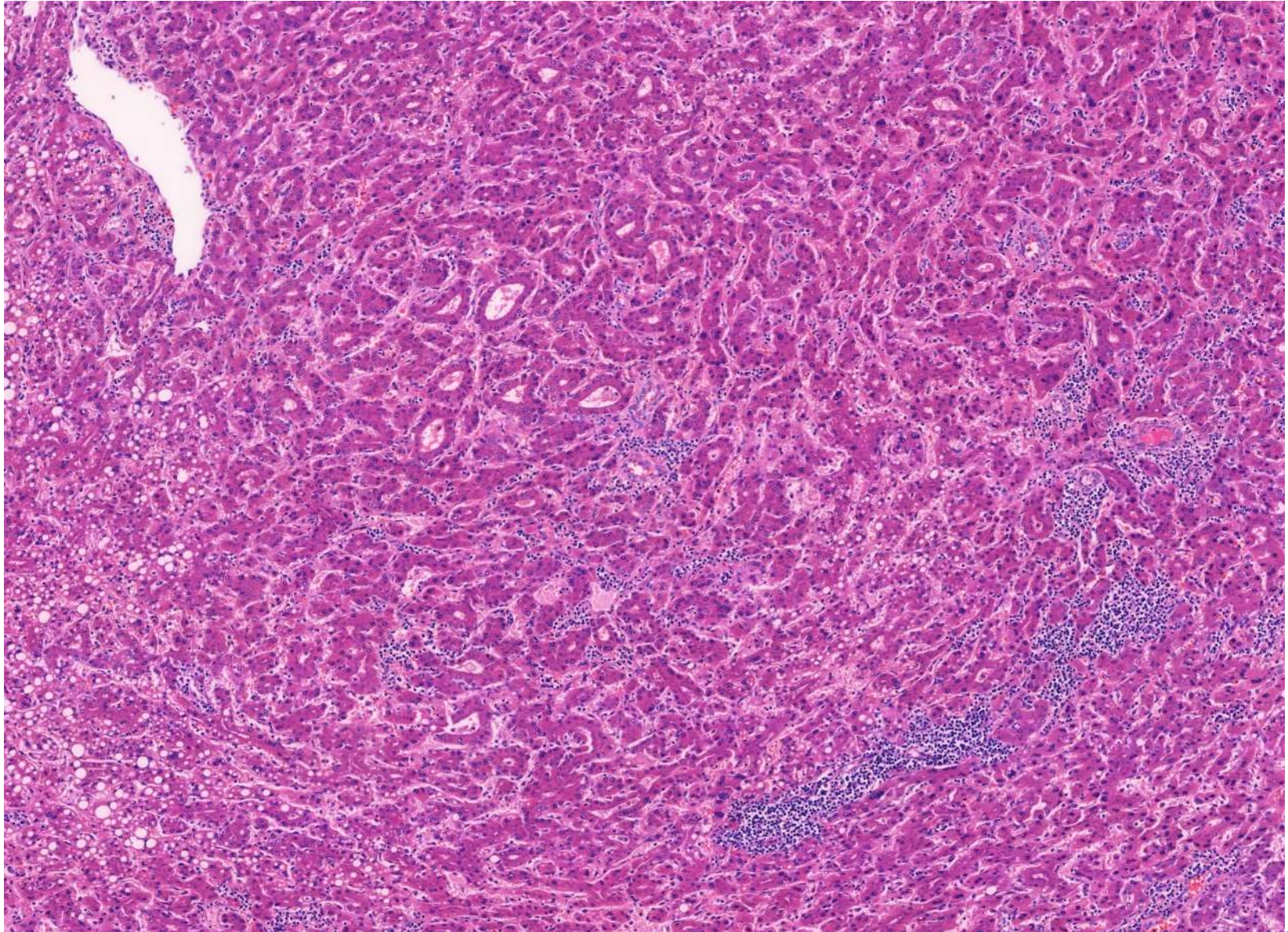


CD34

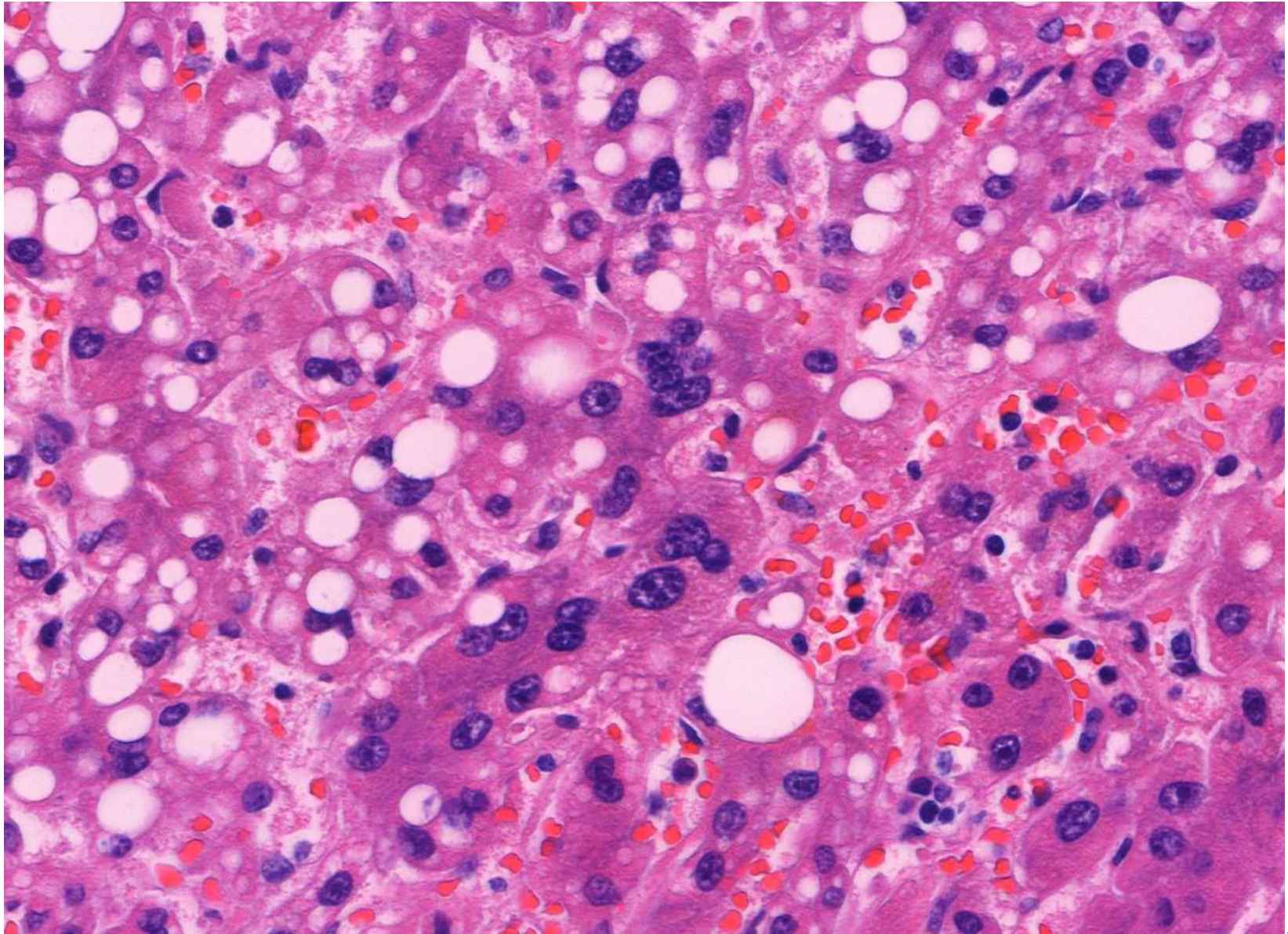




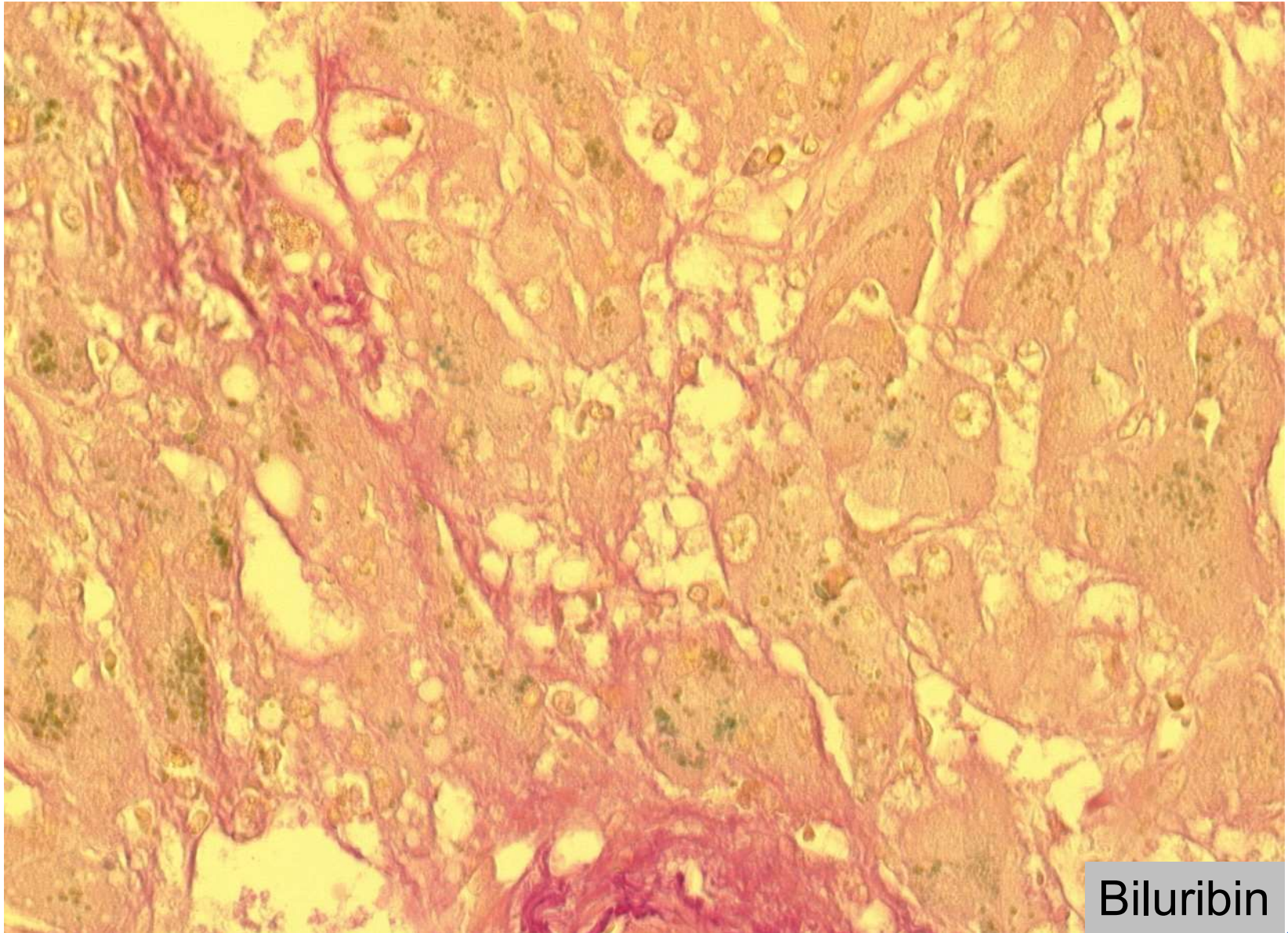






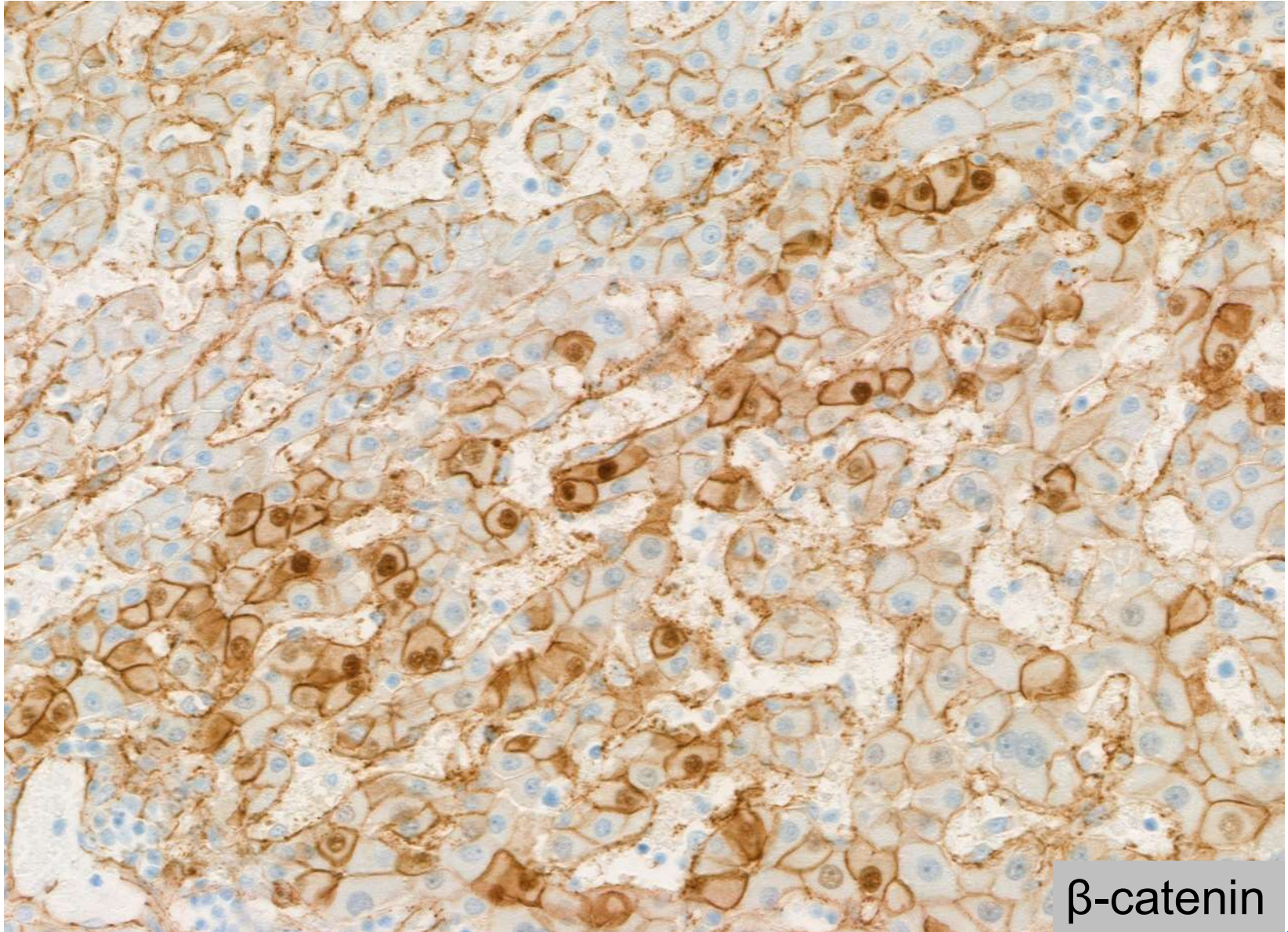






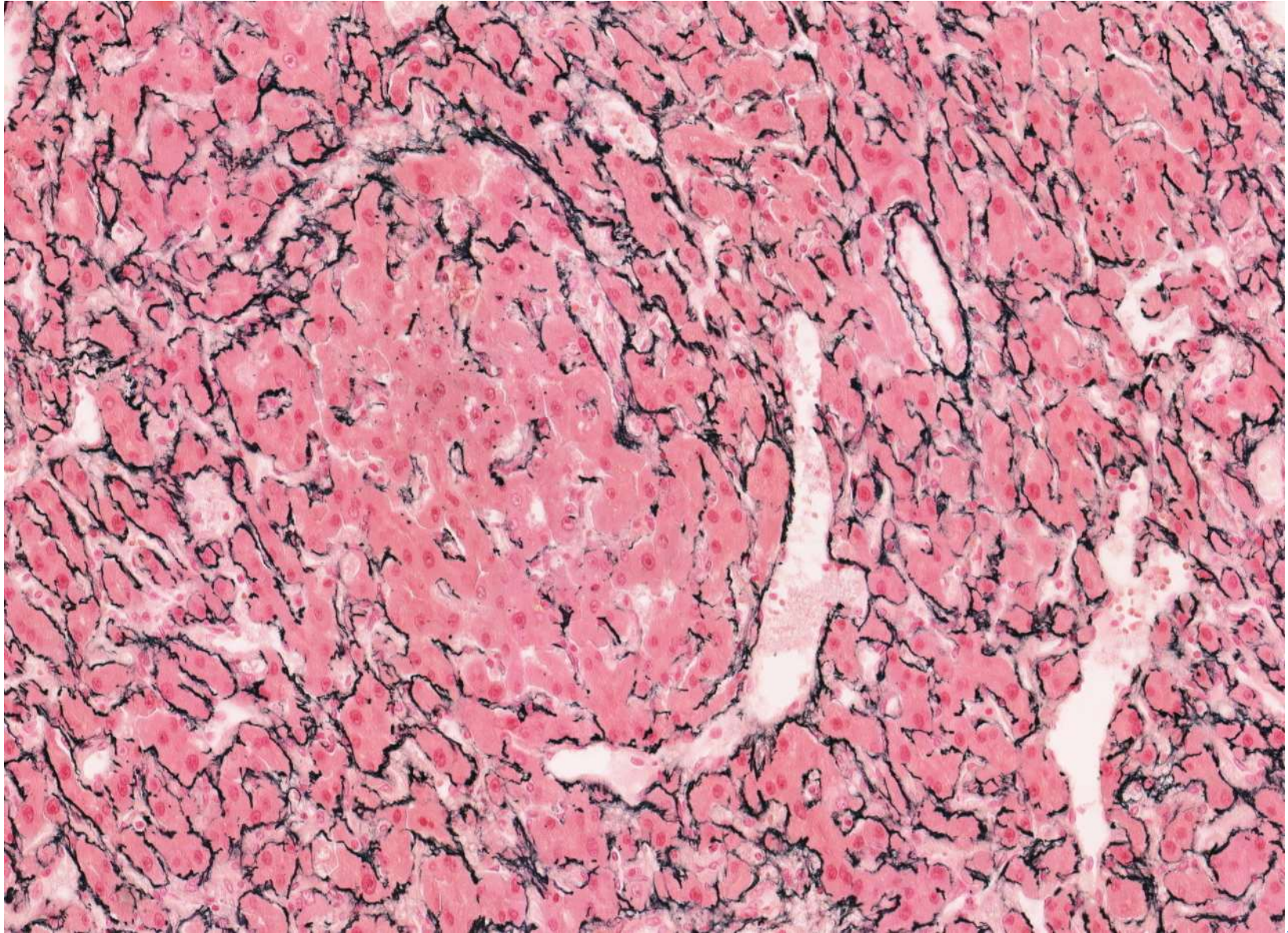
Bilirubin






$\beta$ -catenin







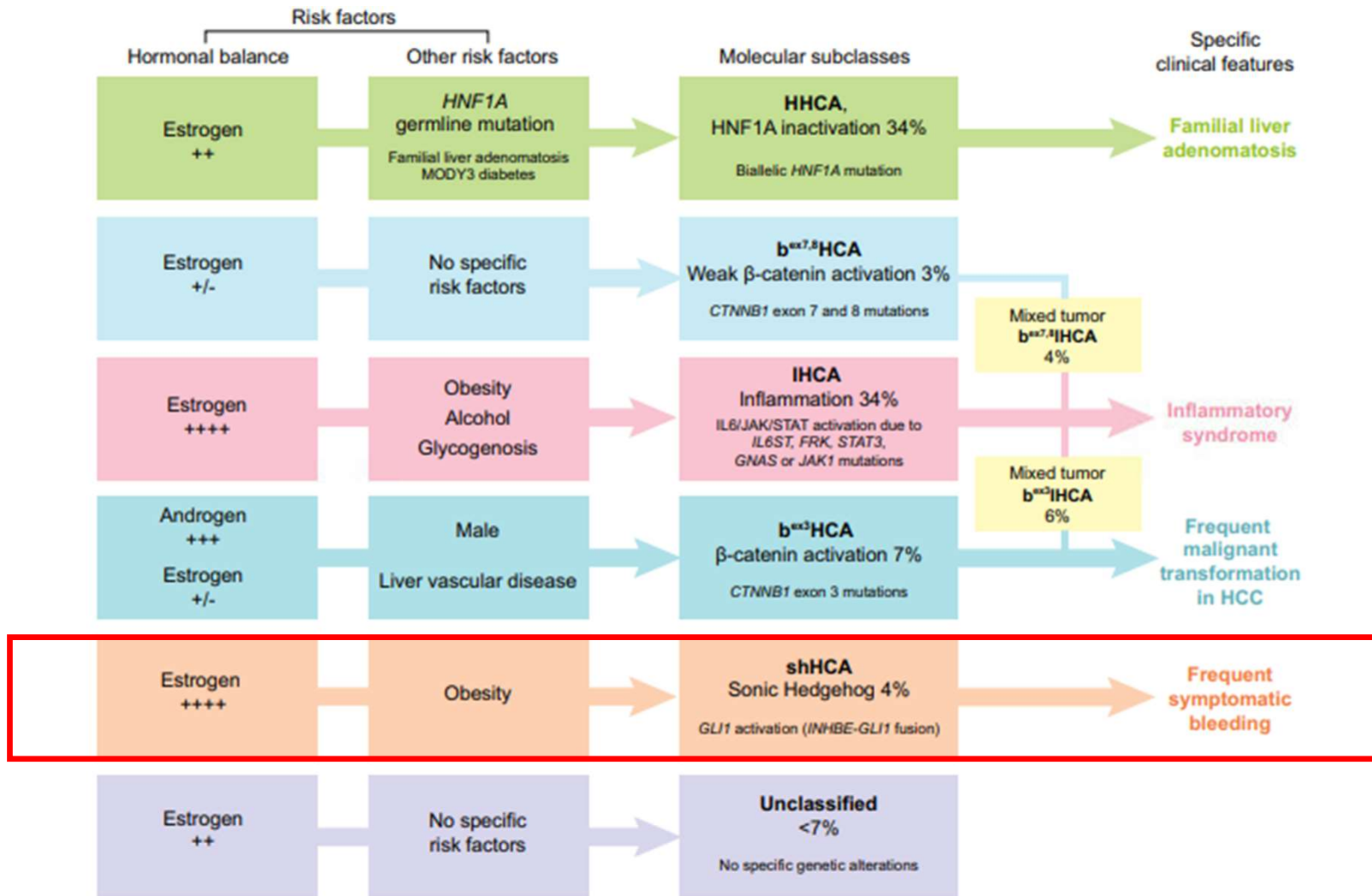
## *Diagnosis*

- bHCA, exon 3 S45?
  - Histopathological features suggestive for bIHCA (sinusoidal dilatation, inflammation)
  
  - Area Ø 5 cm
    - More atypia more acinar transformation, more bilirubinostasis, focally minimal loss of reticulin,...
  - Suggestive for malignant transformation into well-differentiated HCC
  - Completely resected ( $\geq 2$  mm)
  
  - NGS
    - Two variants were identified:
    - CTNNB1 c.133T>C (p.Ser45Pro) pathogenic variant
    - IL6ST exon 6 putative pathogenic variant
- 

## Sonic hedgehog HCA (shHCA) 4% of HCAs

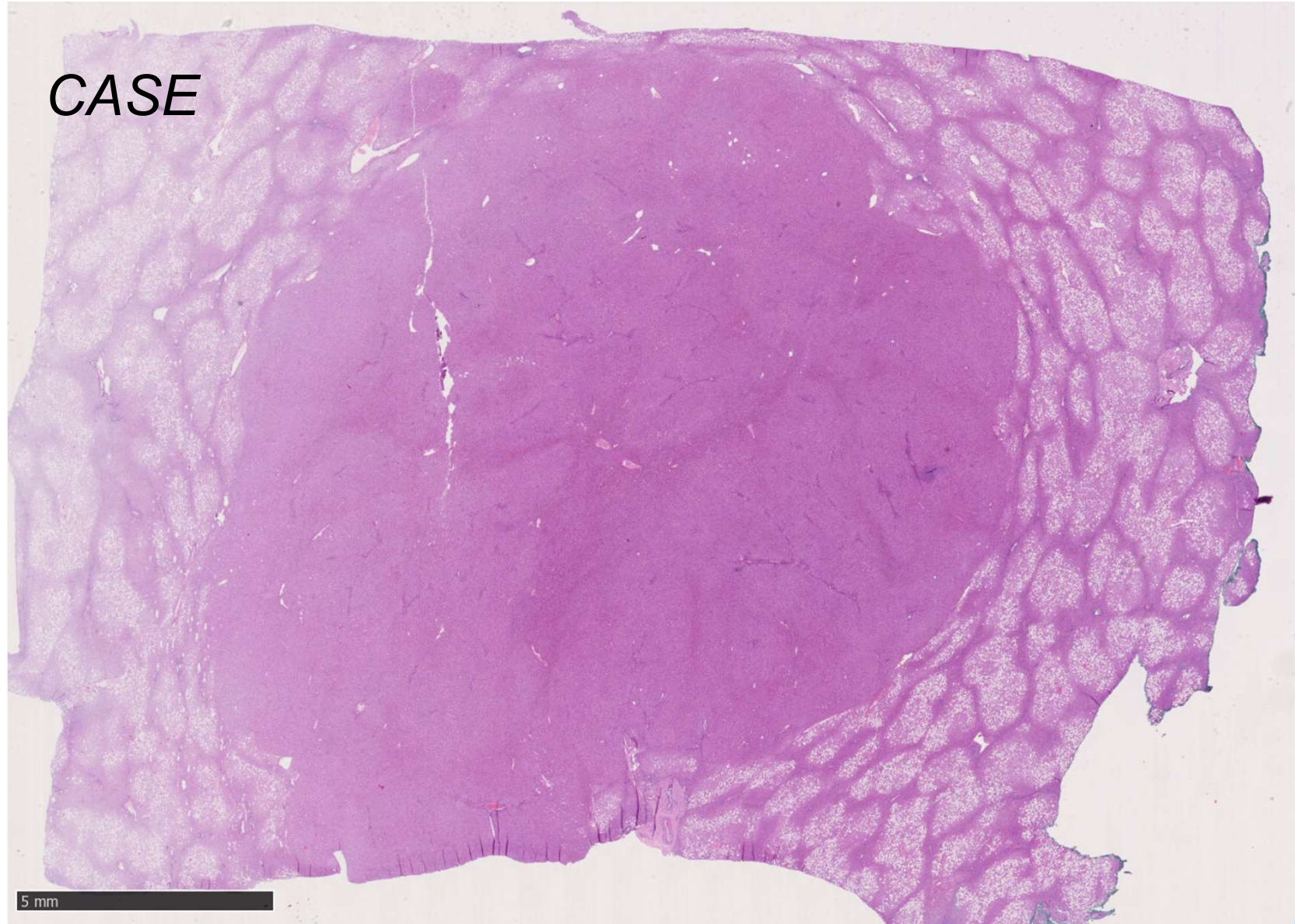
- Activation of sonic hedgehog pathway due to small somatic deletions of INHBE leading to fusion of INHBE and GLI1
- May be identified by immunostaining for PTGDS (probably low sensitivity)
- Overexpression of ASS1 also been reported in HCA (**ASS1-pos HCA**), including probably all shHCAs (probably low specificity)
- Associated with high risk of hemorrhage, even for small nodules
- Further studies needed to further characterize these subtypes



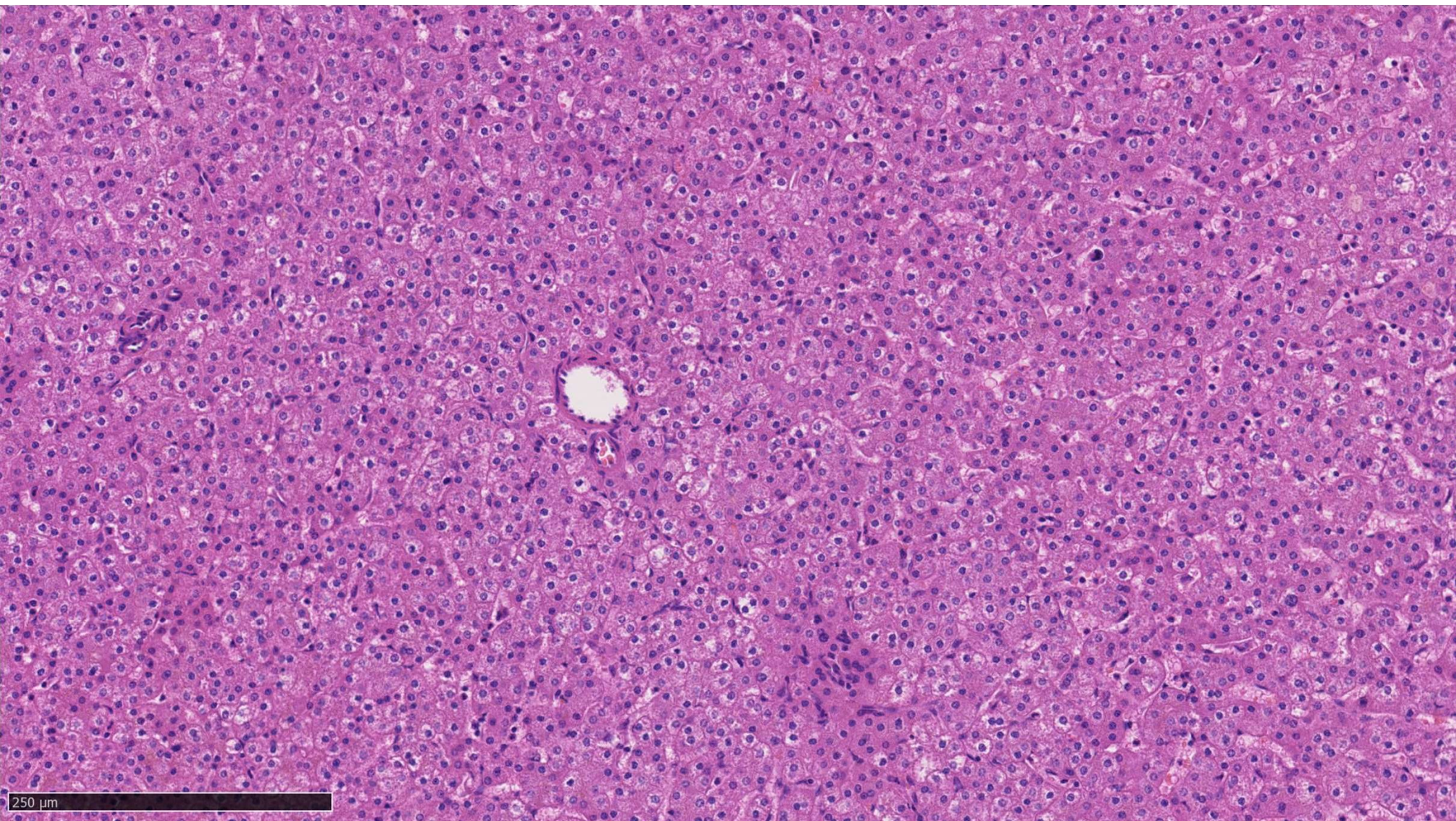


**Fig. 2. The genotype/phenotype classification of hepatocellular adenomas (HCAs).** The main molecular subtypes of HCA linked with specific risk factors, clinical features and risk of complications were represented. Mixed forms between inflammatory HCA (IHCA) and  $\beta$ -catenin exon 3 mutated HCA, and between IHCA and  $\beta$ -catenin mutated HCA exon 7/8 have been described.

*CASE*

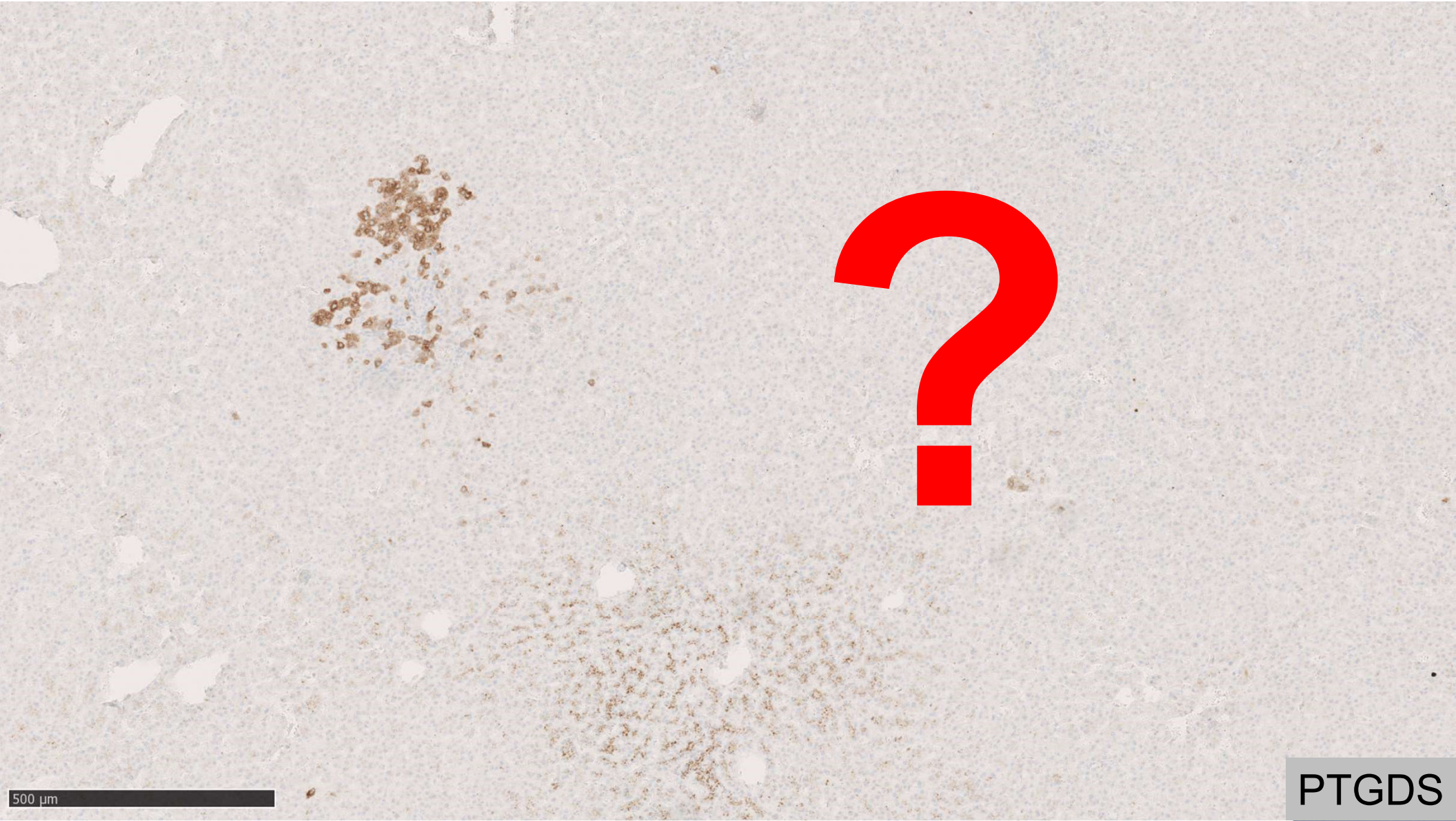





250  $\mu$ m





500  $\mu\text{m}$

PTGDS



## *Diagnosis*

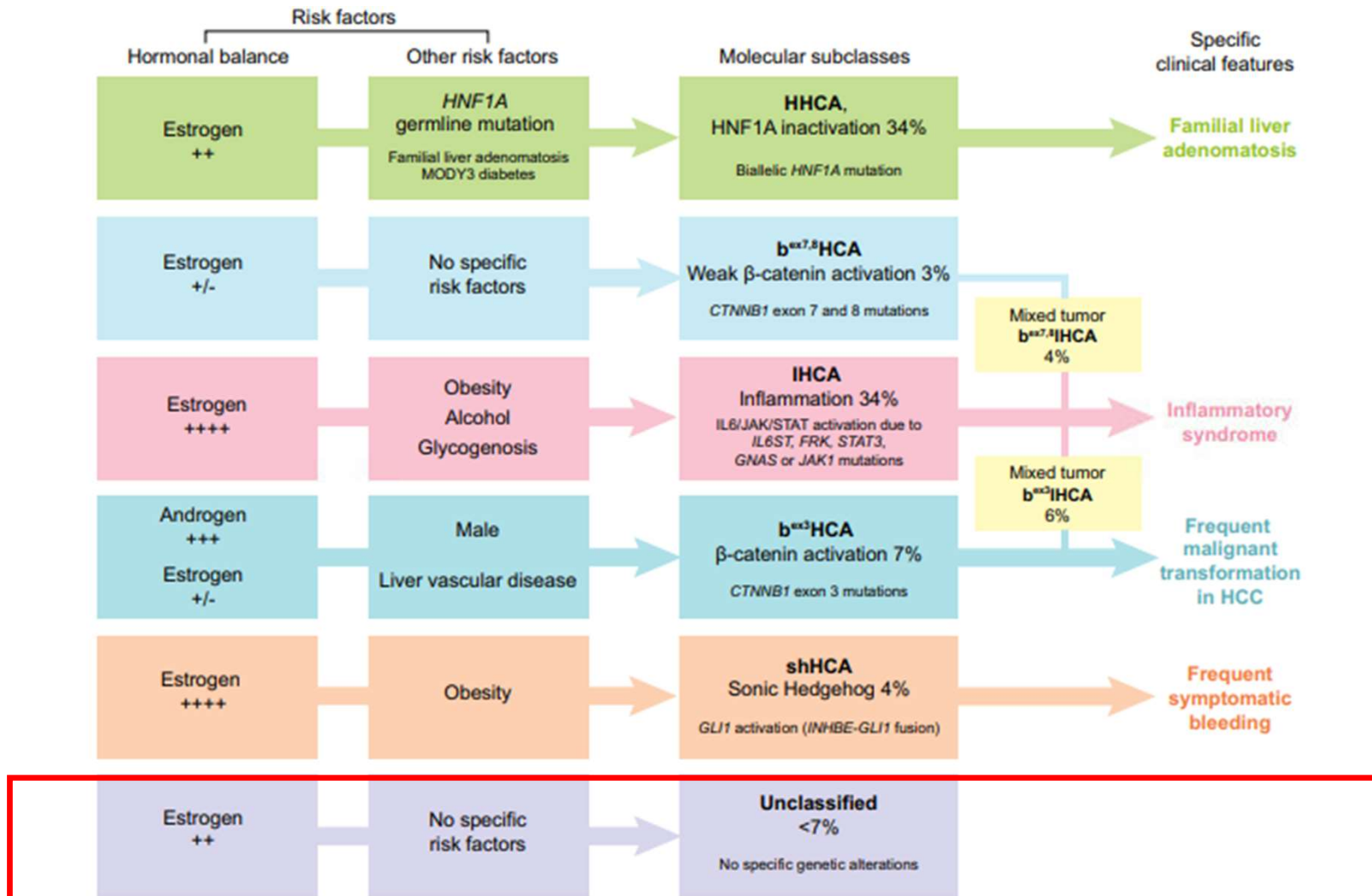
- shHCA? Unclassified HCA?
- NGS
  - No variants in CTNNB1 (exon 3, 7, 8), TERT promoter, IL6ST, STAT3, FRK, GNAS, JAK1, HNF1A

This patients also had IHCA's

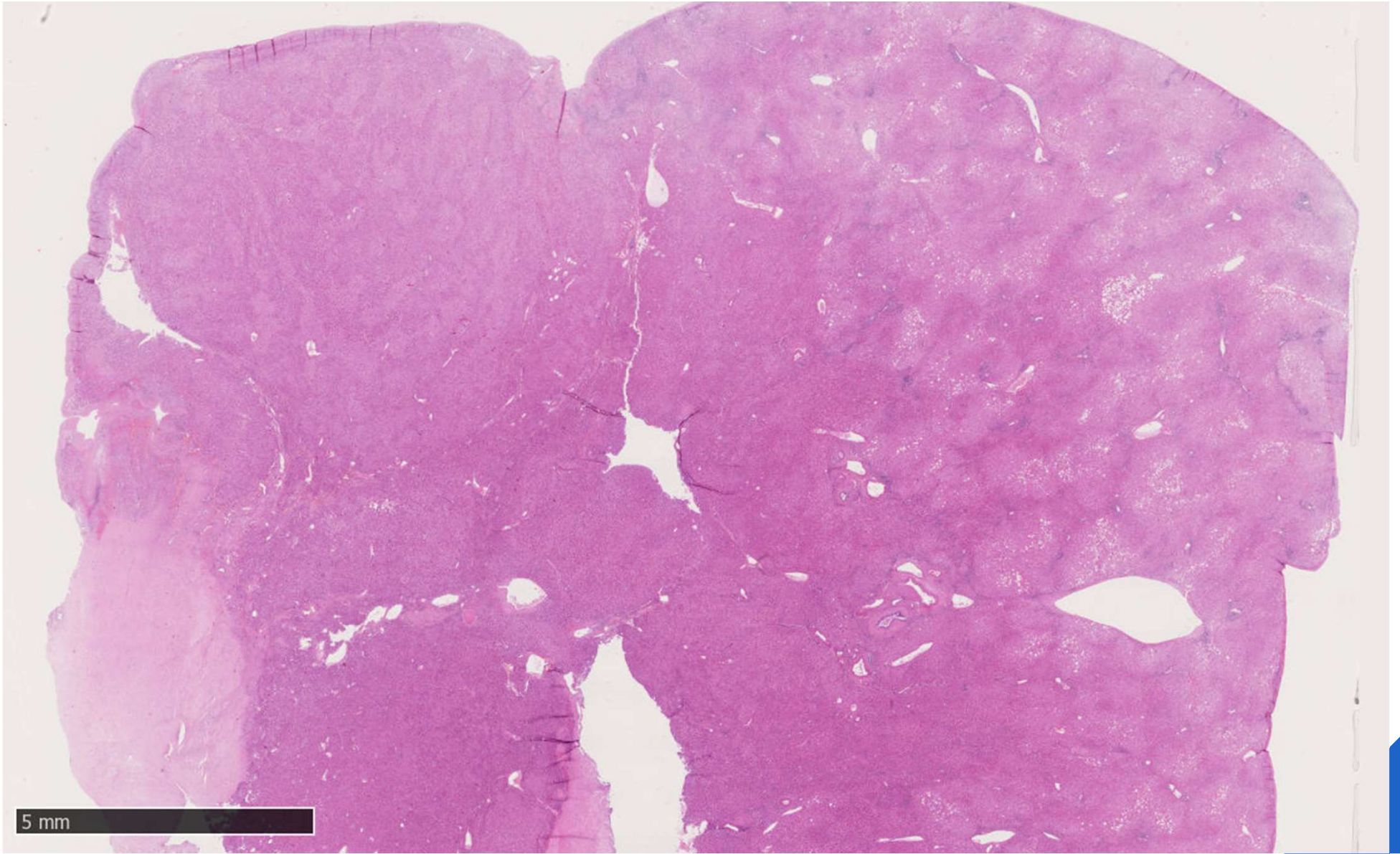
Unclassified HCA 5-10% of all HCAs

- Lack well-defined pathological or genetic findings



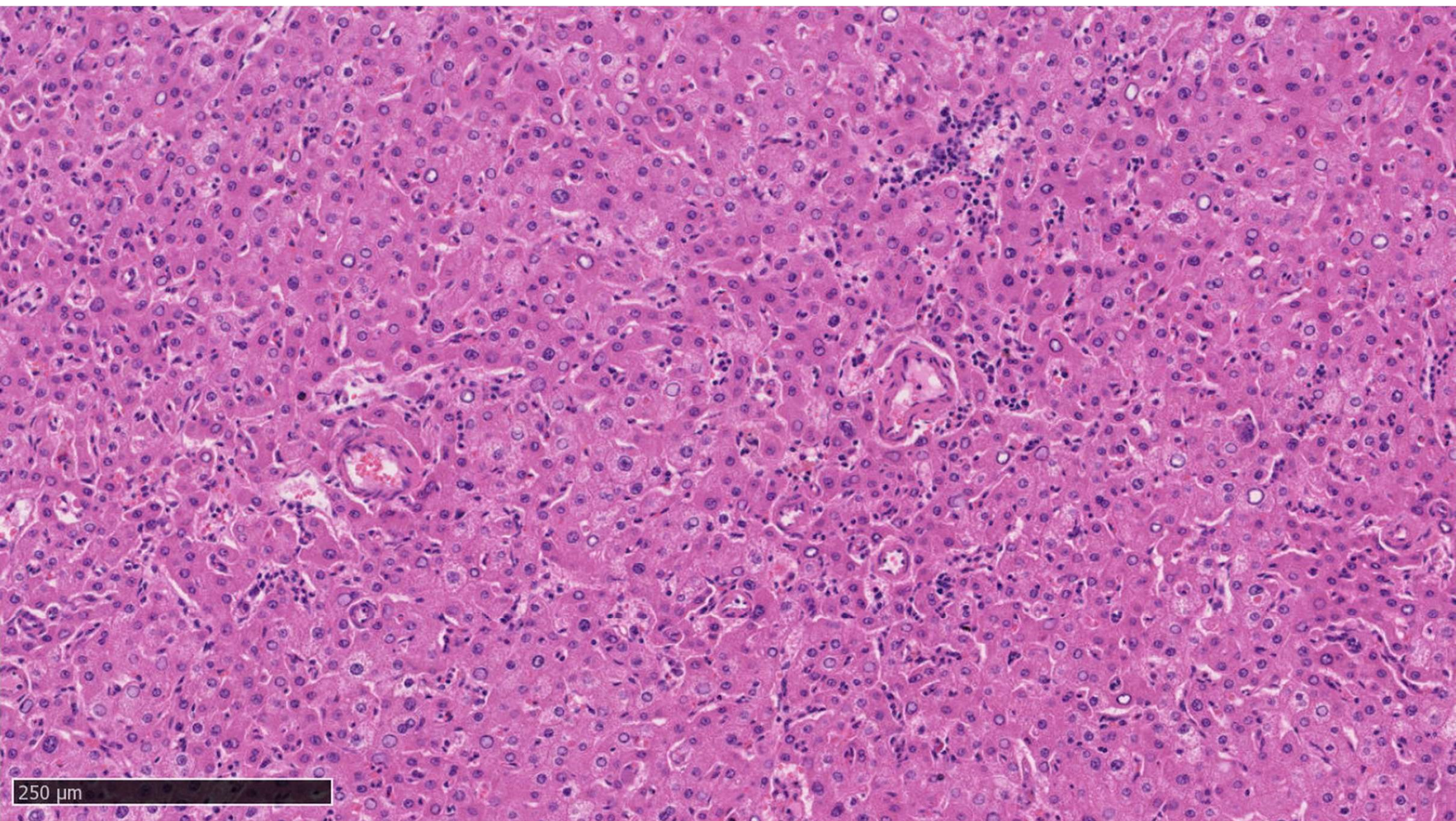


**Fig. 2. The genotype/phenotype classification of hepatocellular adenomas (HCAs).** The main molecular subtypes of HCA linked with specific risk factors, clinical features and risk of complications were represented. Mixed forms between inflammatory HCA (IHCA) and  $\beta$ -catenin exon 3 mutated HCA, and between IHCA and  $\beta$ -catenin mutated HCA exon 7/8 have been described.

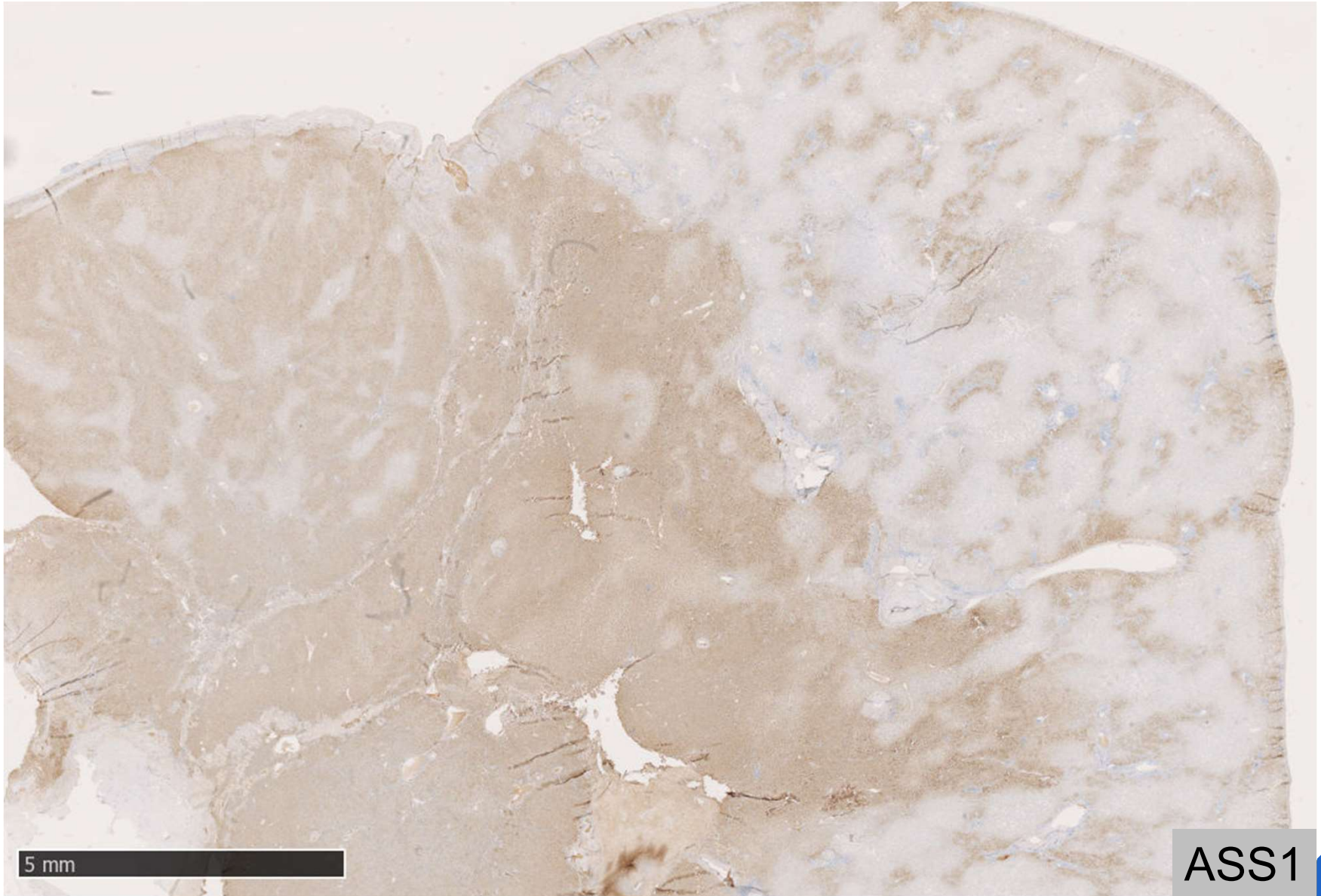


5 mm









5 mm

ASS1



## *Diagnosis*

- Unclassified HCA? shHCA?
- NGS
  - No variants in CTNNB1 (exon 3, 7, 8), TERT promoter, IL6ST, STAT3, FRK, GNAS, JAK1, HNF1A

## HCA prognosis/prediction - management guidelines HCA

- Biopsies to assess diagnosis
  - Surgical resection
    - For tumors >5 cm
    - Irrespective of size if other high-risk features (male, androgen-associated,  $\beta$ -catenin activation, borderline features)
  - $\beta$ -catenin activation can direct management, especially in small and multiple tumors
- GS good surrogate marker to identify different CTNNB1 mutations
- Accurate assessment of GS staining crucial for diagnosis



- **Inconclusive GS pattern for evaluation of malignancy risk**
  - High in cases with exon 3 mutations
  - Low/absent in cases with exon 7/8 mutations

**Molecular/cytogenetic testing for CTNNB1 mutation, TERT promoter mutations, and chromosomal gains (1, 7, and 8) can be helpful**

## NGS Universitair Ziekenhuis Gent Prof. J. Van der Meulen

73 genen SOLID MDG DNA NGS panel (Roche KAPA HyperCap): *AKT1, ALK, APC, AR, ARID1A, ATM, BAP1, BRAF, BRCA1, BRCA2, CCND1, CDK12, CDK4, CDK6, CDKN2A, CDKN2B, CTNNB1, DICER1, DPYD, EGFR, ERBB2, ERBB3, ESR1, FBXW7, FGFR1, FGFR2, FGFR3, FGFR4, FOXL2, FKR, GATA3, GNA11, GNAQ, GNAS, H3-3A, H3-3B, H3C2, H3C3, HNF1A, HRAS, IDH1, IDH2, IL6ST, JAK1, JAK2, KEAP1, KIT, KRAS, MAP2K1, MET, MYOD1, NRAS, NTRK1, NTRK2, NTRK3, PDGFRA, PDGFRB, PIK3CA, PIK3R1, POLE, PTEN, RB1, RET, RNF43, ROS1, SMAD4, SMO, SPOP, STAT3, STK11, TERT, TP53, VHL*

Panel encompasses genes characteristic for

- bHCA

**CTNNB1 exon 2, 3, 4, 7, 8** / NM\_001904.4 / build hg38

- IHCA

**GNAS exon 7, 8, 9** / NM\_000516.5 / build hg38

**JAK1 exon 15, 16** / NM\_002227.4 / build hg38

**FRK exon 6** / NM\_002031.3 / build hg38

**STAT3 exon 3, 6, 17, 20, 21** / NM\_139276.2 / build hg38

**IL6ST exon 6, 10** / NM\_002184.3 / build hg38

- HHCA

**HNF1A all exons** / NM\_000545.6 / build hg38

- Malignant transformation in HCA

**TERT promoter region** / NM\_198253.2 / build hg38



# DDx

## Focal nodular hyperplasia

- Typical FNH features (nodularity, fibrous septa, ductular reaction) can be seen in IHCA
- Map-like GS staining in FNH + SAA/CRP positivity in IHCA help in DDx

## Hepatocellular carcinoma

- Thick cell plates, f. pseudoglands, small-cell change, mitoses, loss/fragmentation of the reticulin network typical of HCC
- IHC for glypican-3 (GPC3) or HSP70 favors HCC, but is not helpful in most cases
- Arterialized sinusoids (CD34+) are f. in HCCs, but can also be seen in benign lesions, including FNH and HCA

## Epithelioid angiomyolipoma

- Can resemble steatotic HCA (e.g, HHCA, IHCA) and can show diffuse GS staining
- IHC demonstration of myomelanocytic differentiation confirms diagnosis of angiomyolipoma

# Focal nodular hyperplasia



## FNH definition/epidemiology

- Mass-forming hyperplastic response of hepatocytes resulting from localized vascular malformation
- 2nd most f. benign liver nodule (after hemangioma)
- 80-90% young women, rarely men
- Rare in children:
  - Sporadic (rare)
  - Post chemotherapy for various pediatric malignancies  
Up to 8%, median lag time 10 y.

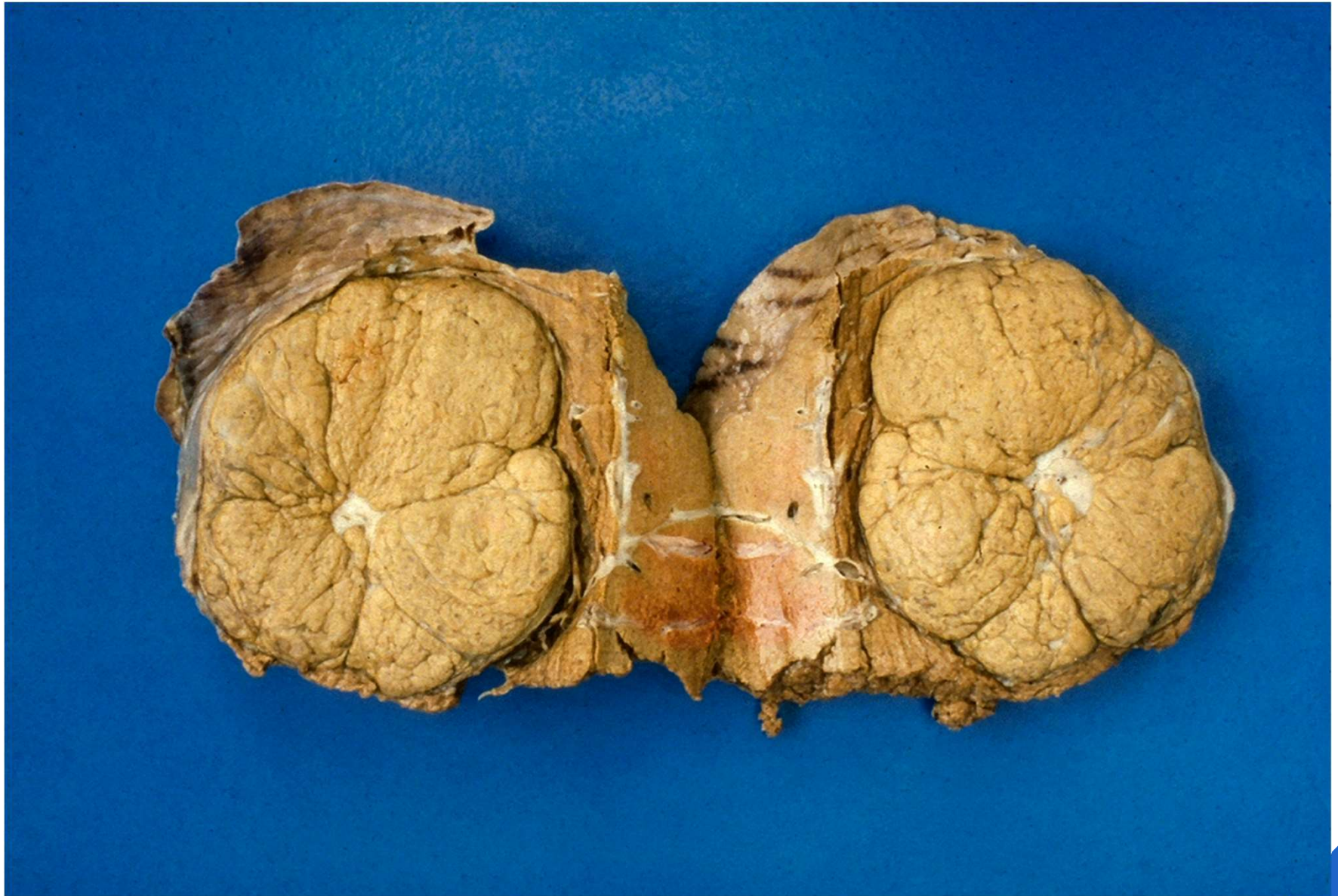## FNH clinical characteristics

- 75% solitary and <5 cm
- Background liver usually normal
- Can in association with vascular diseases
  - Portal vein thrombosis or atresia
  - Budd–Chiari syndrome
  - Hereditary hemorrhagic telangiectasia
- Can adjacent to mass lesions
- 90% accurate diagnosis on imaging  
Biopsy only required if atypical imaging features

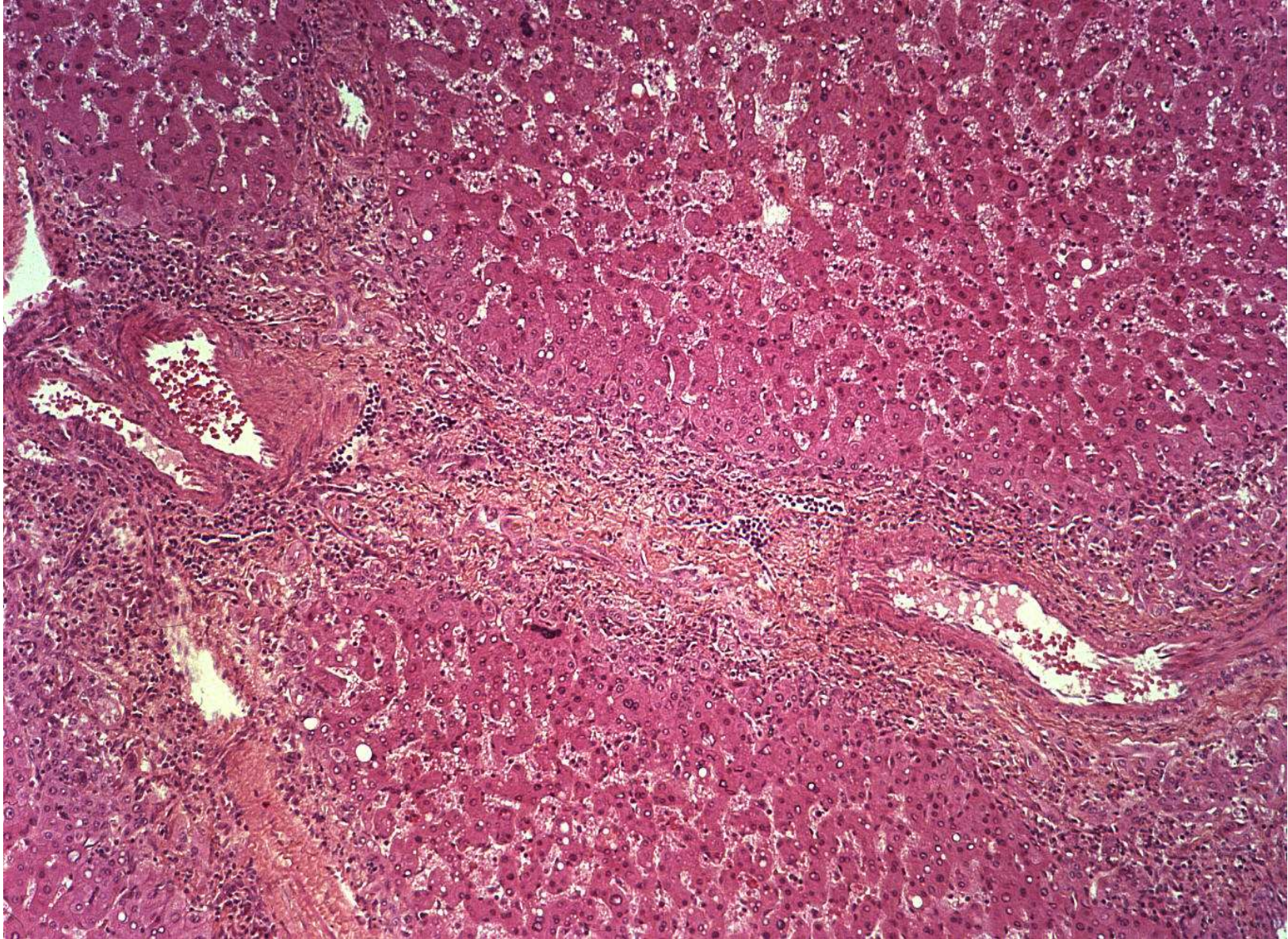


## FNH macroscopy/histopathology

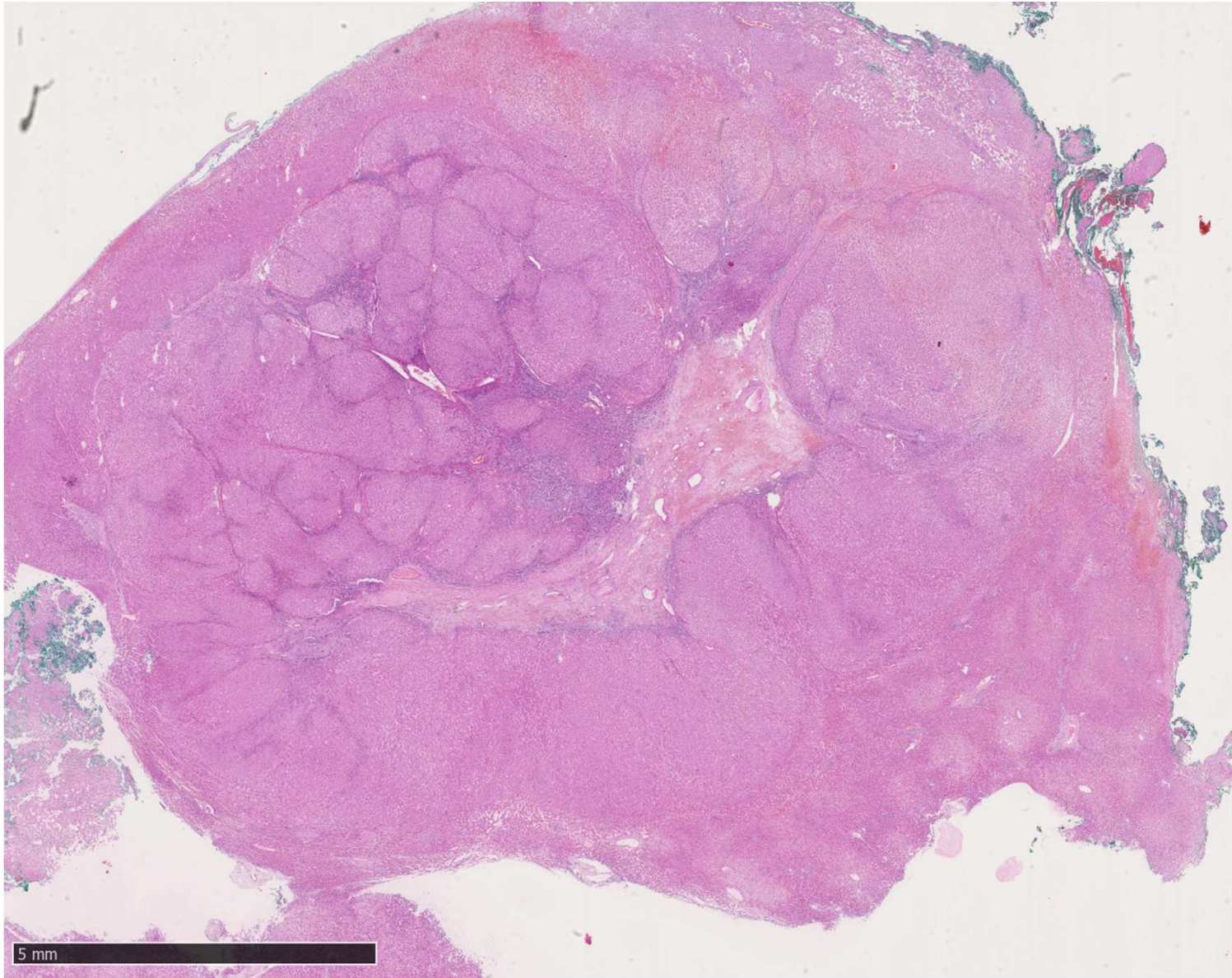
- Pale, firm, well-delineated, unencapsulated mass
- Few mm to >10 cm
- Multinodular with hepatocytes in plates no more than 2 cells thick
- Central fibrous scar with radiating septa with large dystrophic vessels and numerous small arterioles
  - Some FNH lack central scar
- Portal tract-like structures
  - Artery unaccompanied by portal veins/ducts, often inflammatory infiltrate
  - Ductular reaction at interface (CK7/CK19)
- Often features of cholate stasis
  - Feathery degeneration of hepatocytes
  - Mallory–Denk bodies
- Patchy/diffuse CD34 staining



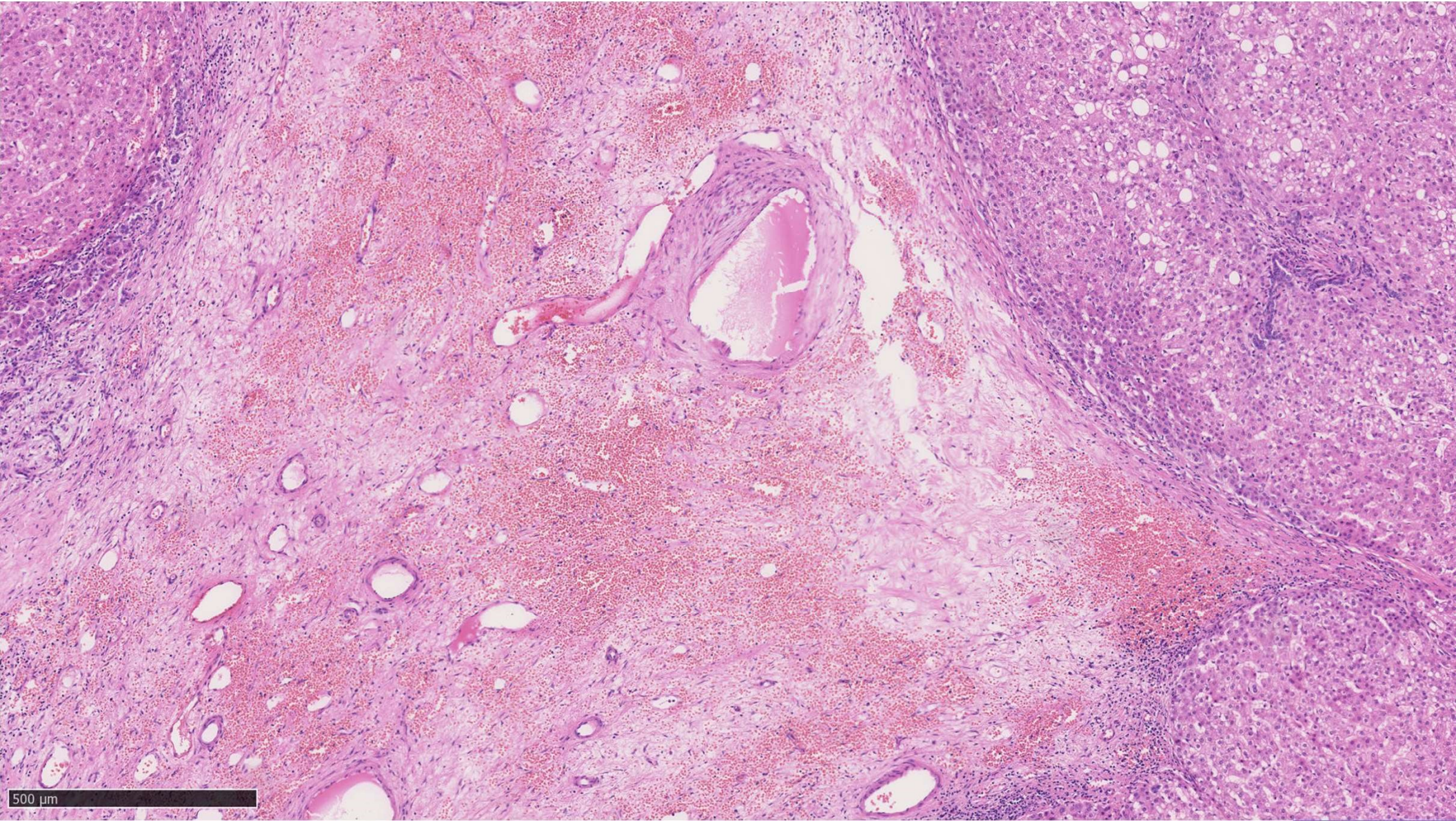






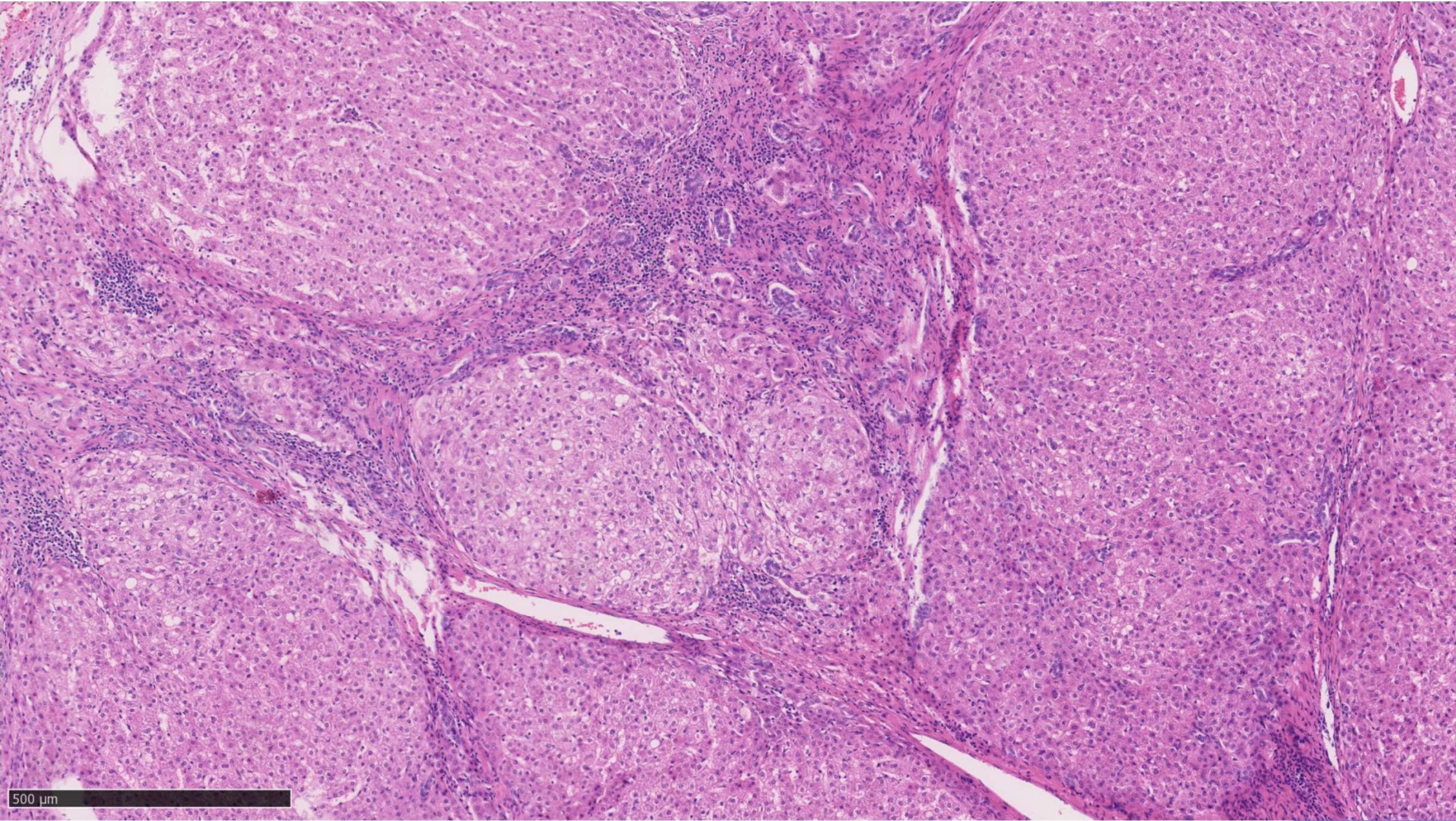






500  $\mu$ m



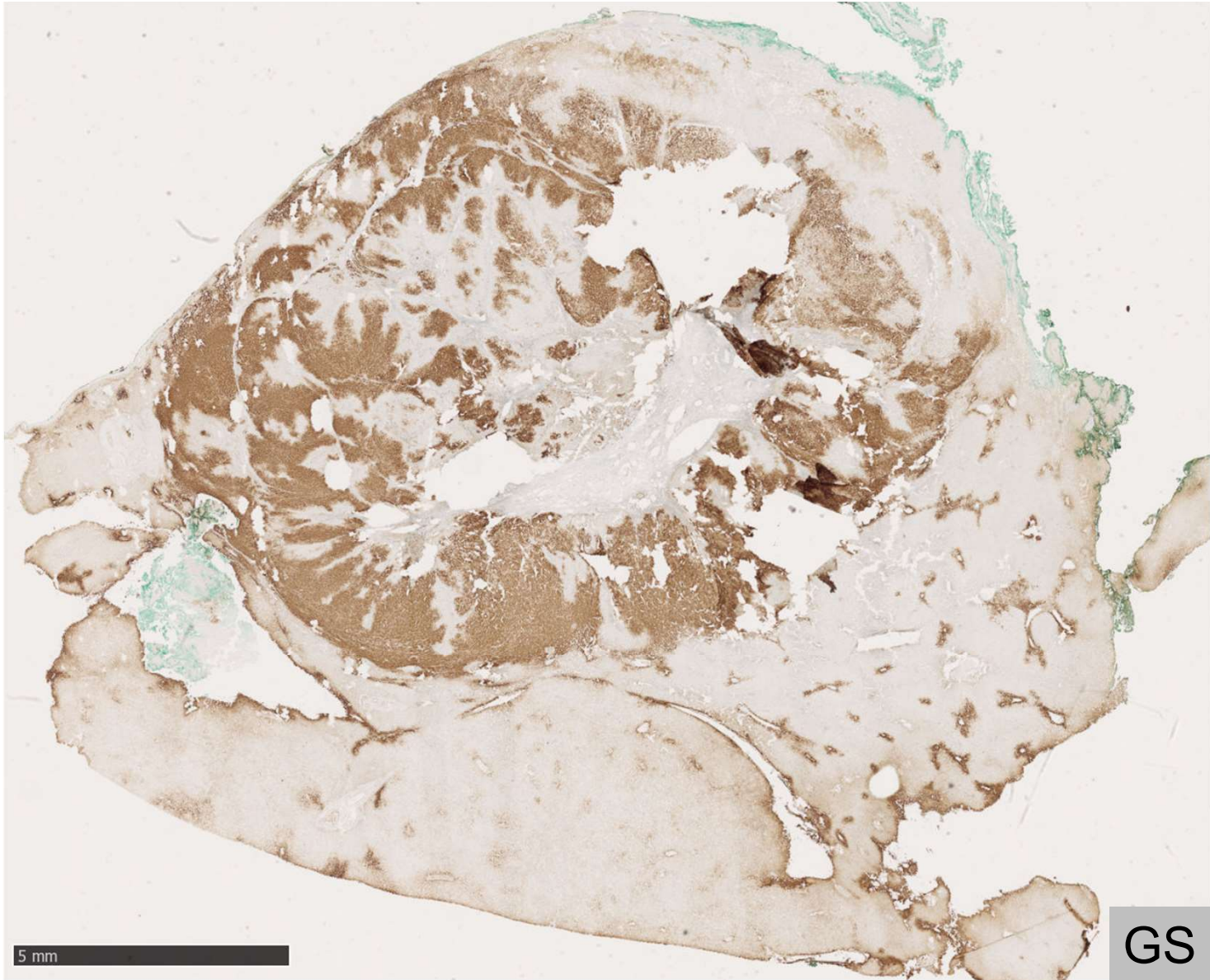


500 μm



## FNH genetics/immunohistochemistry

- Polyclonal
- $\beta$ -catenin activation without mutations in *CTNNB1/AXIN1*  
Overexpression of Wnt/ $\beta$ -catenin target genes  
Explains expansion of **glutamine synthetase (GS)** staining in hepatocytes
- Useful for diagnosis, also on biopsies  
**Characteristic map-like pattern**  
Broad, anastomosing areas of expression in hepatocytes next to hepatic veins





## FNH histopathology

- One/more of typical features (e.g., nodularity, ductular reaction) may not be present
- Steatosis, steatohepatitis-like features, large-cell change can occur
- Vascular diseases or around different kinds of neoplasms  
FNH-like regenerative nodules without all typical features → “FNH-like” nodules

## FNH management

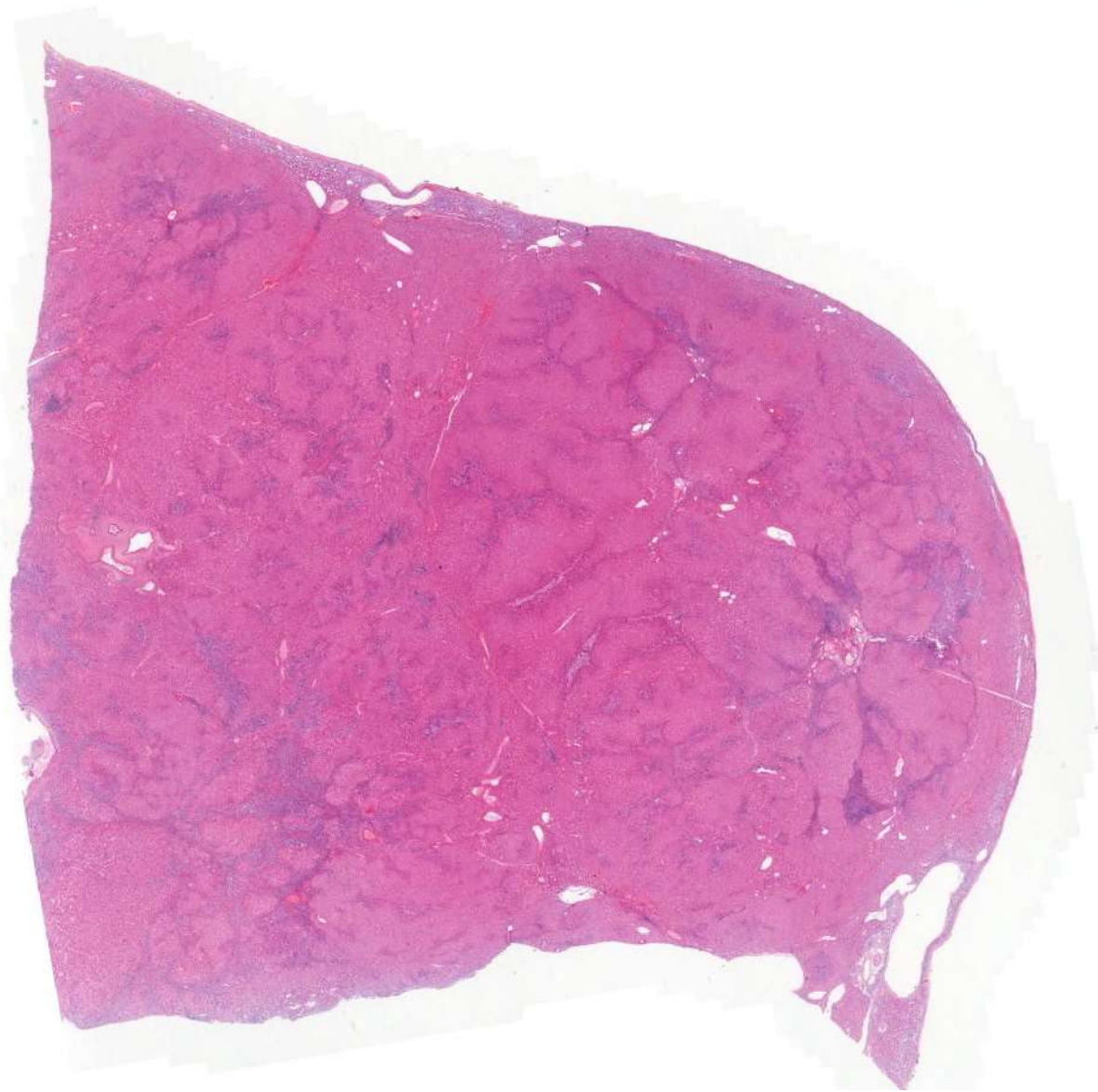
- If no symptoms conservative management
- Certain diagnosis: no follow-up indicated  
Doubtful diagnosis : biopsy  
Surgery in rare instances when diagnosis not definitive on biopsy
- No indication for discontinuing OC
- Follow-up during pregnancy not necessary



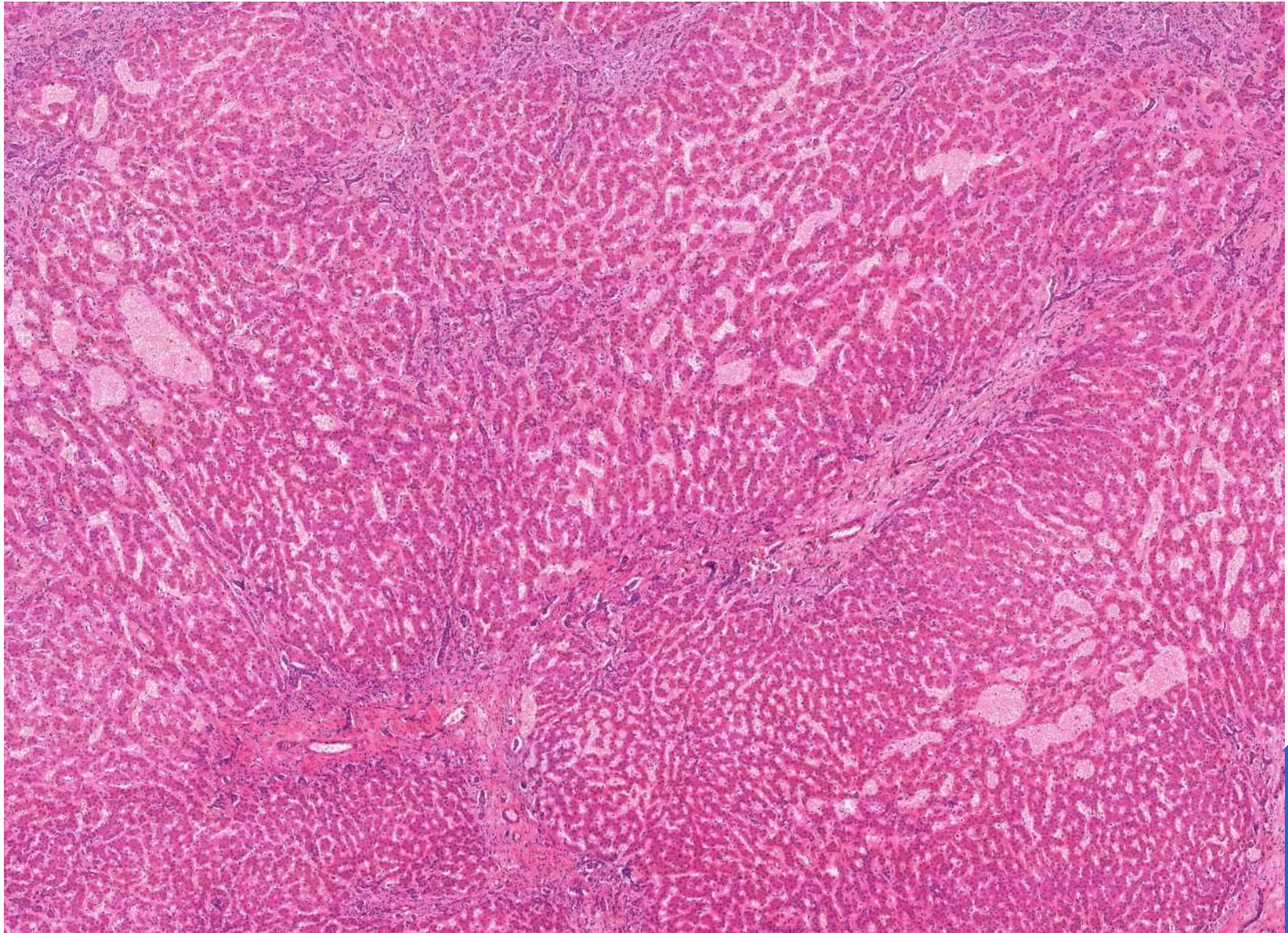
## DDx HCA & HCC

- Fat, isolated arteries, sinusoidal dilatation more common in HCA
- Nodularity, fibrous septa, ductular reaction more typical of FNH
- Histological overlap in 20-30% of cases, especially with IHCA
- IHCA: no map-like GS staining + SAA/CRP positivity
- Patchy SAA or periseptal CRP staining seen in some FNH
- Map-like GS must not be mistaken for diffuse staining in bHCA/HCC in small biopsies
- Periphery FNH may show wider cell plates and focal reticulin loss, which can mimic HCC, especially on needle biopsies

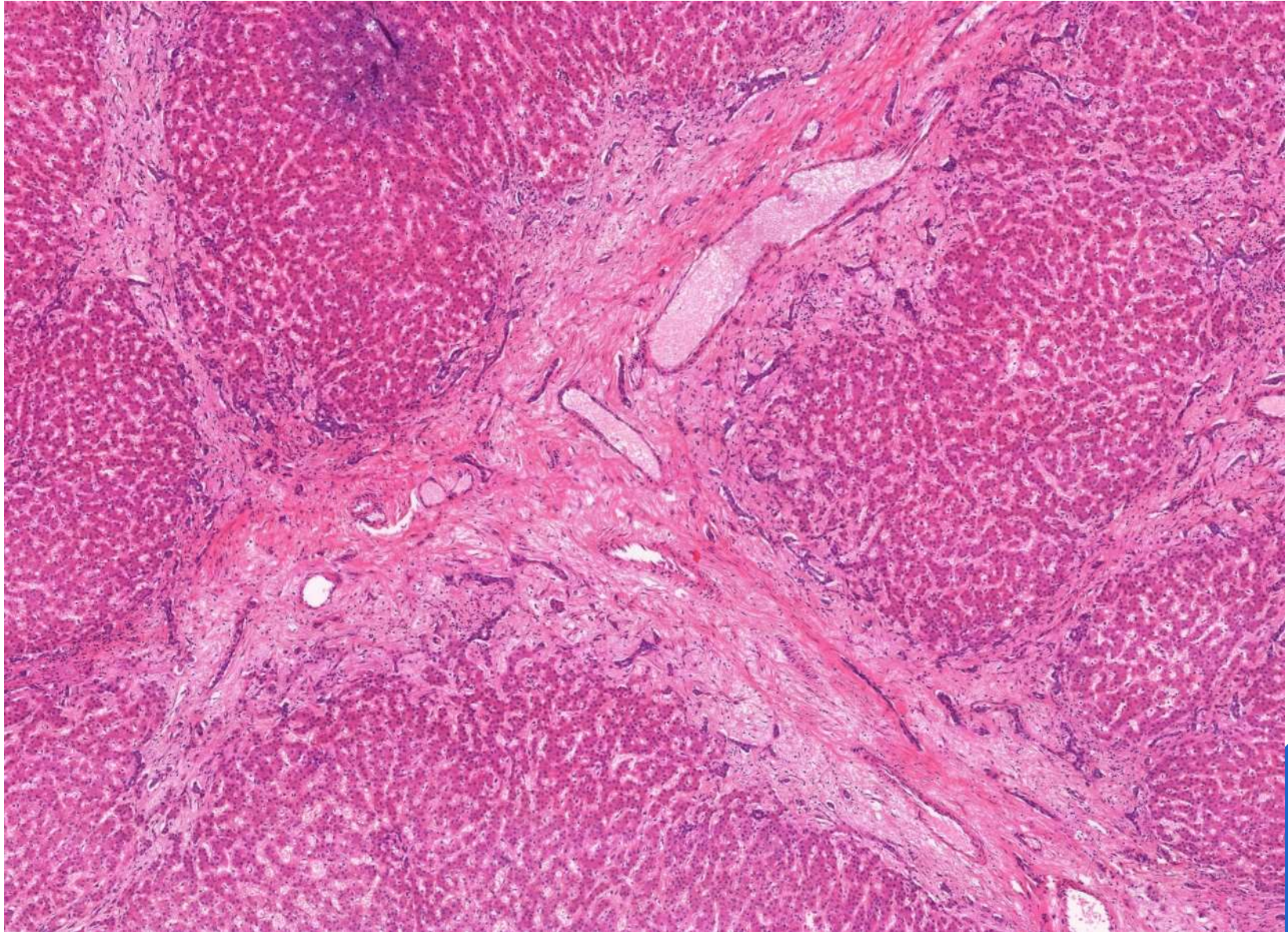
*CASE*



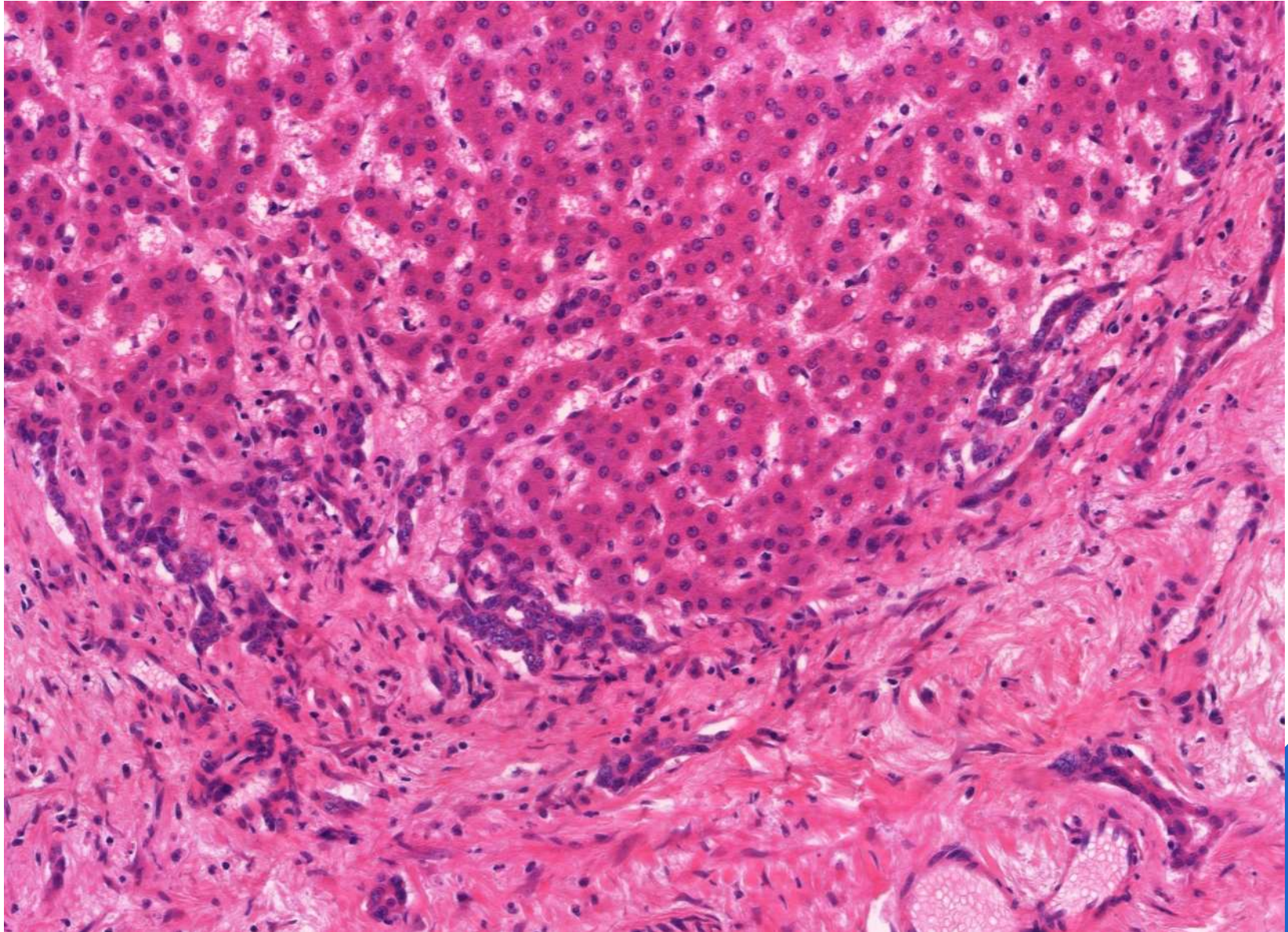




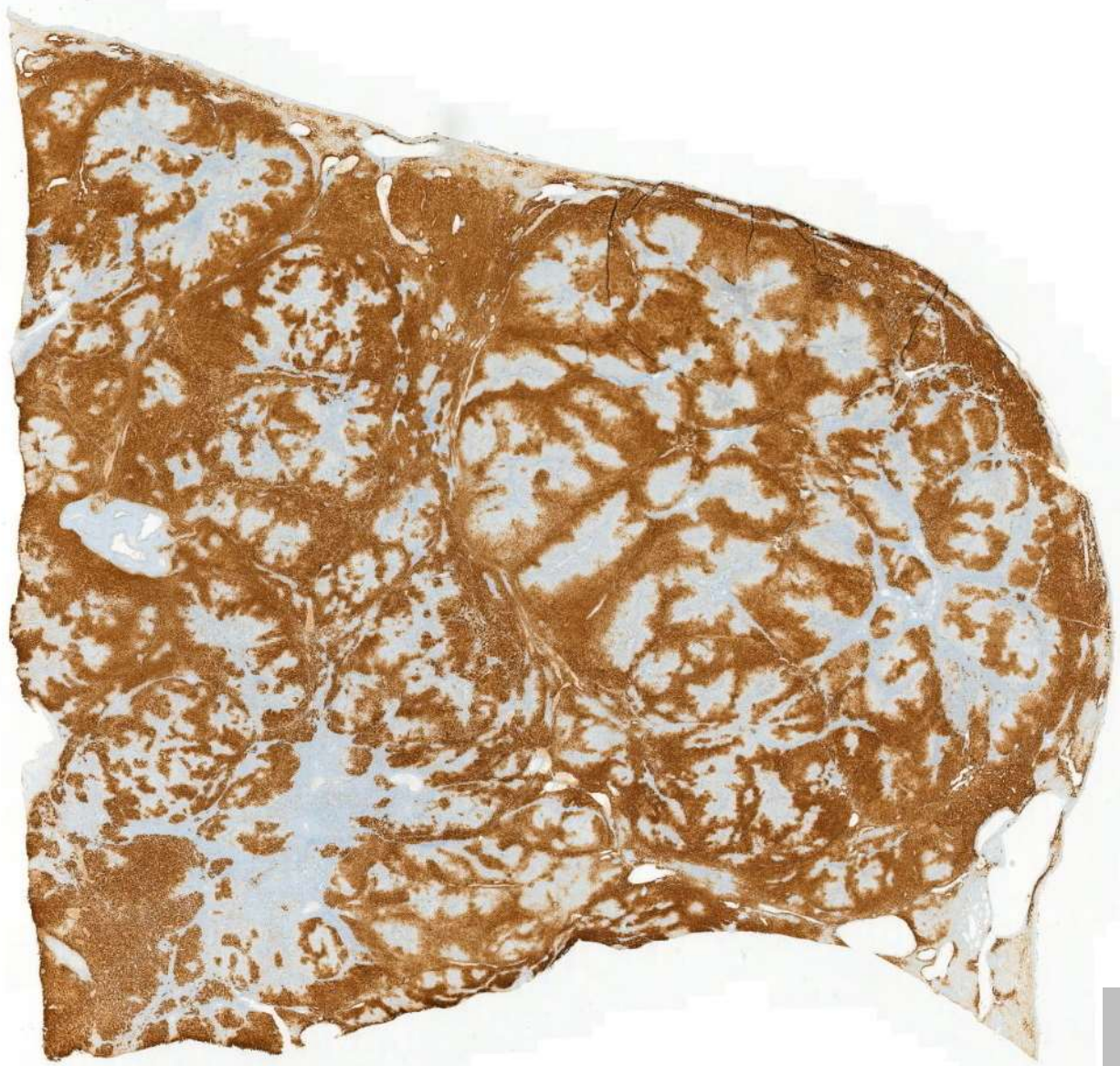











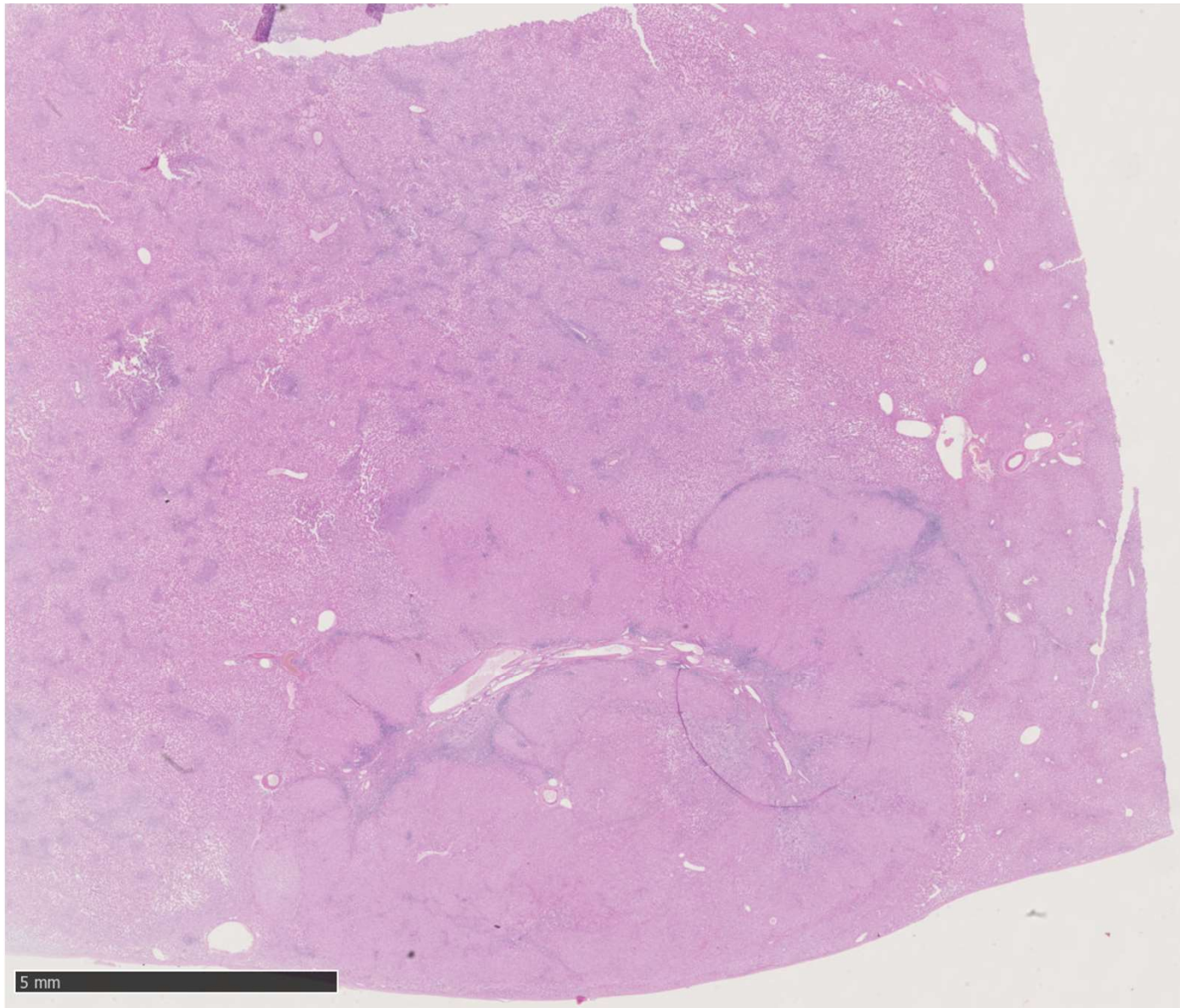
GS



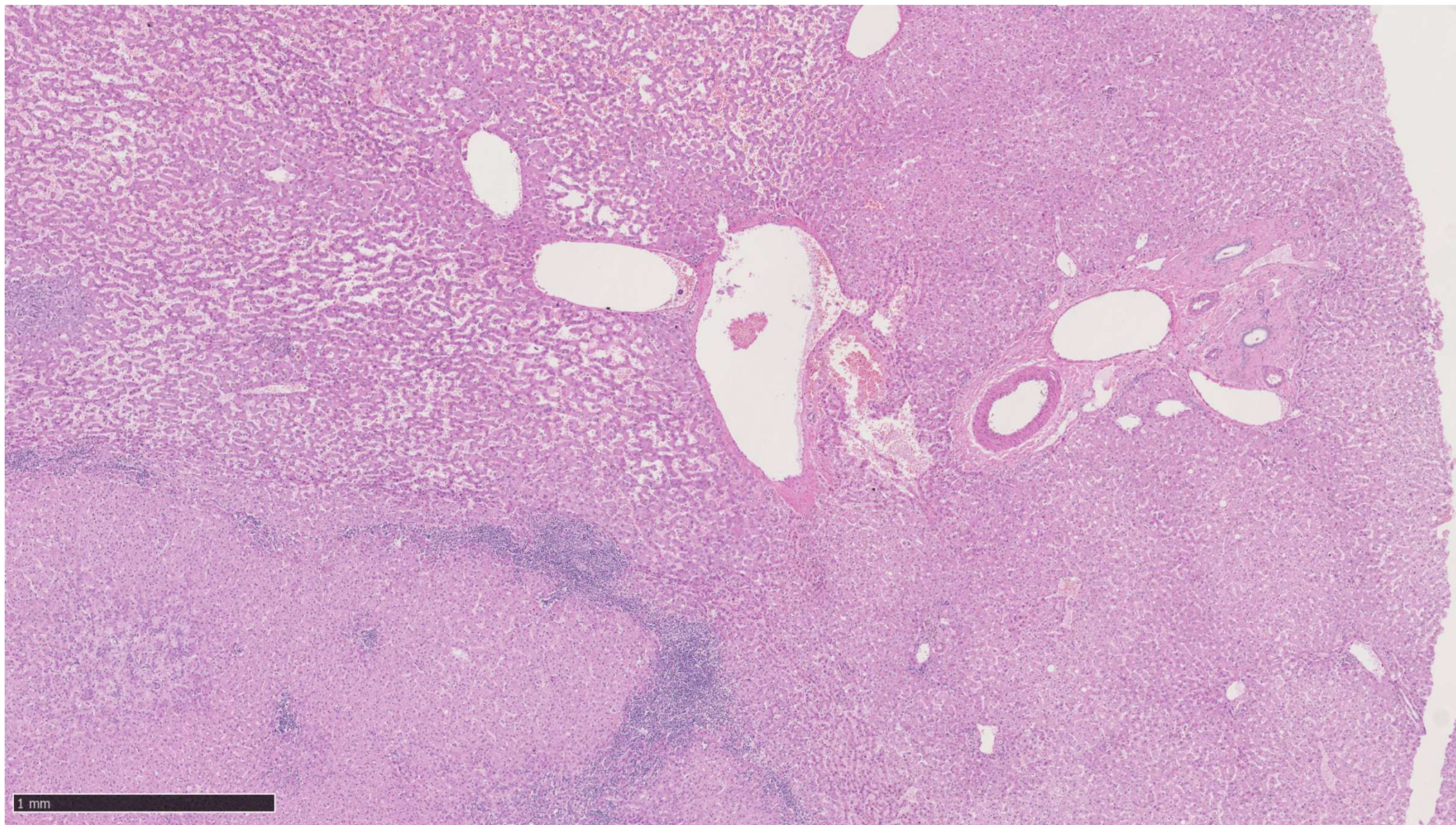
# *Diagnosis*

- FNH with sinusoidal dilatation

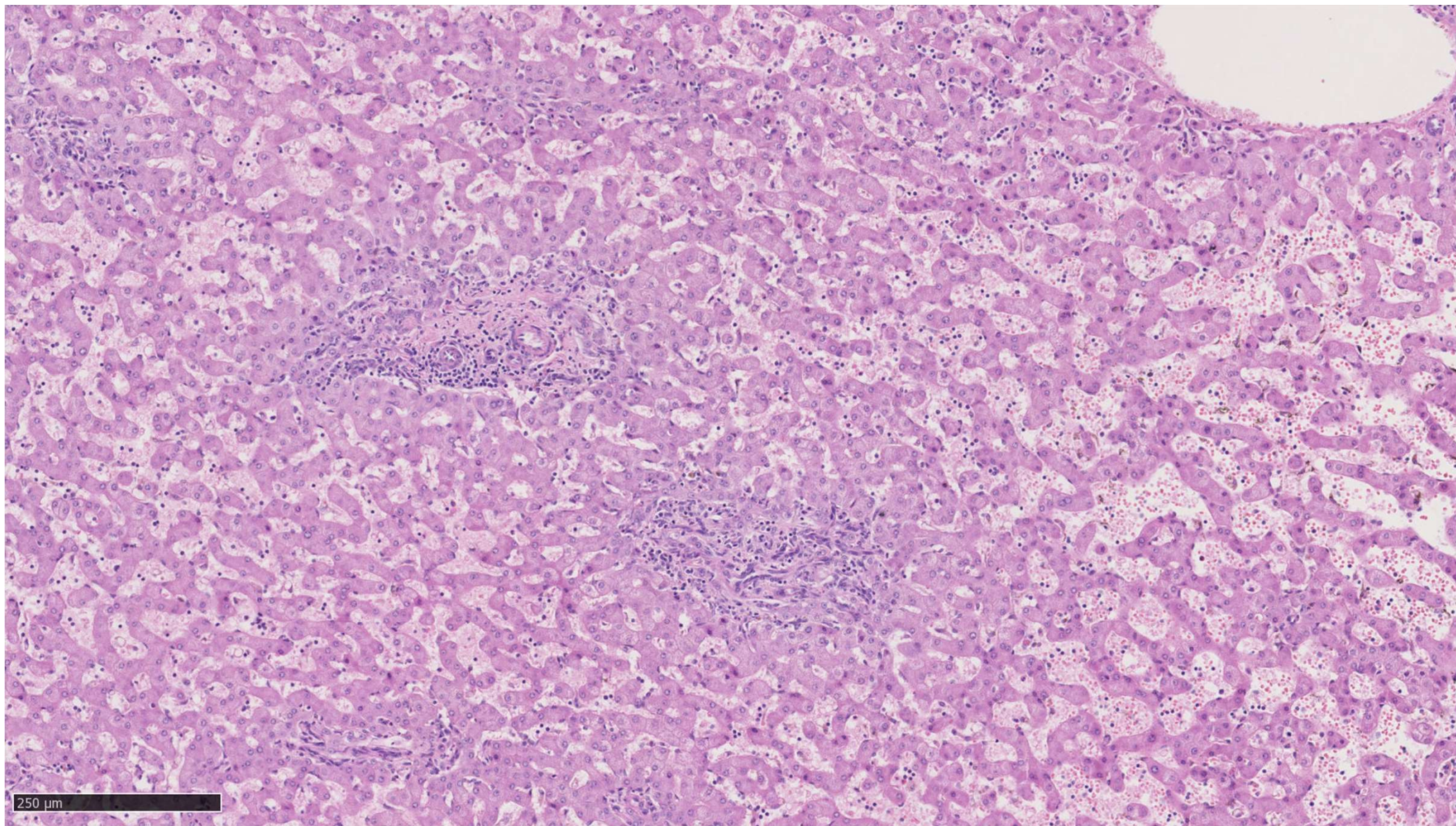
*CASE*





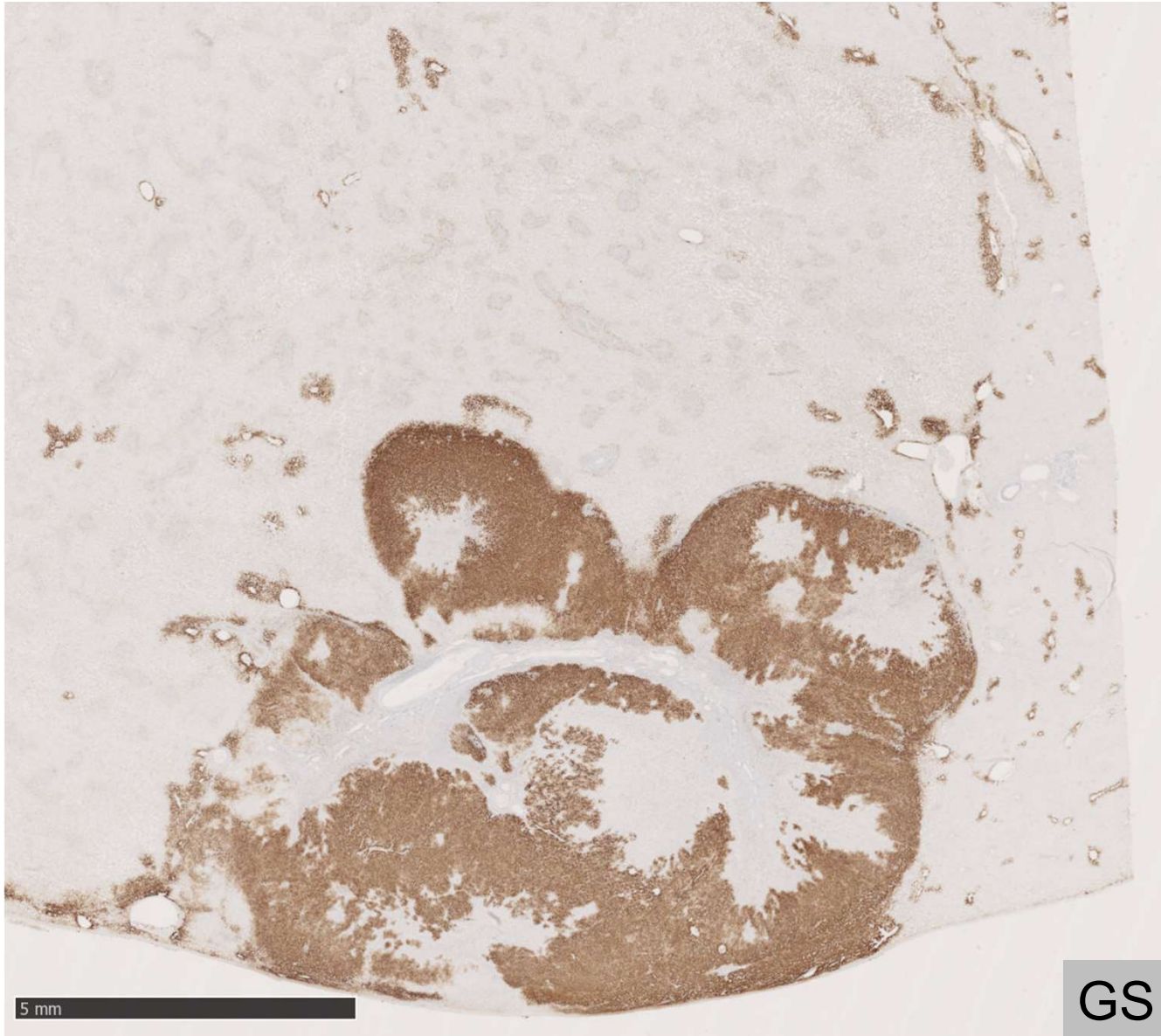






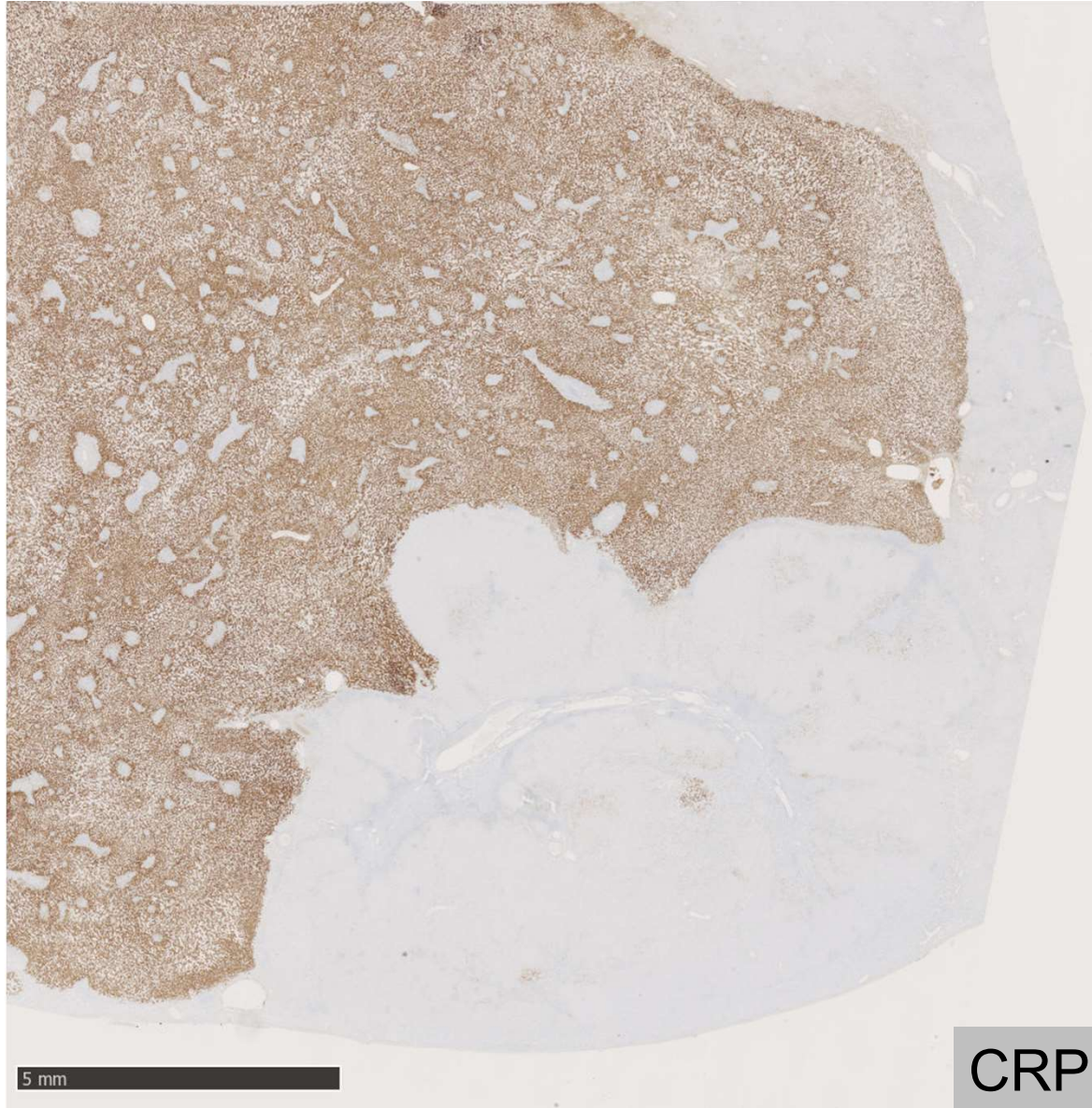
250  $\mu$ m





5 mm

GS



5 mm

CRP





## *Diagnosis*

- IHCA
- No IHC arguments for  $\beta$ -catenin activation
- FNH in vicinity of mass-lesion
  
- No NGS performed



# Bile duct adenoma



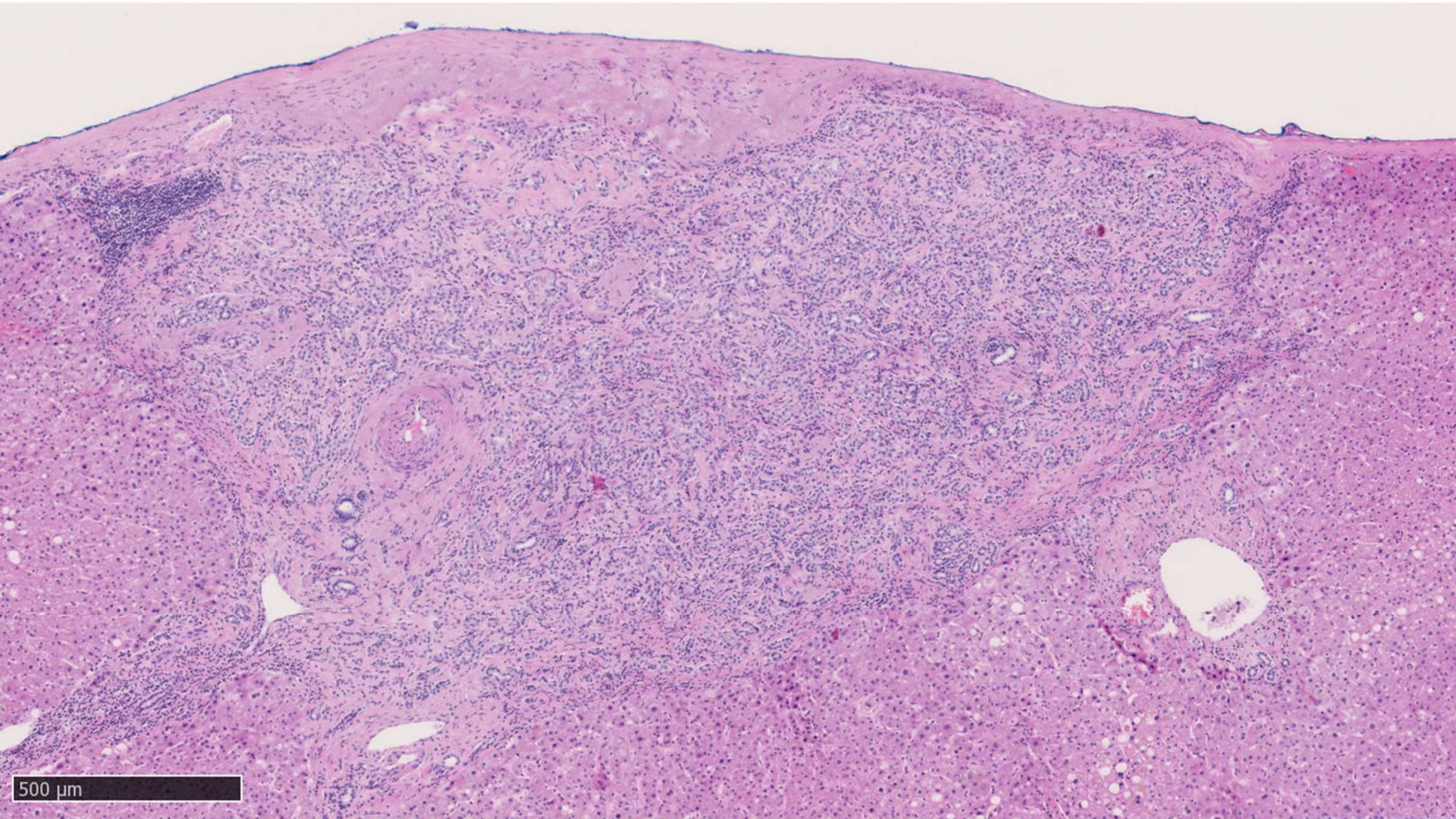
## BDA: clinical characteristics/pathogenesis

- Incidental finding at surgery (intraoperative frozen sections)/autopsy
- BRAF p.V600E mutations in 8/15  
Suggest at least some true neoplasms

## BDA macroscopy/histopathology

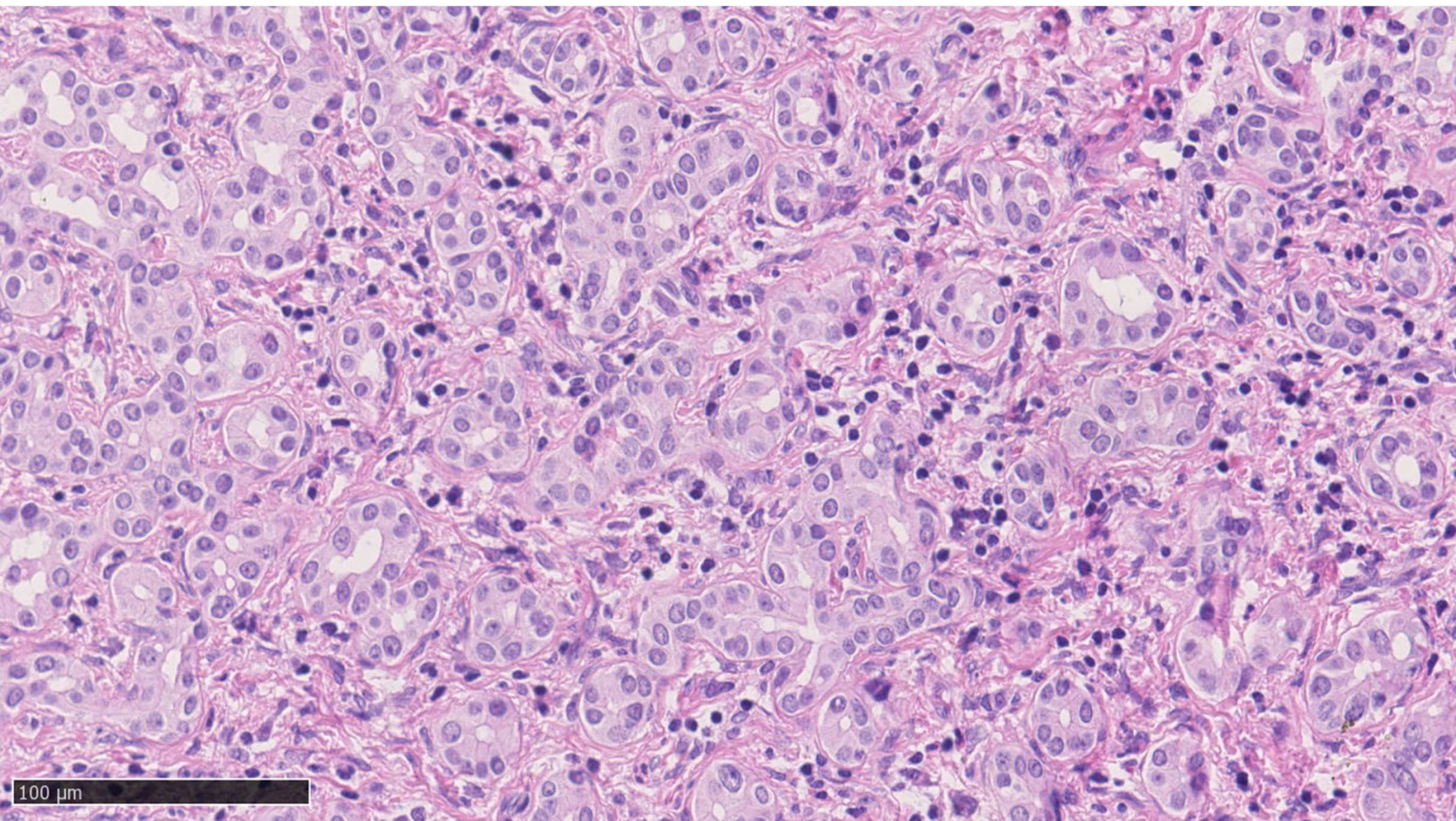
- Usually solitary, subcapsular, white, firm, well-circumscribed nodule
- Usually <1 cm (range 1-20 mm)
- Disordered collection of uniform small ducts in connective tissue stroma with varying degrees of chronic inflammation
- No infiltrative/pushing margin
- Cuboidal cells with regular nuclei, resembling ductules
- Ducts no/little lumen
- Some mucin/more collagenized stroma
- Pre-existing portal tracts often enclosed
- Clear-cell/oncocytic changes described





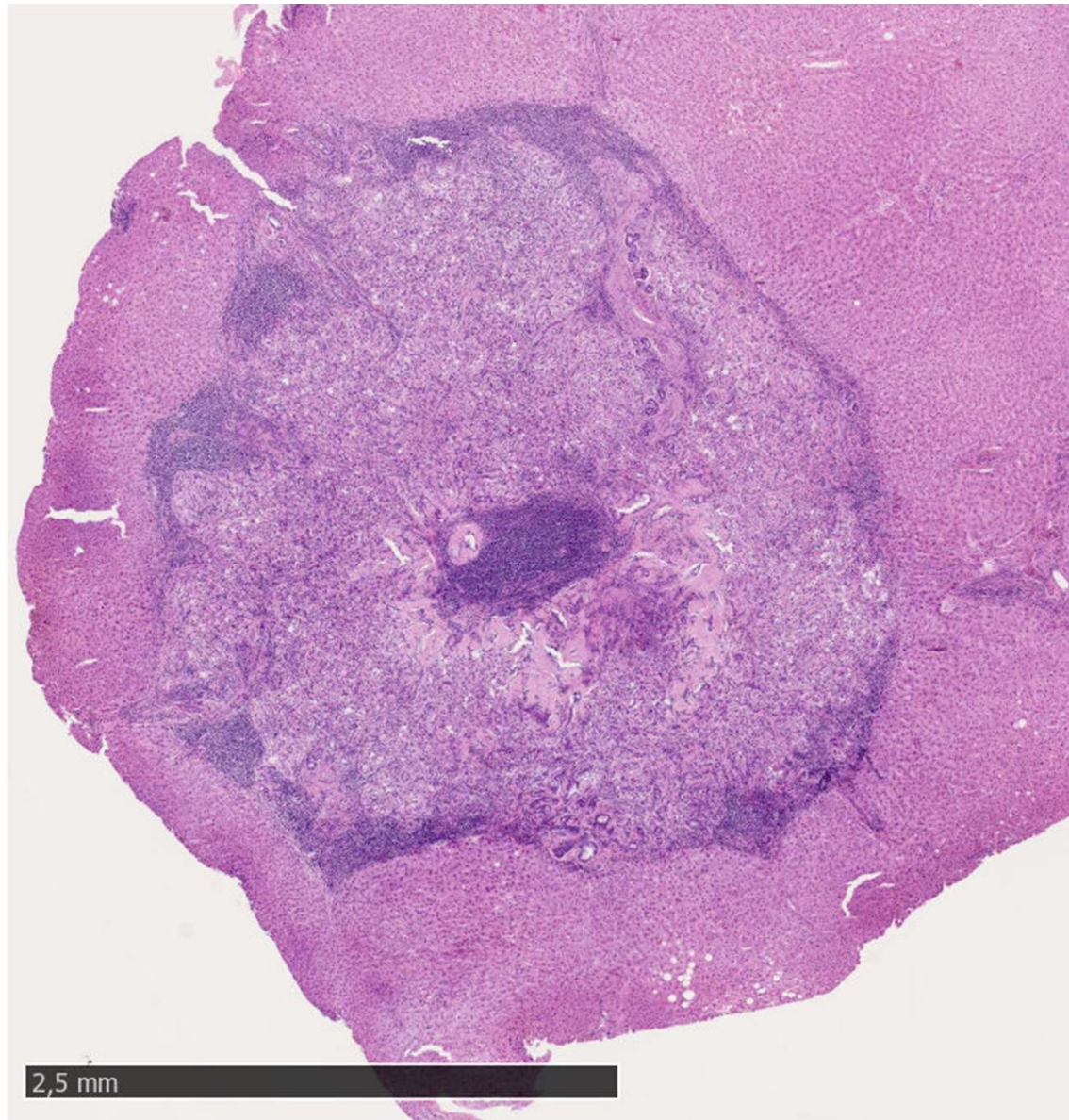
500 μm





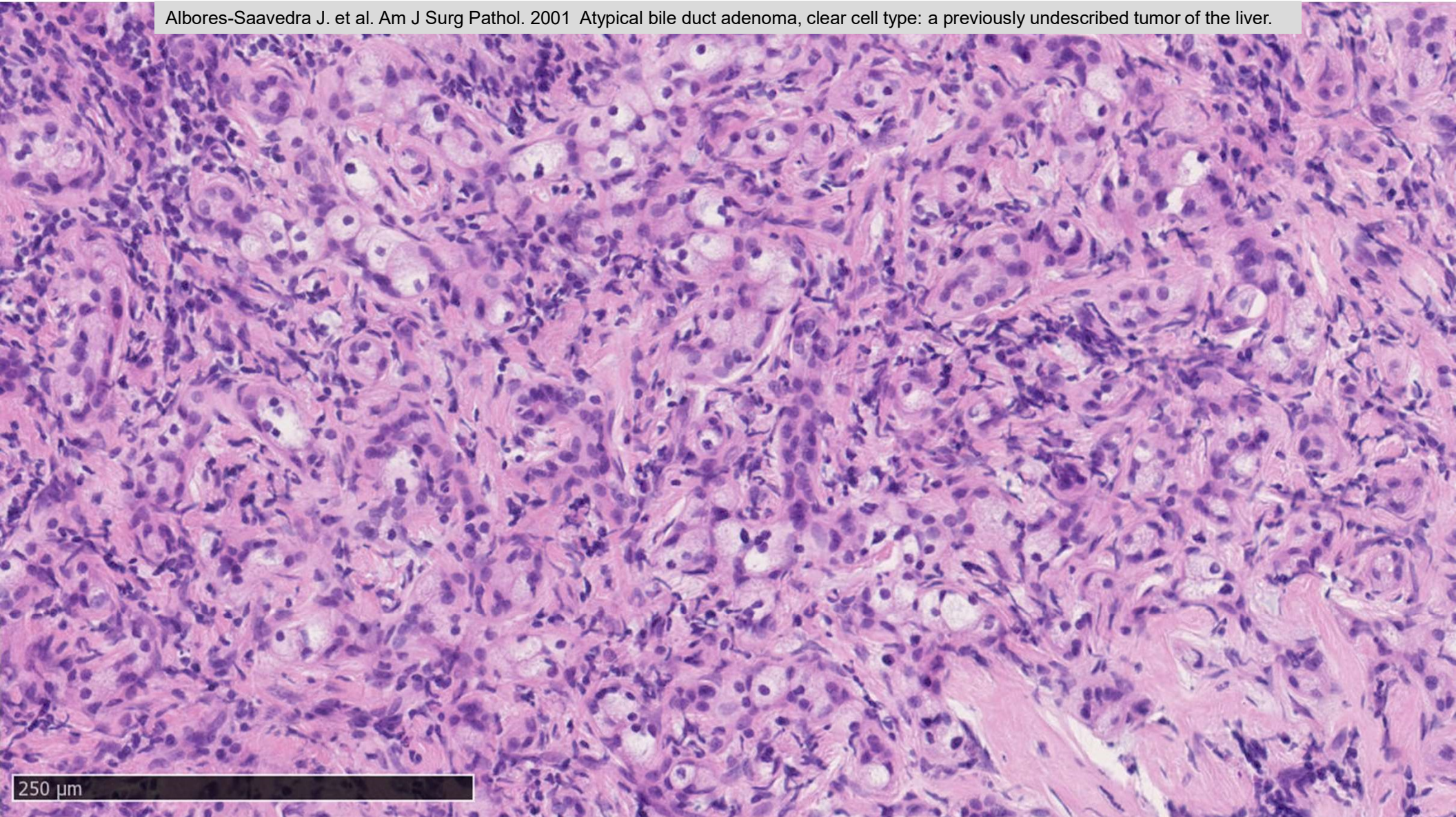


*CASE*



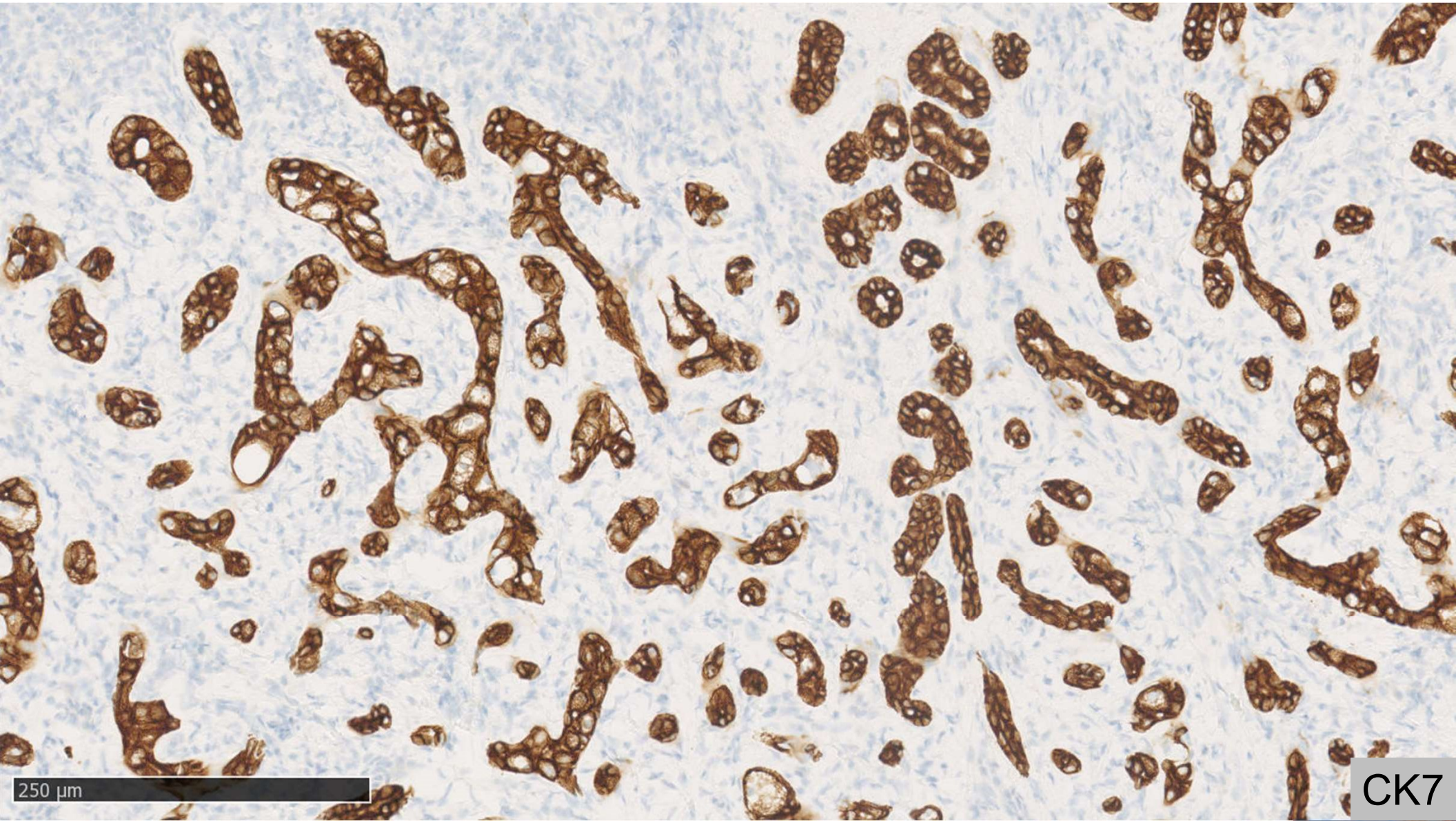


Albores-Saavedra J. et al. Am J Surg Pathol. 2001 Atypical bile duct adenoma, clear cell type: a previously undescribed tumor of the liver.



250  $\mu$ m





250 μm

CK7

## BDA DDX from other solid-microcystic glandular lesions of the liver

### Metastatic pancreatobiliary adenocarcinoma

- Confusion possible, especially in frozen sections

### Cholangiolocarcinoma

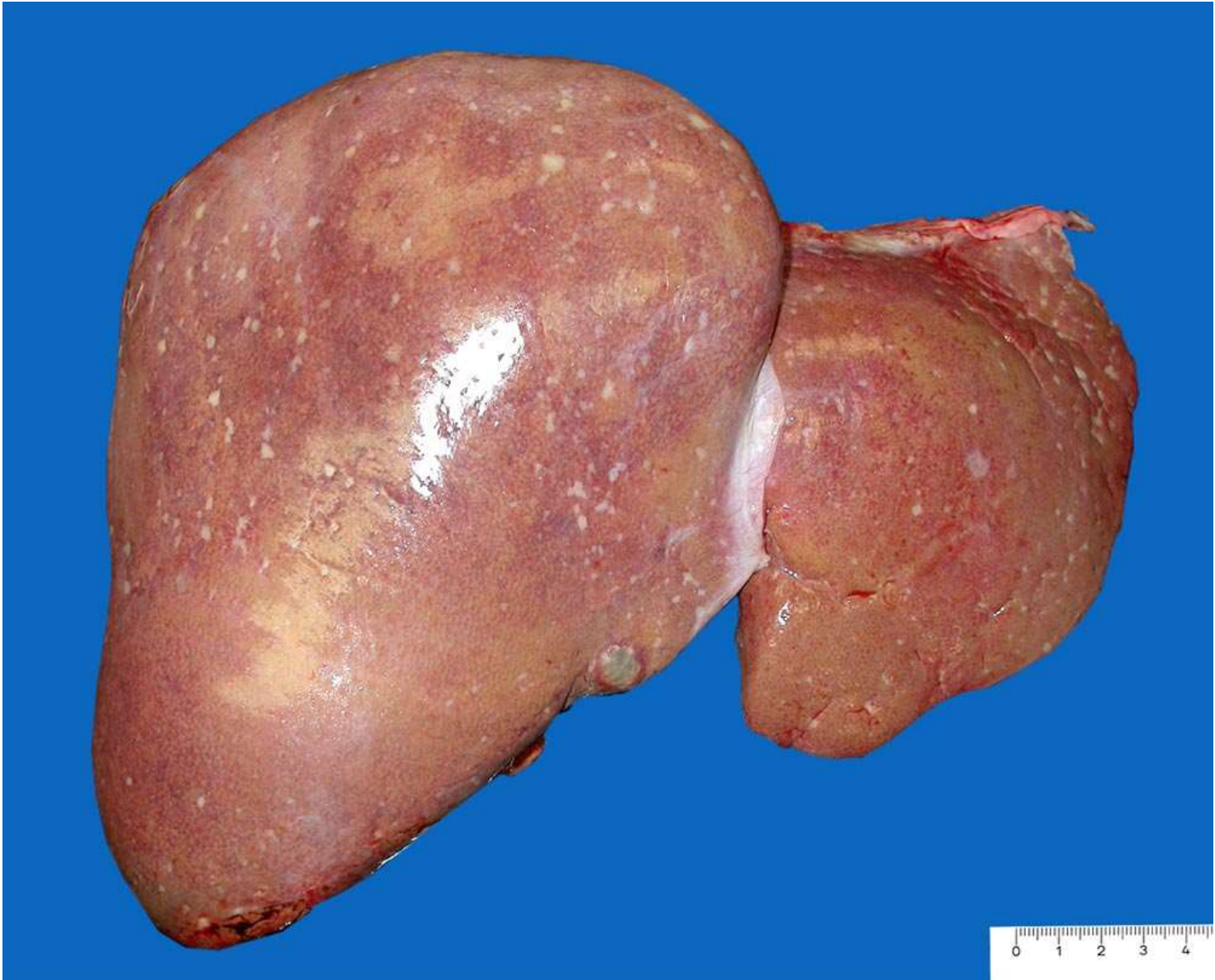
- Also innocent-looking small ductular structures
- DDX based on tumor size, cytological/architectural patterns, invasive features
- Ki-67 index low in BDA (average 2%, never >10%)

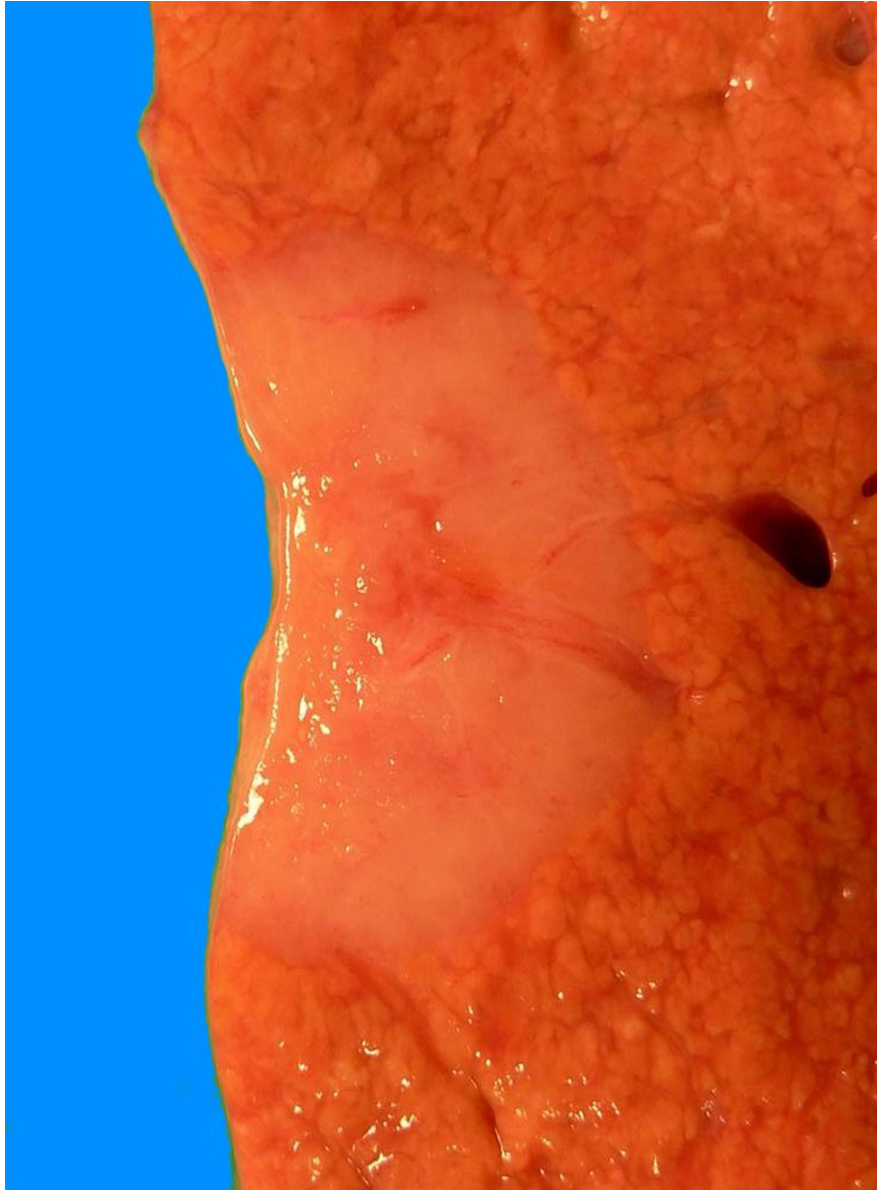
### Von Meyenburg complex (bile duct microhamartoma)

- Usually <0.5 cm
- Related to portal tracts, dense fibrous stroma
- Irregular/rounded cystic ductal structures, flattened/cuboidal epithelium  
Lumina may contain proteinaceous fluid/bile concretions

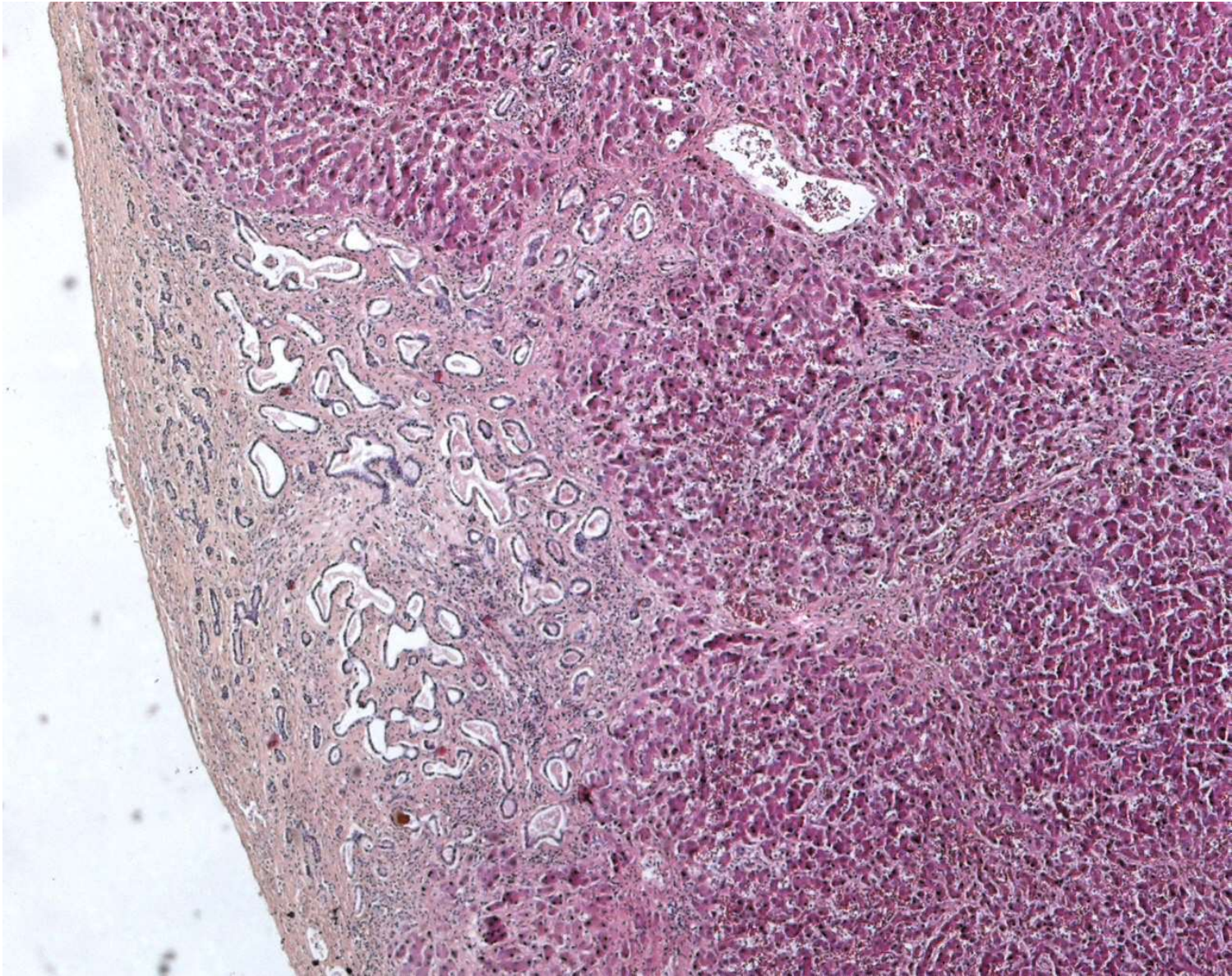
BDA no cystic changes and no bile



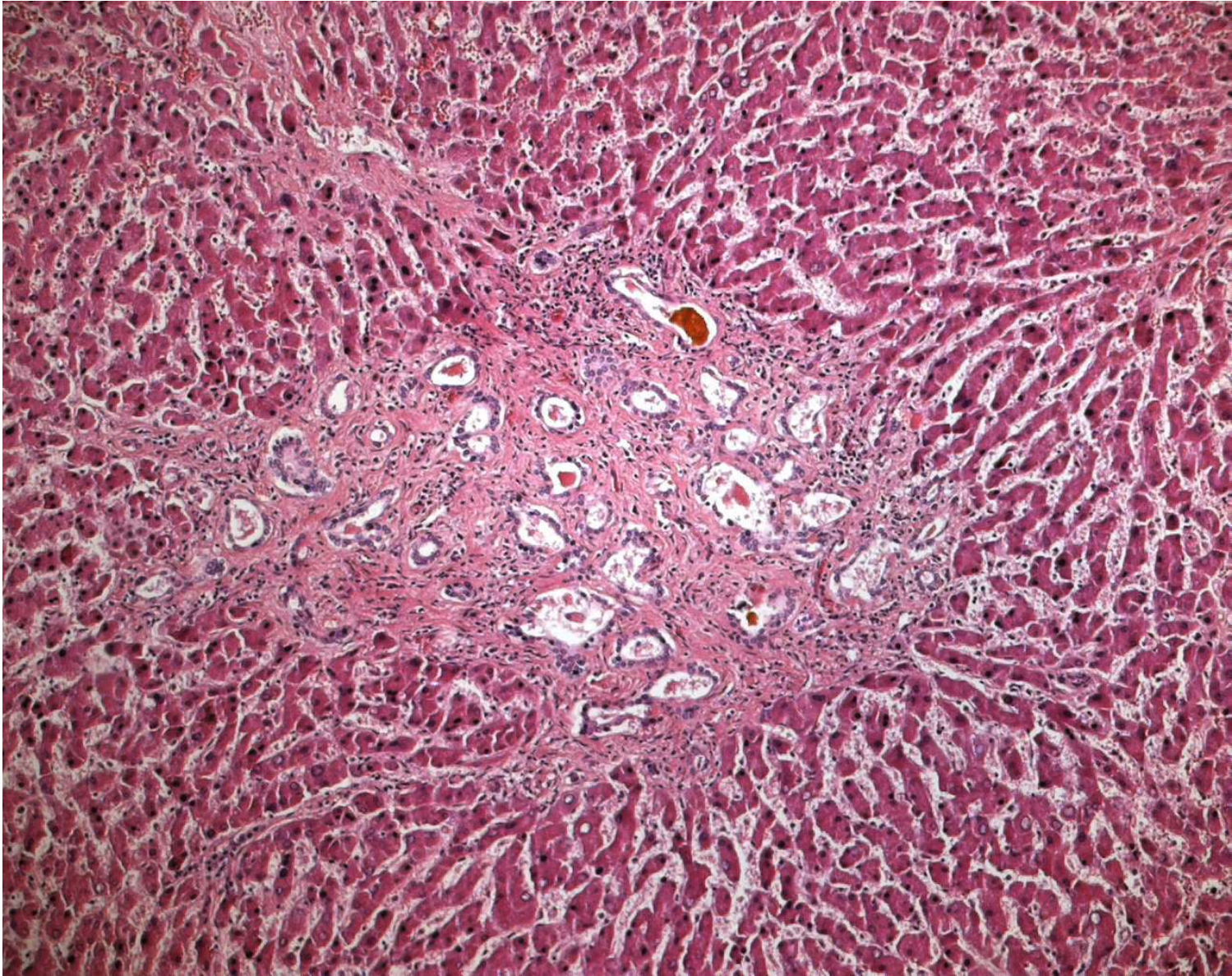














# CONCLUSIONS

## Hepatocellular adenoma

- Accurate assessment of GS staining crucial to identify bHCA with risk of malignant transformation
  - High with exon 3 mutations
  - Low/absent with exon 7/8 mutations

## Focal nodular hyperplasia

- Map-like GS staining

Inconclusive GS pattern: molecular testing can be helpful

## Bile duct adenoma

- Small, f. inclusion portal tracts, absence infiltrative/pushing margin

## HCA/FNH/BDA histopathology crucial in diagnostic process

### **CASE**

External referral for molecular pathology hepatocellular adenoma

Biopsy (FFPE) for DNA NGS in the context of suspected HCA (HNF1A, CTNBB1,.....)

No histology required

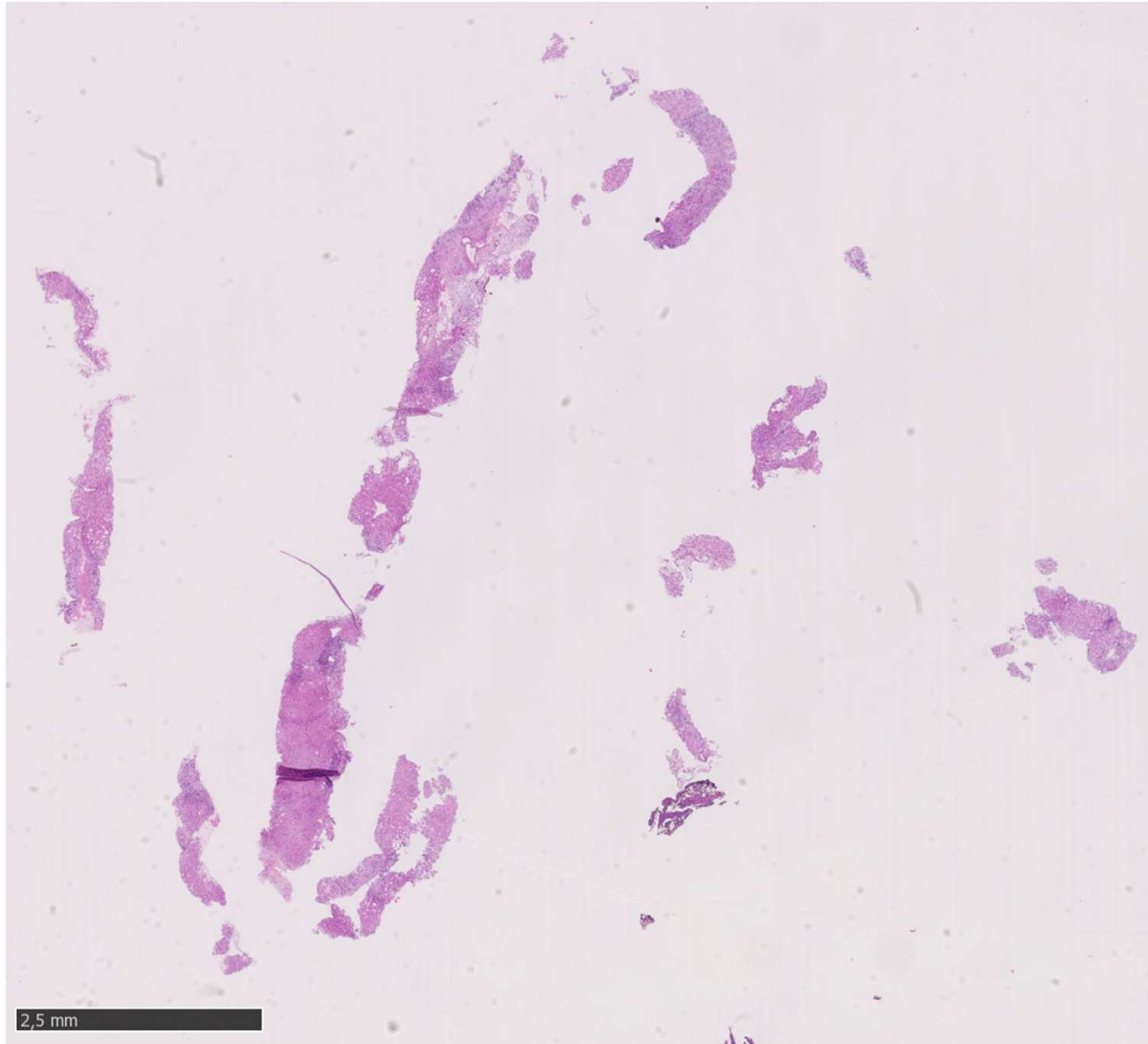
Results NGS analysis

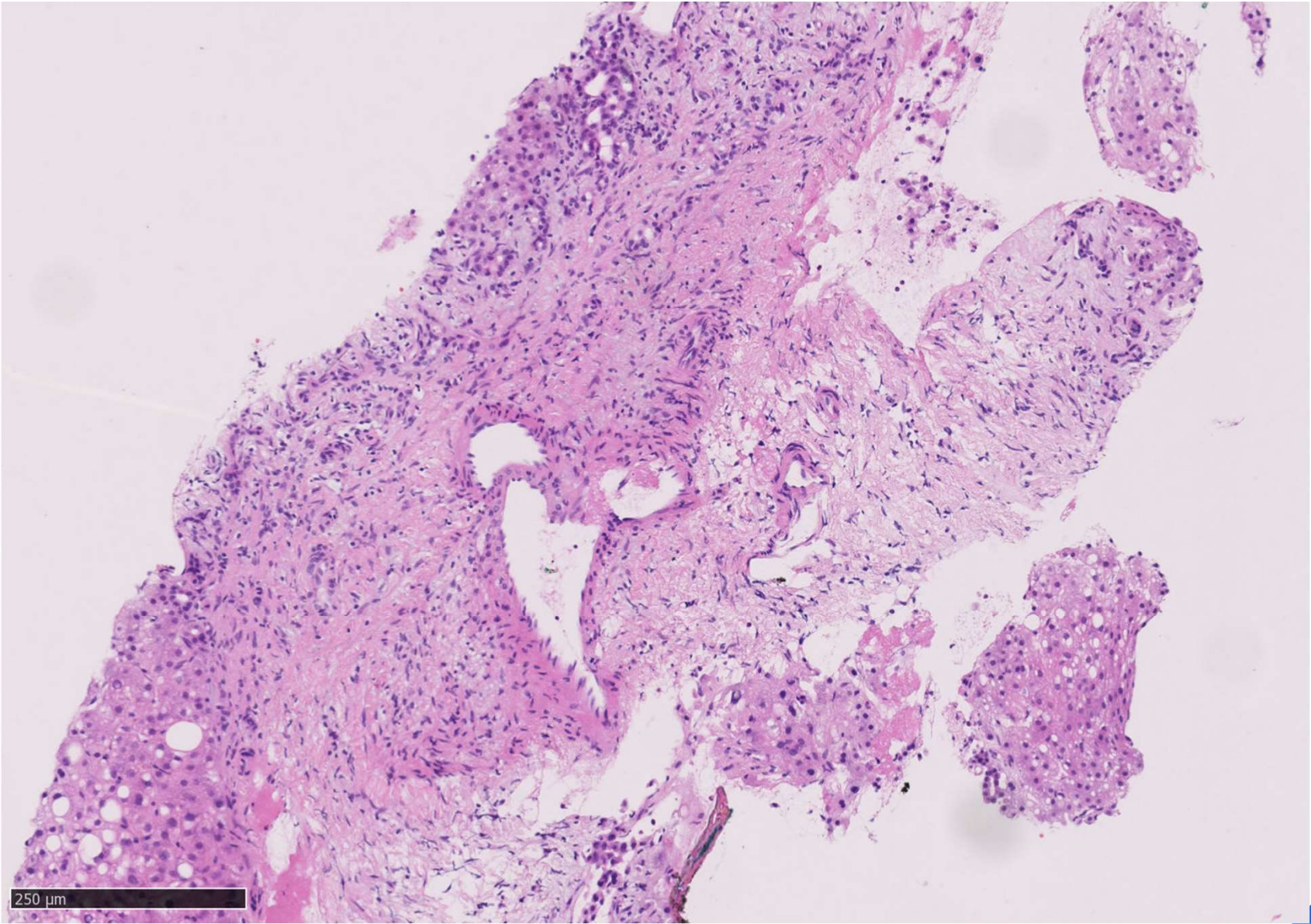
No variants in CTNNB1 (exon 3, 7, 8), TERT promoter, IL6ST, STAT3, FRK, GNAS, JAK1, HNF1A

Low frequency variants could potentially be missed due to too low coverage of some ROIs (coverage <300x)

*Diagnosis* **shHCA? Unclassified HCA? IHCA? FNH? HCC? Other?**



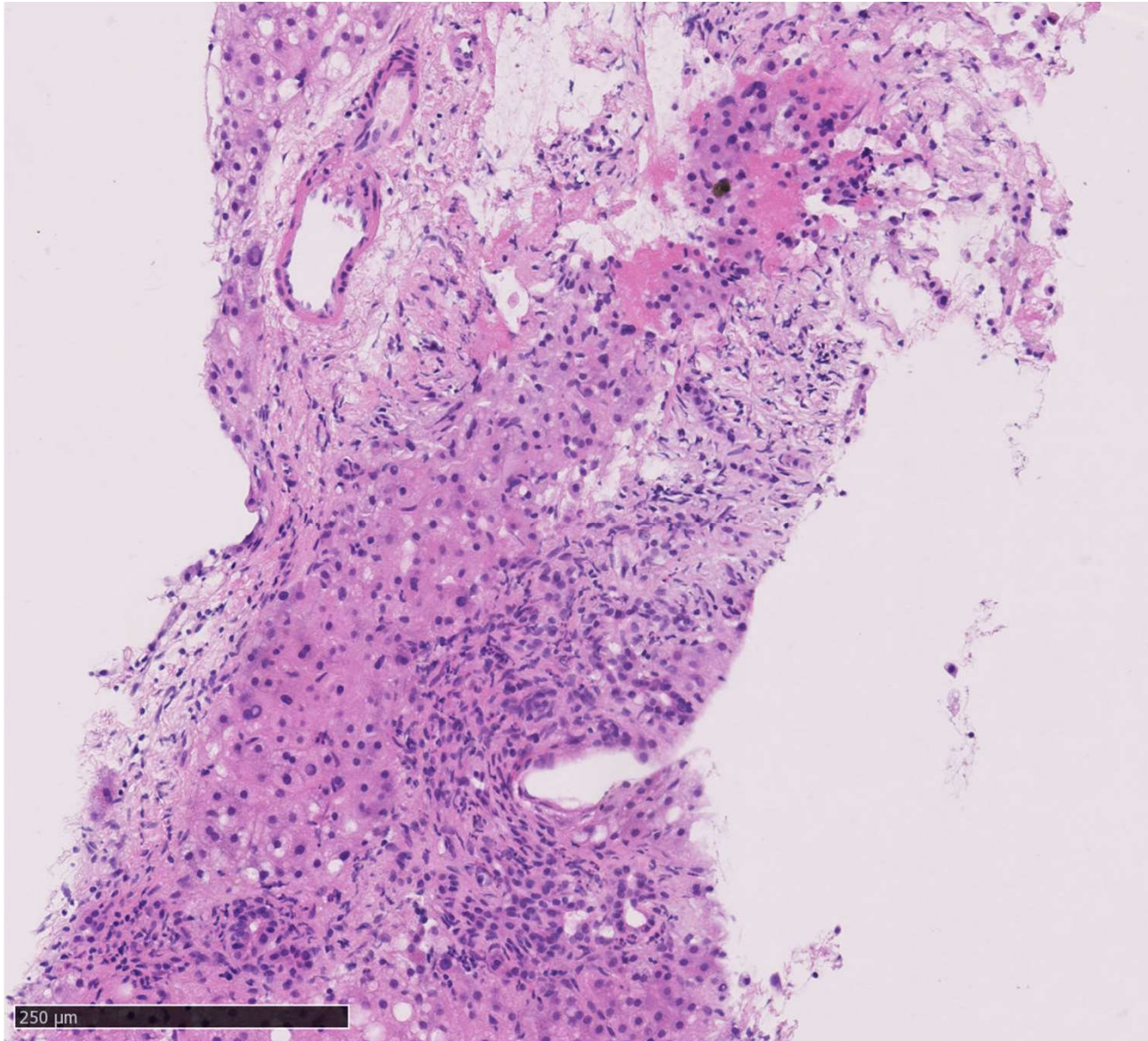


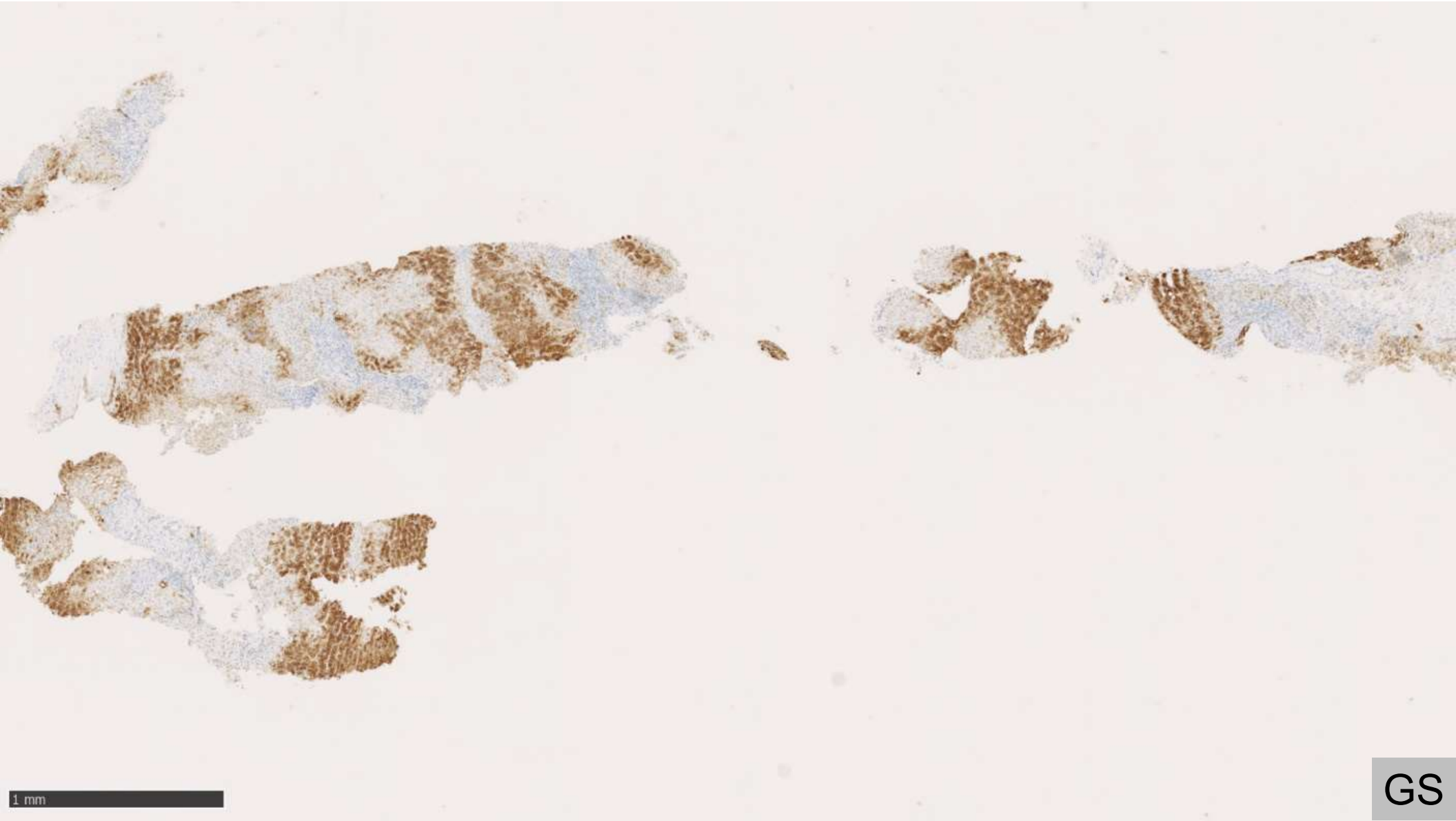


250  $\mu$ m



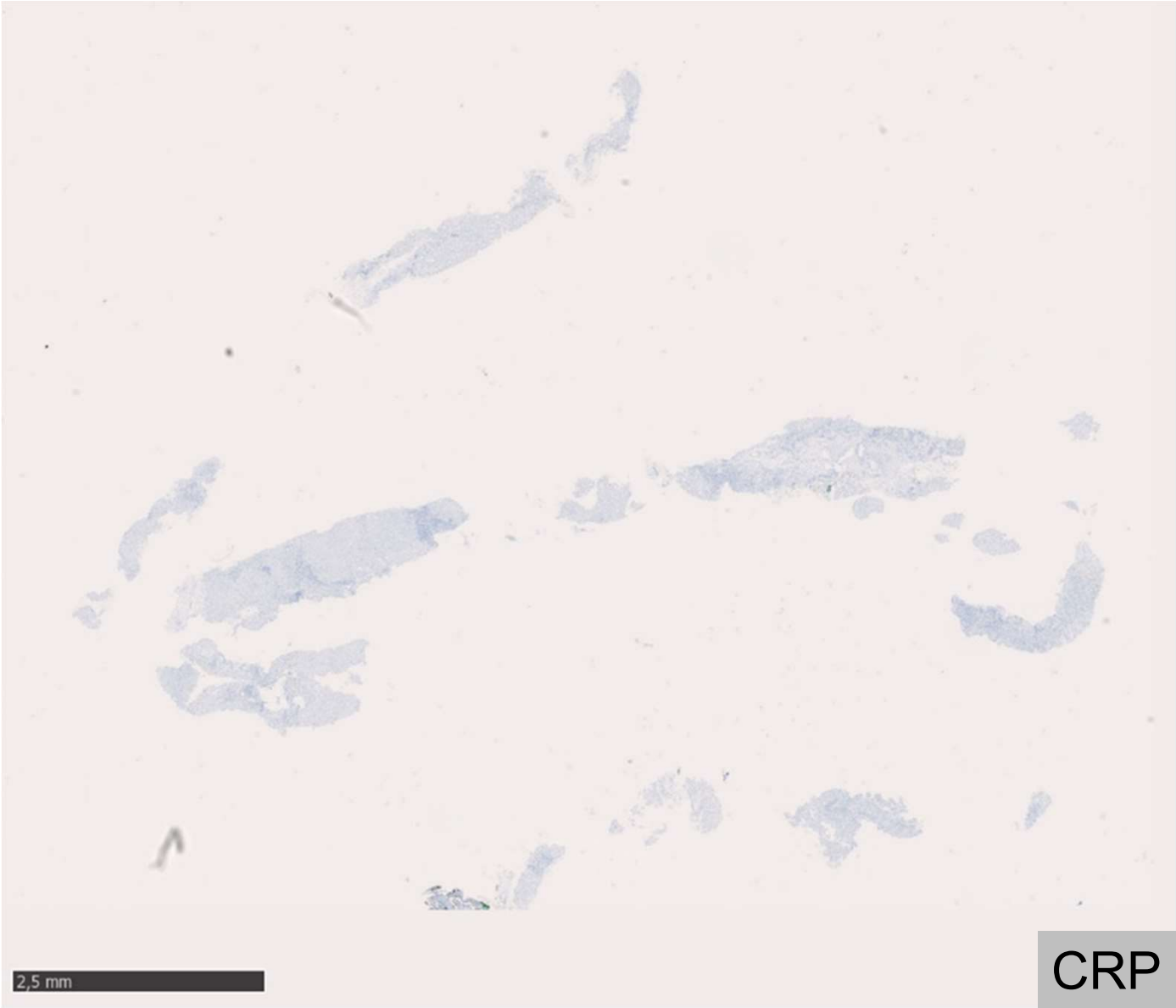





GS





2,5 mm

CRP





Thank you for your attention