Julie Lemahieu
Ine De Wispelaere
Laura Gadeyne
Isabelle Lambert
Marc Haspeslagh
Annemarie Degroote
Karolien Van Den Bossche

Macroscopy of the skin

YPS & BSP MACROSCOPY COURSE 2023

Macroscopy

YPS & BSP MACROSCOPIE 2023

Macroscopy of skin

YPS & BSH MACROSCOPY COURSE 2023

Annular with scaly border

Diagnosis	*Clinical presentation*	*Treatment options*
Tinea corporis	Scaly, annular, erythematous plaques or papules on glabrous skin	Topical and systemic antifungals
Pityriasis rosea	Small, fawn-colored, oval patches with fine scale along the borders, following skin cleavage lines	Topical and systemic corticosteroids; UVA, UVB
Granuloma annulare	Indurated, nonscaly, skin-colored annular plaques and papules, usually on the extremities	Topical and intralesional corticosteroids
Sarcoidosis	Indurated, erythematous plaques	Topical, intralesional and systemic corticosteroids; antimalarials; thalidomide
Hansen's disease	Erythematous annular plaques, with or without scale	Dapsone; rifampin (Rifadin)
Urticaria	Evanescent annular, nonscaly, erythematous plaques	Oral antihistamines
Subacute cutaneous lupus erythematosus	Annular or papulosquamous plaques, with or without scale, on sun-exposed areas	Topical, intralesional and systemic corticosteroids; antimalarials
Erythema annulare centrifugum	Annular patches with trailing scale inside erythematous borders	

Inflammatory skin disease : clinical information=mandatory
Clinical pictures as part of routine method
Requires clinical education of pathologist - requires step up in diagnostic challenge
Relation between dermatologist and pathologist : education of dermatologist by pathologist and trust from dermatologist in dermatopathologist

YPDC-IBSP MACROSCOPY COURSE 2023

Tumoral skin pathology

YPS MACROSCOPY COURSE 2023

HYPSE BSP MICROSCOPE COURSE 2023

Dermoscopy in vivo

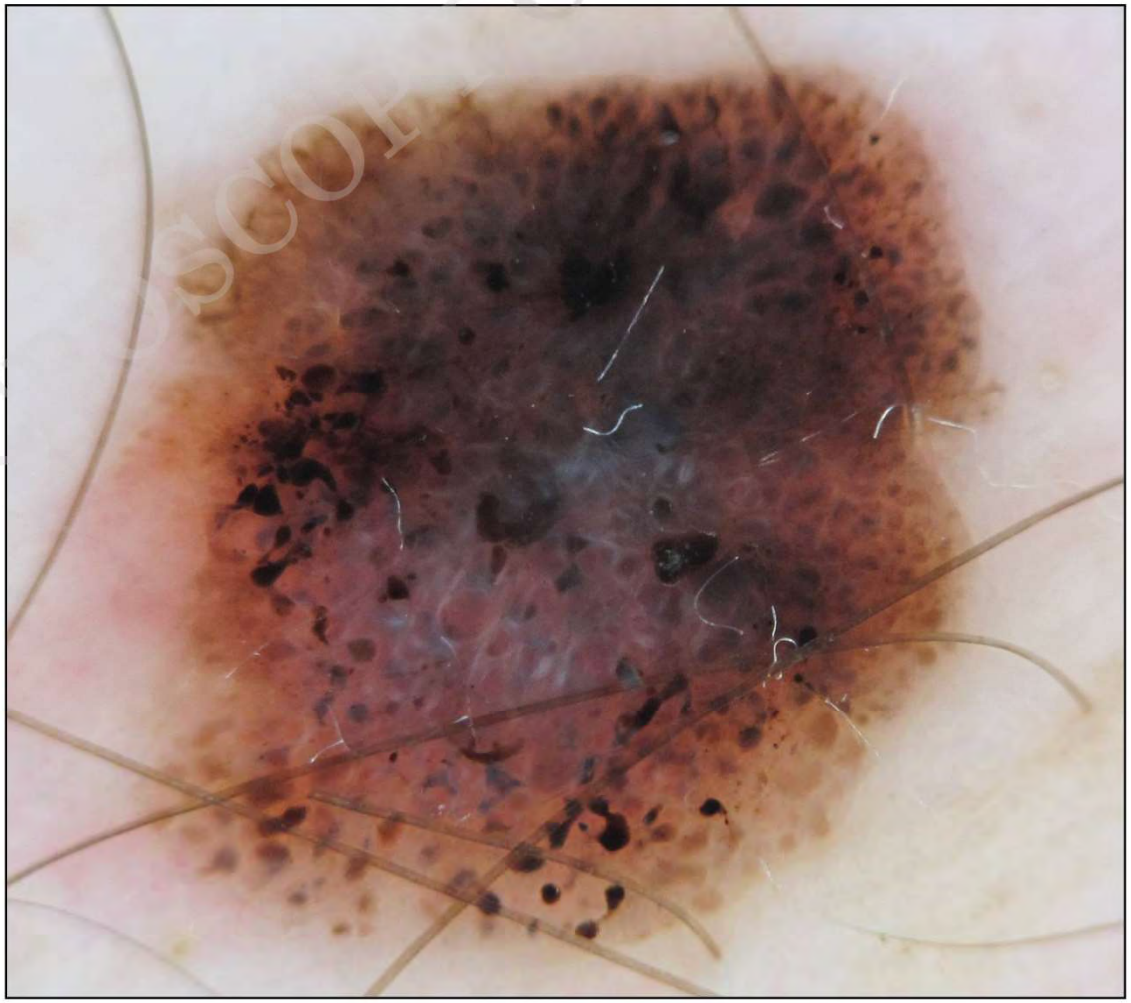

YPS & EDP MACROSCOPIC COURSE 2023

IYPS & BSPM MICROSCOPY COURSE 2023

YPS & BSP MACROSCOPY COURSE 2023

New method?

- Lesion specific and targeted sectioning
- Economically feasible
- Clinicopathologic correlation

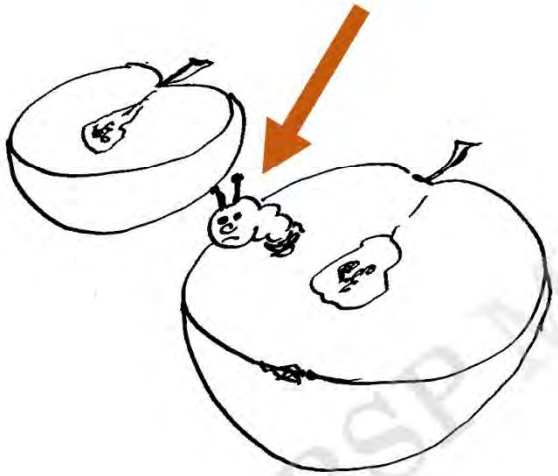

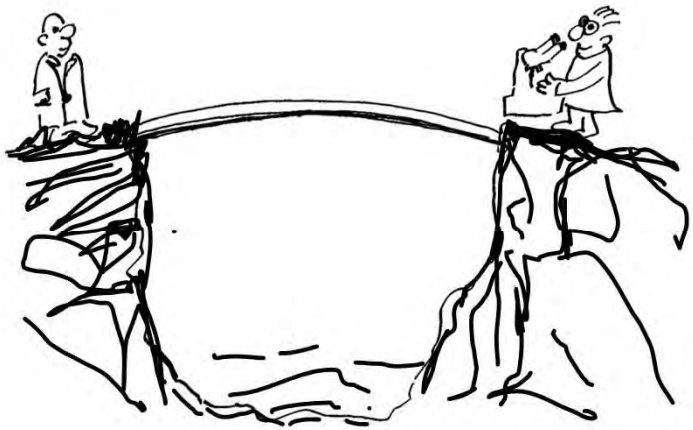

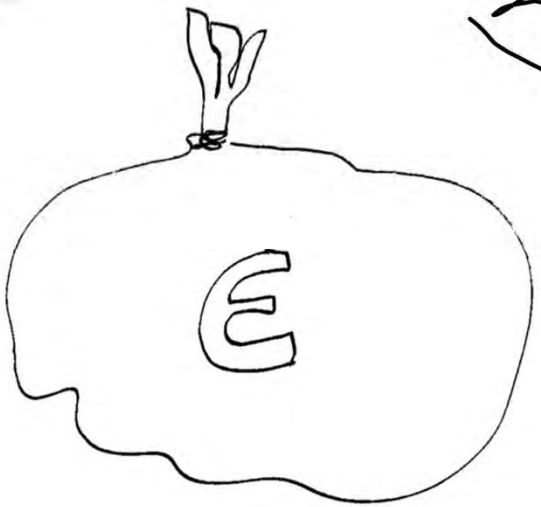

YPS & BSP MACROSCOPY COURSE 2023

Ex vivo dermoscopy

- Arch Dermatol. 2007 Dec;143(12):1548-52.

Ex vivo dermoscopy of melanocytic tumours: time for dermatopathologists to learn dermoscopy.

Scope A1, Busam KJ, Malvehy J, Puig S, McClain SA, Braun RP, Marghoob AA.

- Am J Dermatopathol. 2012 Oct;34(7):710-5.

Ex vivo dermoscopy of cutaneous biopsies For melanocytic neoplasms: a retrospective review of 517 cases with histopathologic correlation.

Amin K1, Fraga GR

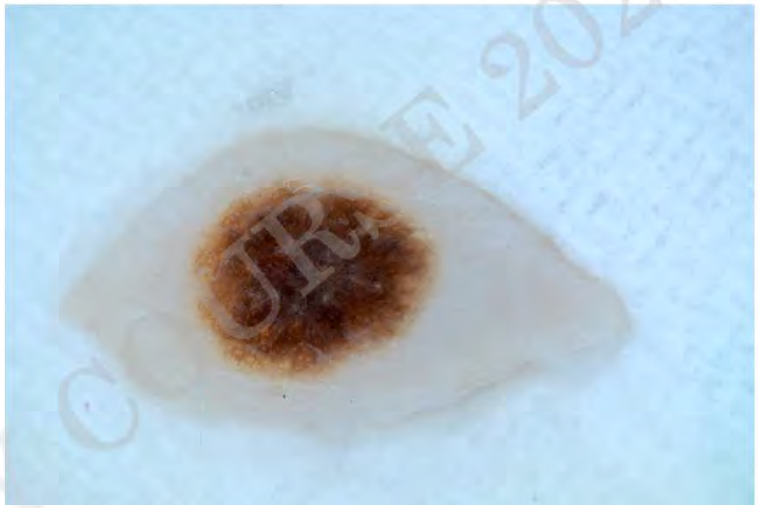

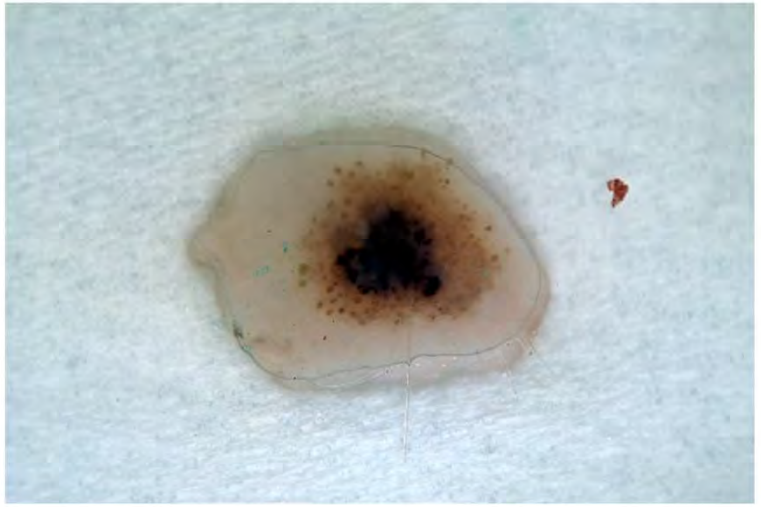

YPS & BSP MACROSCOPY COURSE 2023

2012 routine EX VIVO DERMOSCOPY (EVD)

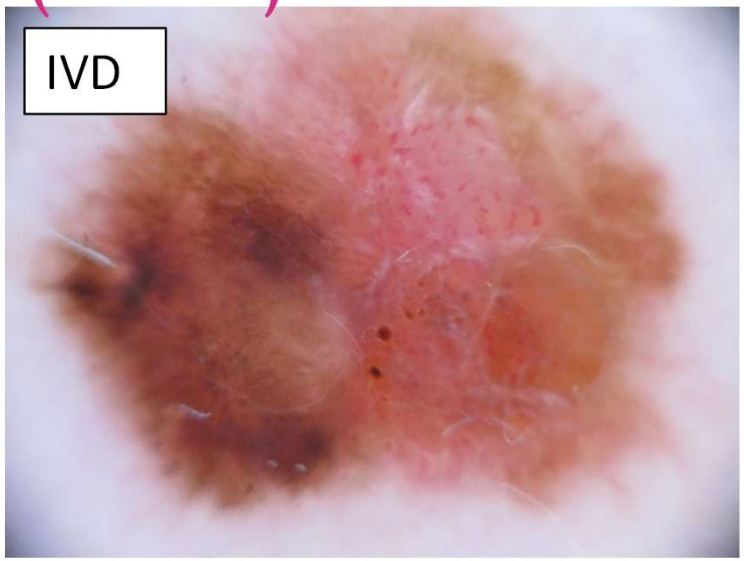

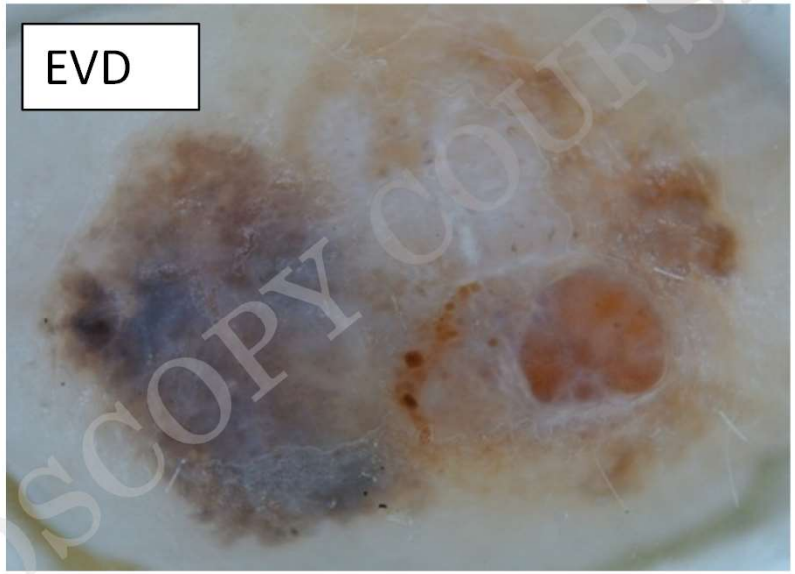

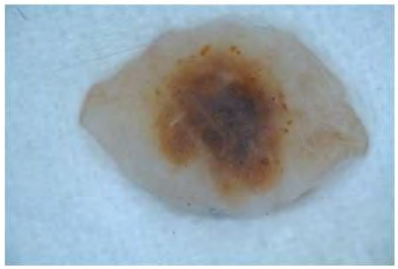

YPS & ESP MACROSCOPY COURSE 2023

Melanoma with ulceration in vivo versus ex vivo

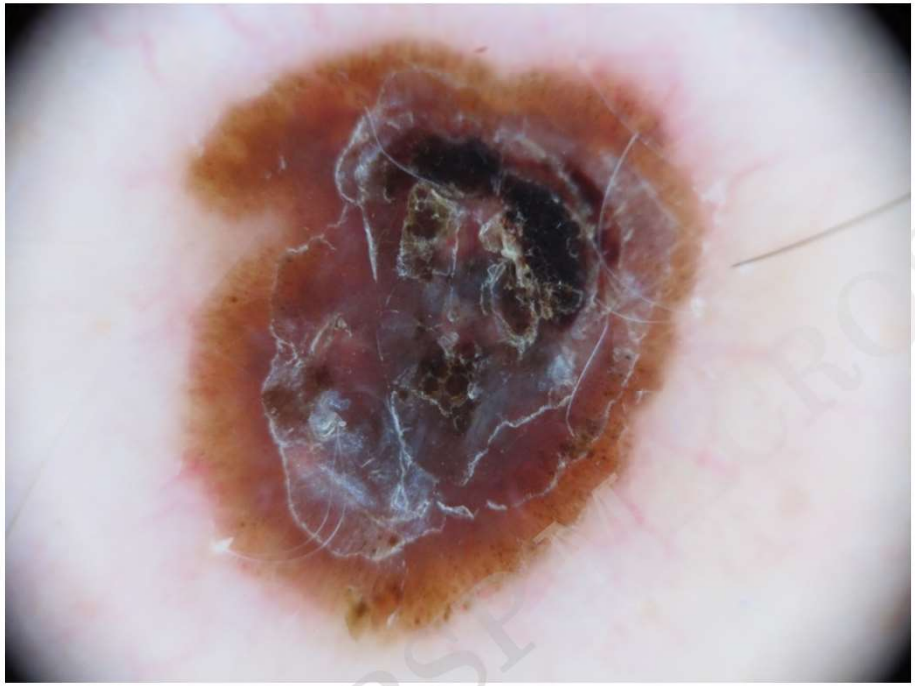

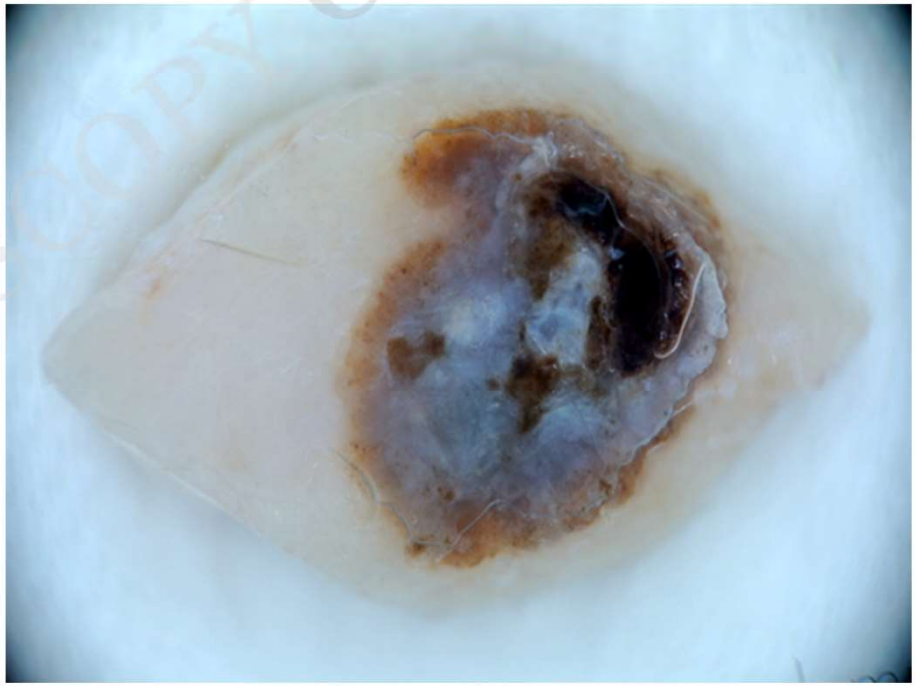

YPS & BSP DERMOSCOPY COURSE 2023

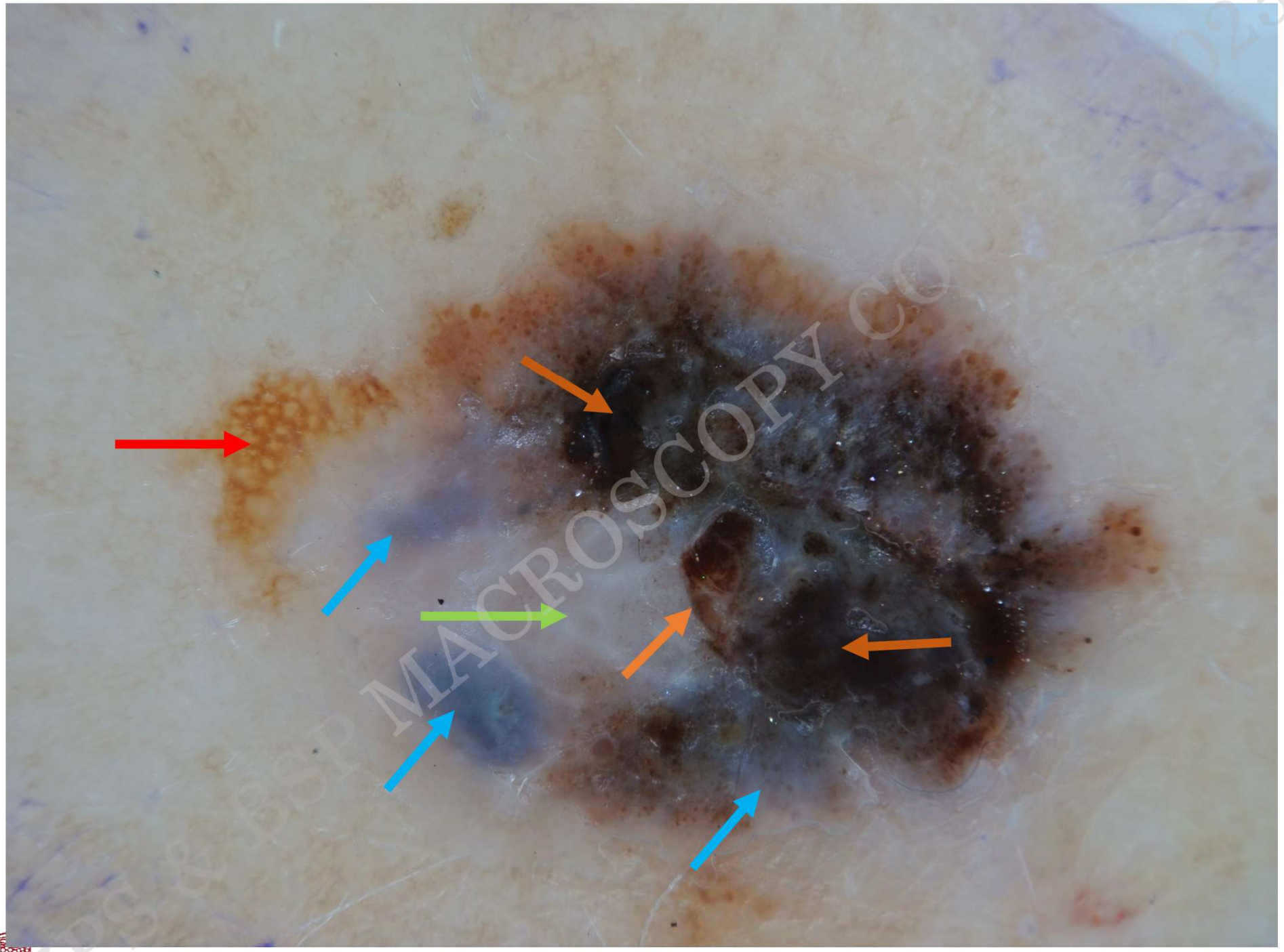
TYPES OF DP MACROSCOPY CC

Focal diagnostic lesions?

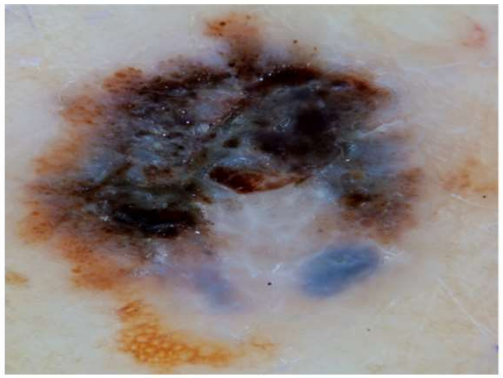

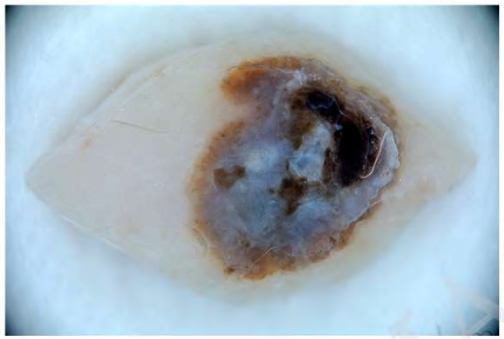

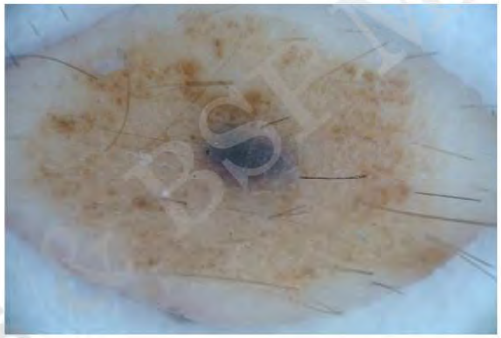



Marking system

YPS - BSI MACROSCOPY COURSE 2023

2311-51965 kuit collisie nevus df?

Targeted slicing

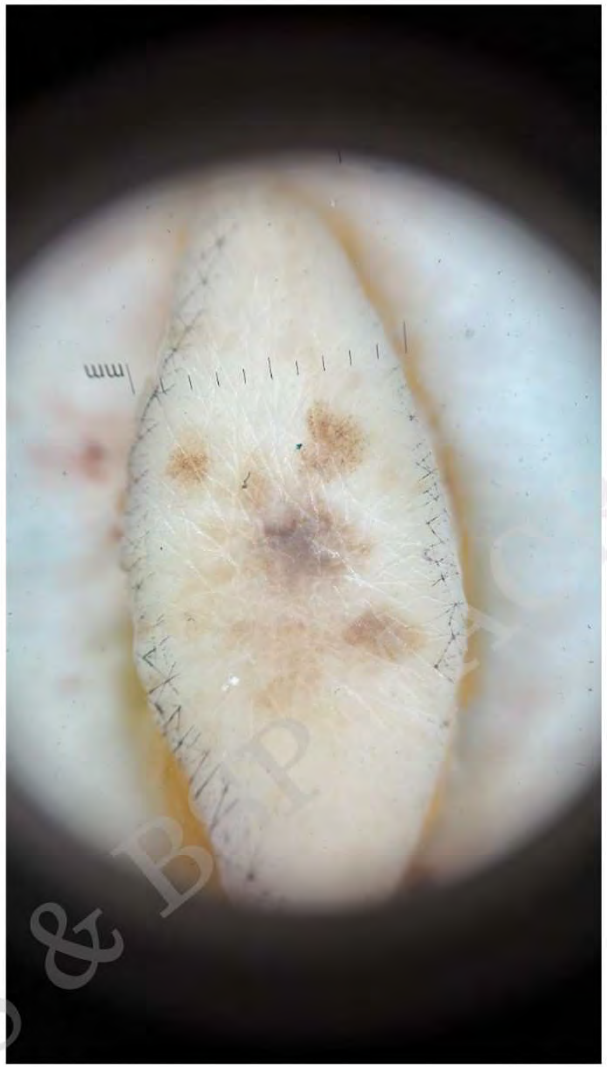

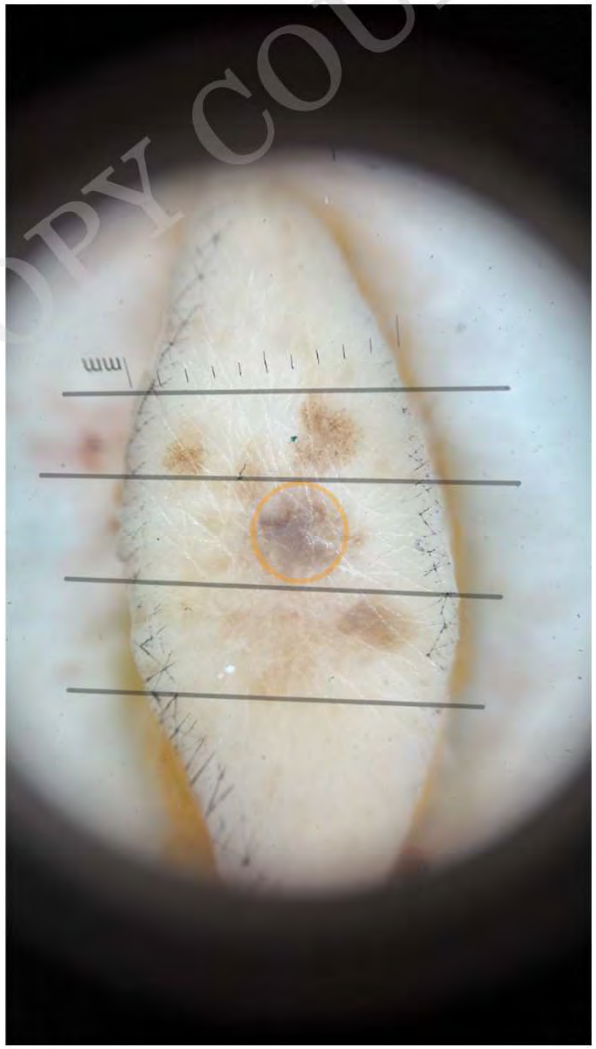

YPS & BP DERMOSCOPY COURSE 2023

EVD-DD

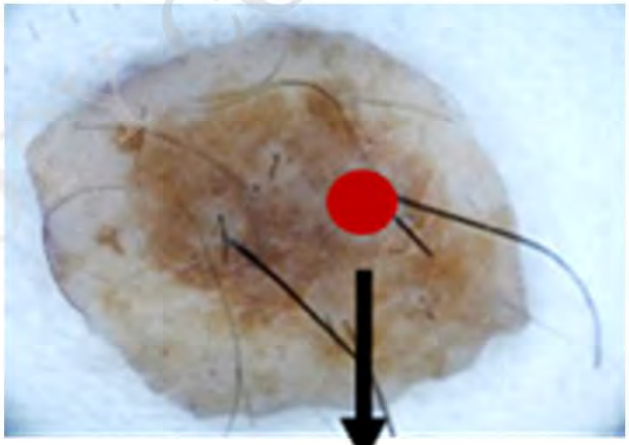

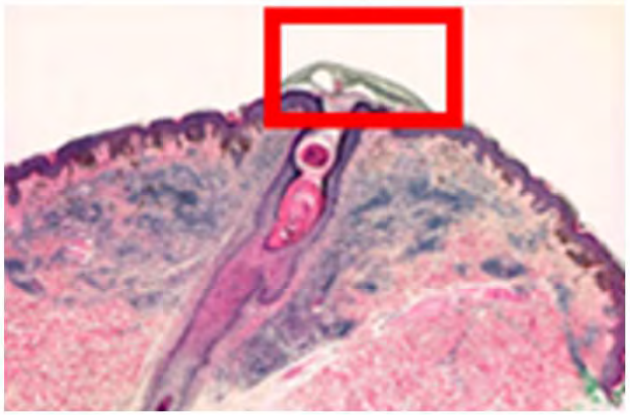

YPS COURSE 2023

Guided Cutting

Standard method

Punch biopsy

Random cuts give no central information, focal lesions may be missed. Block can be exhausted for eventual additional stains.

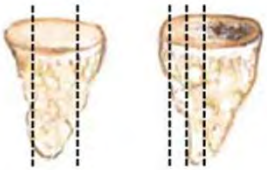

Shaving / curettage

Random longitudinal or transverse sections at three levels result in representative slides of the lesion.

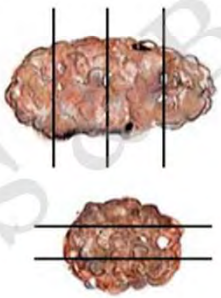

EVD with DD

Punch biopsy

Three depths with marked central section and residual tissue for deeper sections. Marked section of focal lesions.

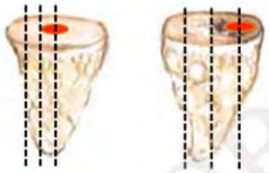

Shaving / curettage

Random longitudinal or transverse sections at three levels result in representative slides of the lesions.

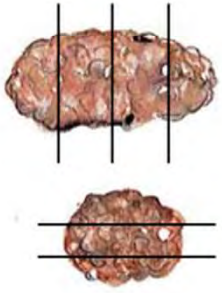

Naevi

Blind transverse bread-loaf sections with processing of tips results in many slides without lesional tissue.

Small, focal lesions can be transected and risk to get lost in slides.

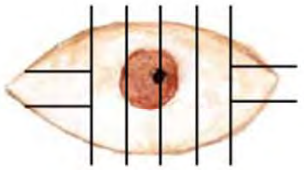

Oriented sectioning without processing tips results in slides with only lesional tissue.



Focal lesion is dotted and traced in the slide.



YPS ©BSP MACROSCOPY COURSE 2023

Deeper sections first block

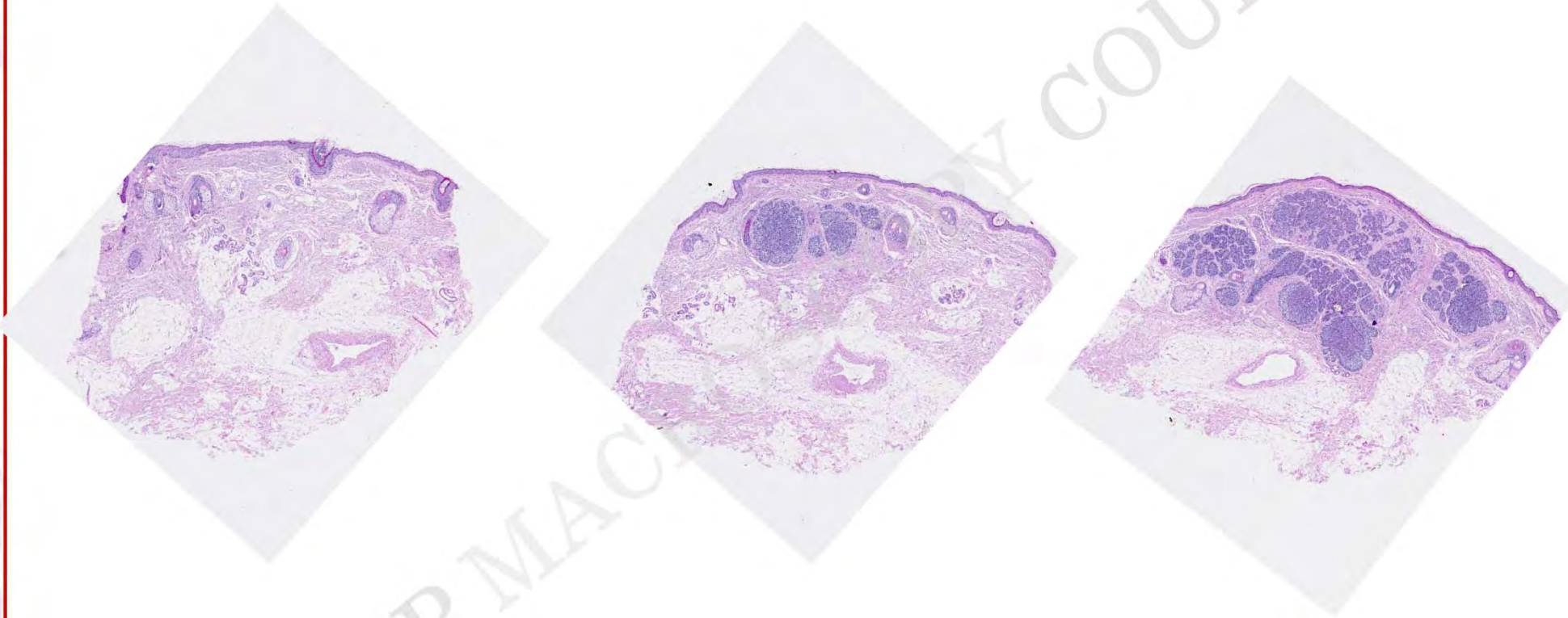

1st depth

2nd depth

3rd depth

Continuous improvement – training – feedback!

YPS & BSP MACHINE LEARNING COURSE 2023

1

2

3

YPS & BSP MICROBIOLOGY 2023

Heterogeneity

- Heterogeneity within a biopsy: collision of lesions
  - Incidental benign collision of lesions
  - Collision with diagnostic importance
- Heterogeneity within a lesion:
  - Explanatory of dermoscopic image and excision of lesion leading to diagnostic assurance
  - Prognostic for diagnosis
    → identification of progression in atypical naevi and (naevus-associated) melanoma
  - Reflected in detection of molecular heterogeneity
    → identification of melanocytomas

YPS & BCN DERMOSCOPY COURSE 2023

2311-51871

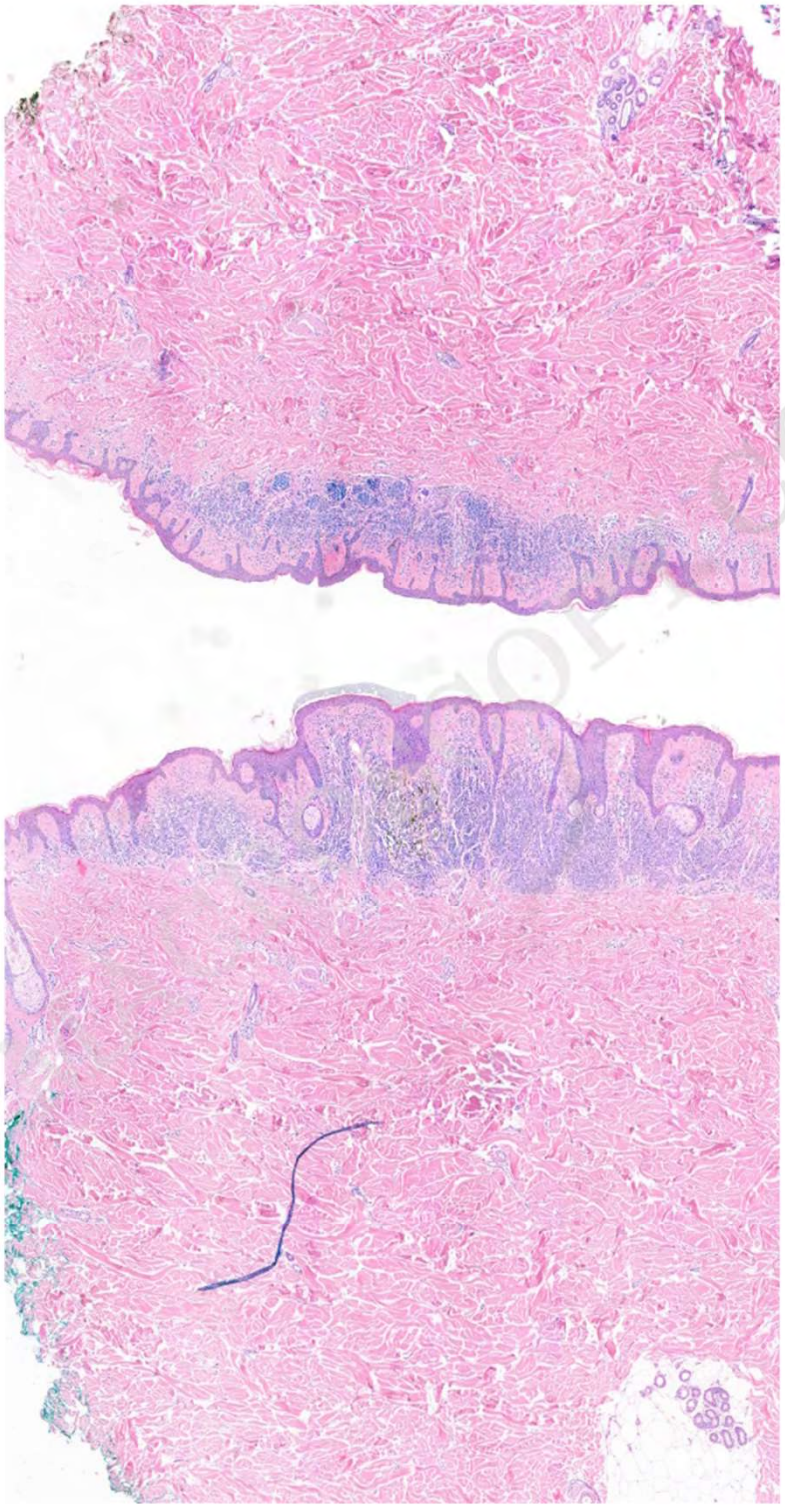

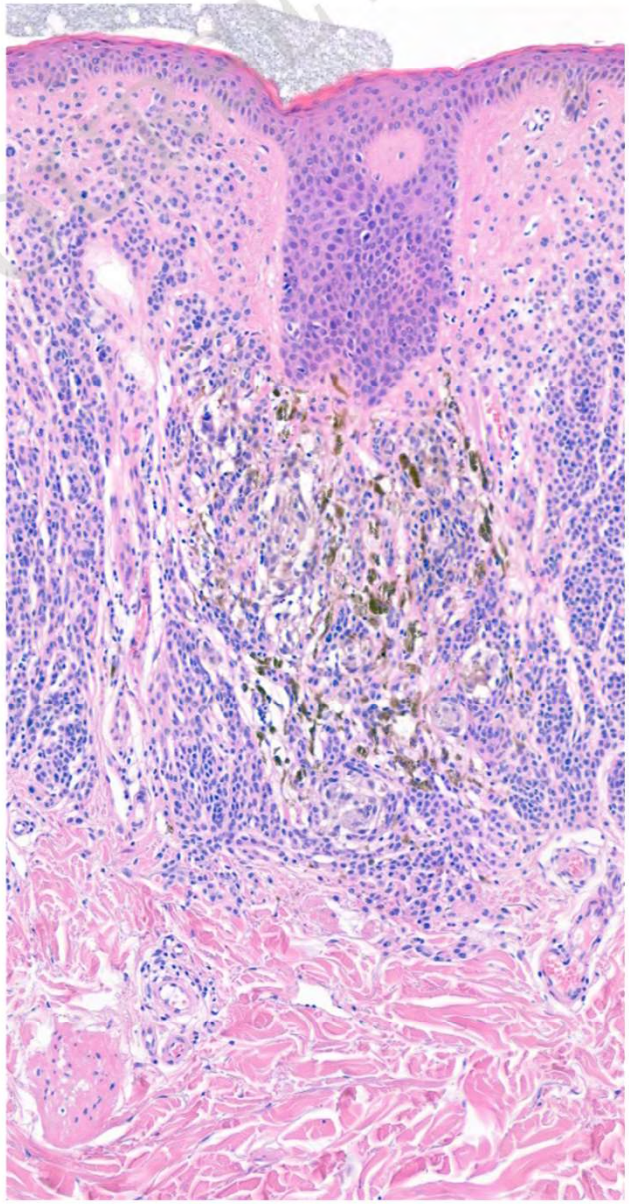

YPS & BSP 2023

2011 → 2023

Haspeslagh M, Degryse N, De Wispelaere I. Routine use of ex vivo dermoscopy with "derm dotting" in dermatopathology. *Am J Dermatopathol.* 2013;35(8):867–869.

EVD-DD 2.0

=

PL-EVD-DD-GC-IP

Paperless - Ex-vivo-Dermoscopy - Derm-dotting - Guided cutting - Incl. prioritisation

YPS & BSP MACROSCOPY COURSE 2023

PL: Digital registration of grossing data

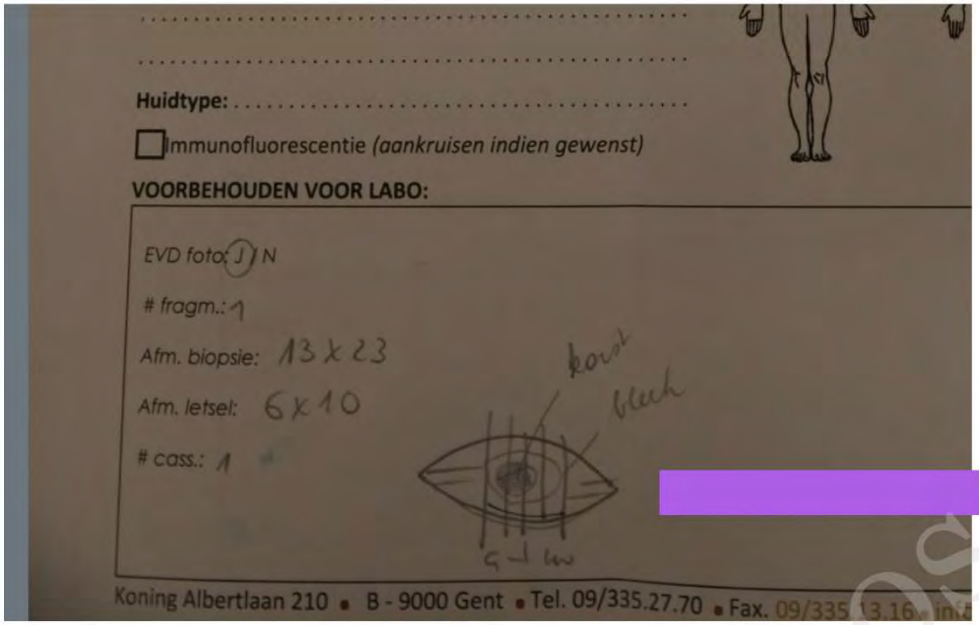

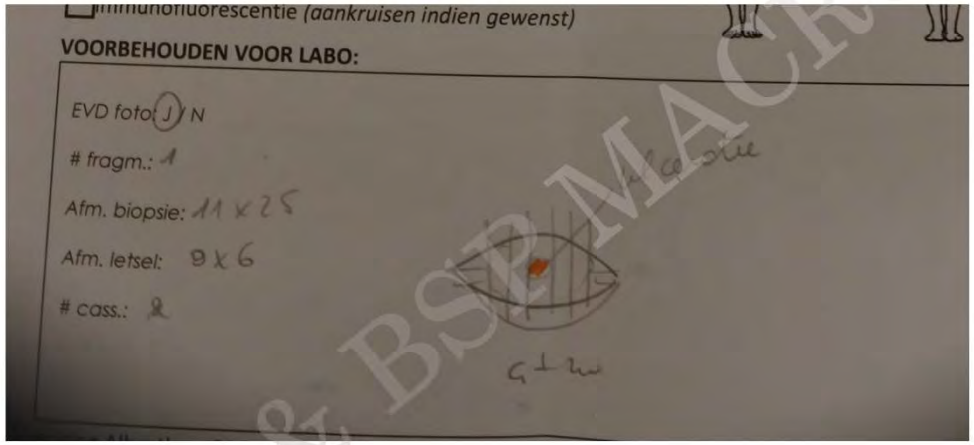

YPS & BSP MACROSCOPY COURSE 2023

PL: digital annotations on EVD picture

MACROSCOPY COURSE 2023

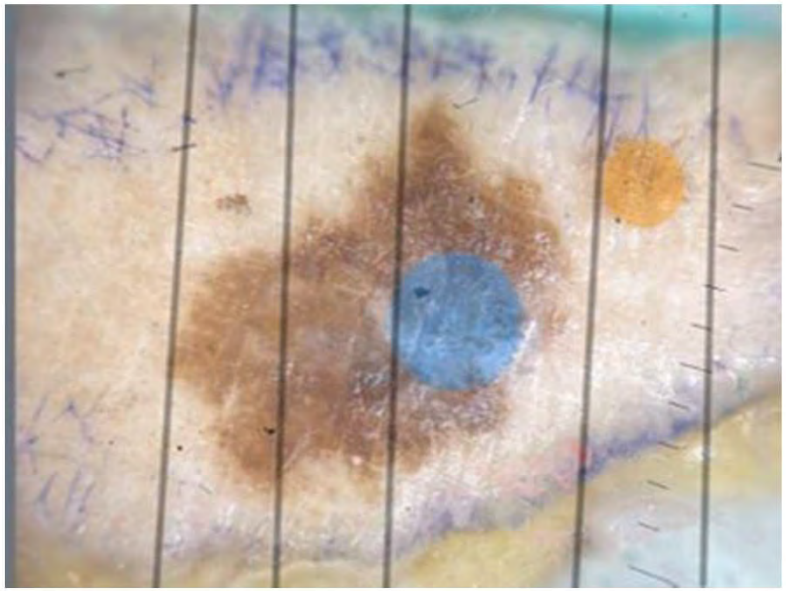



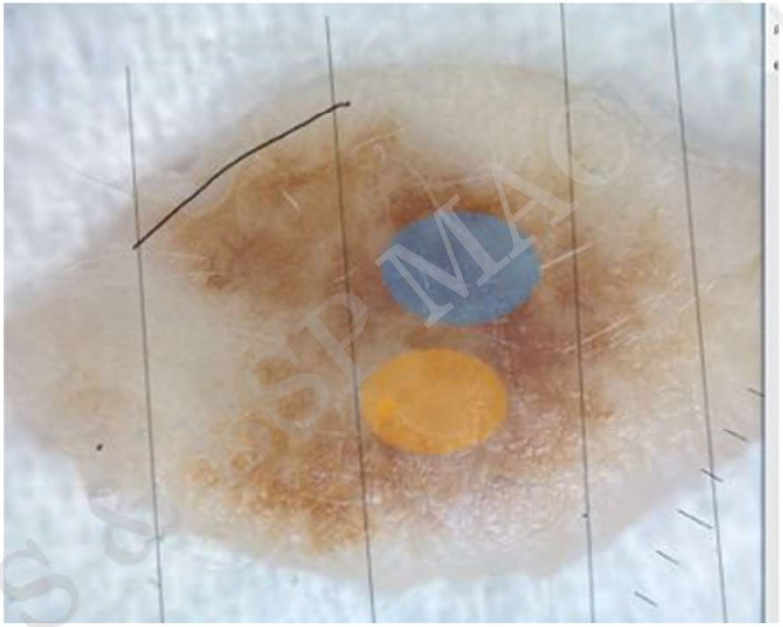



YPS & ISP MAC OSCOPY COURSE 2023

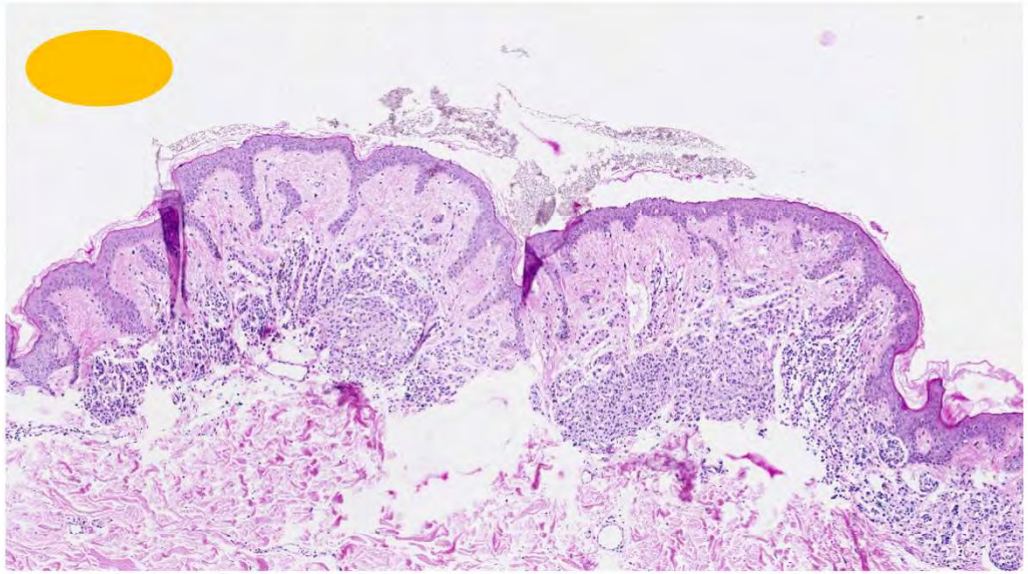

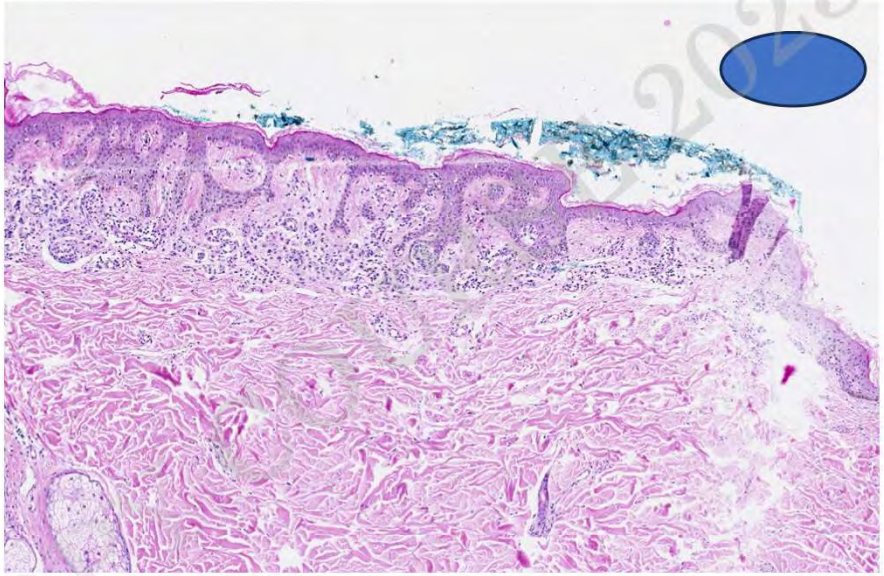

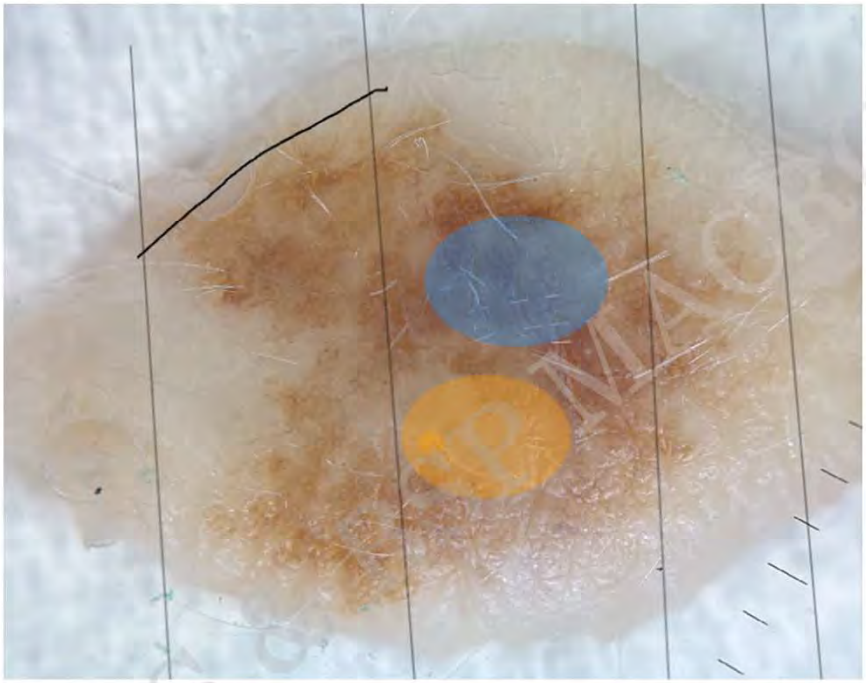

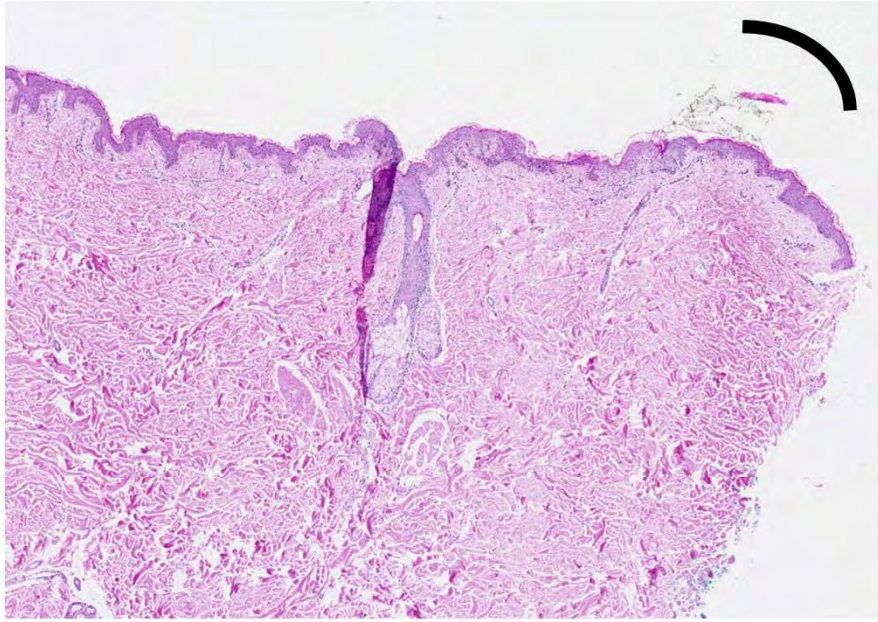

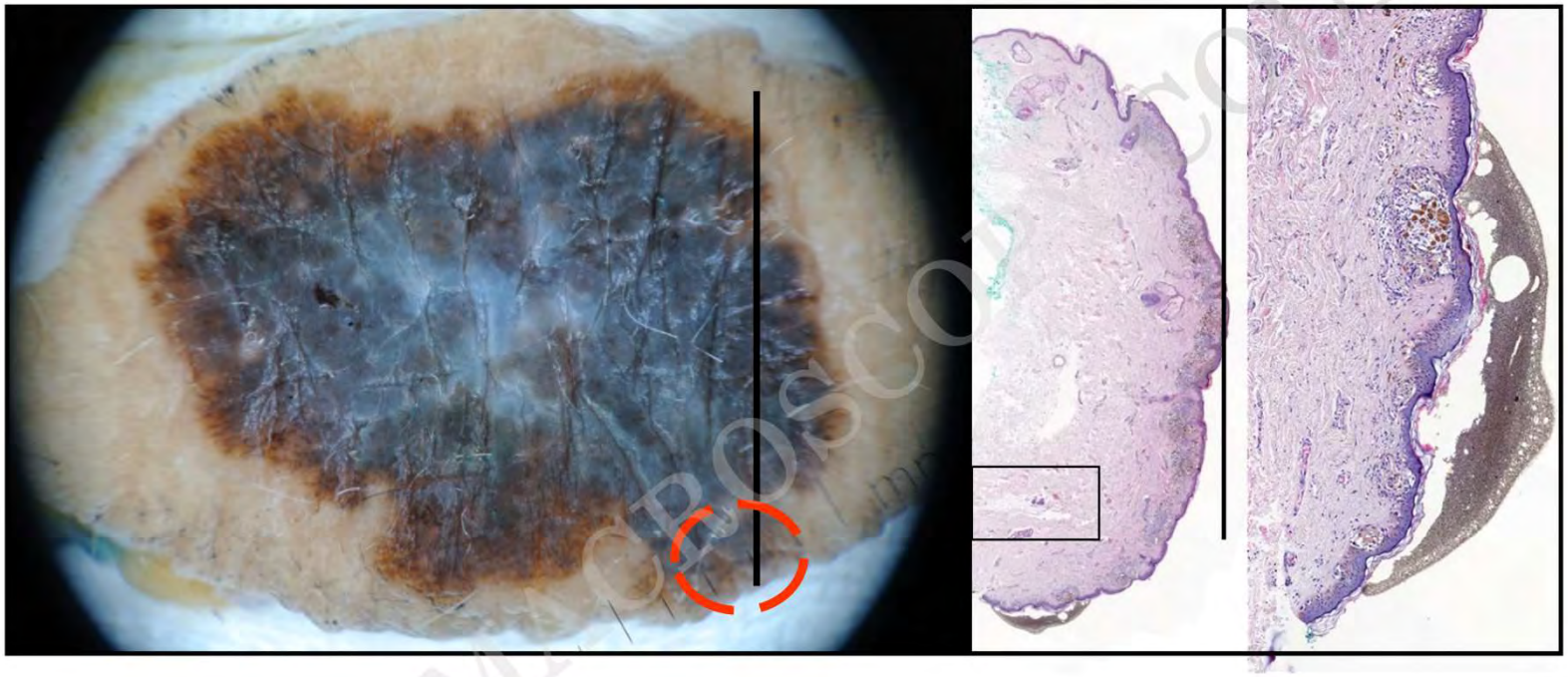

YPS & BSP MICROSCOPY COURSE 2023

hermes-consult / start / vorig / aanvraag behandelen

Locatie: re onder kaaklijn

Klinische inlichtingen: zeer opvallend pikzwart pigmentletseltje met dermoscopisch starburst patroon

DIF

EVD

Afmetingen

Online aanvraag/stalen

Nota MLT: ink spot lentigo? graag FB (mail aub)

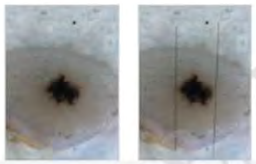

YPS & BSP MACROSCOPY COURSE 2023

2311-51350

Naked eye

Ex vivo

YPS & BSP MACROSCOPY COURSE 2023

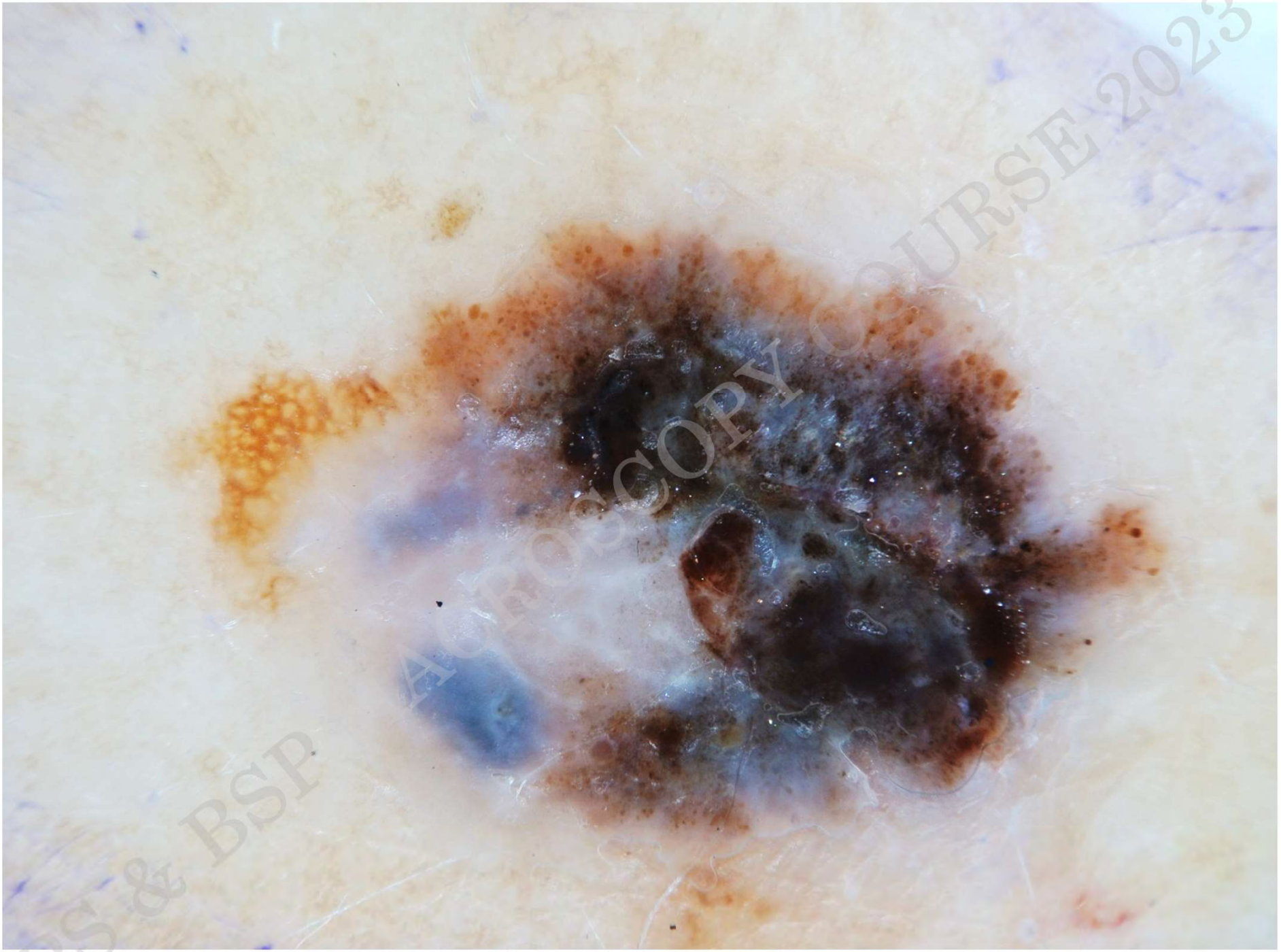

YPS & BSP DERMOSCOPY COURSE 2023

Structures

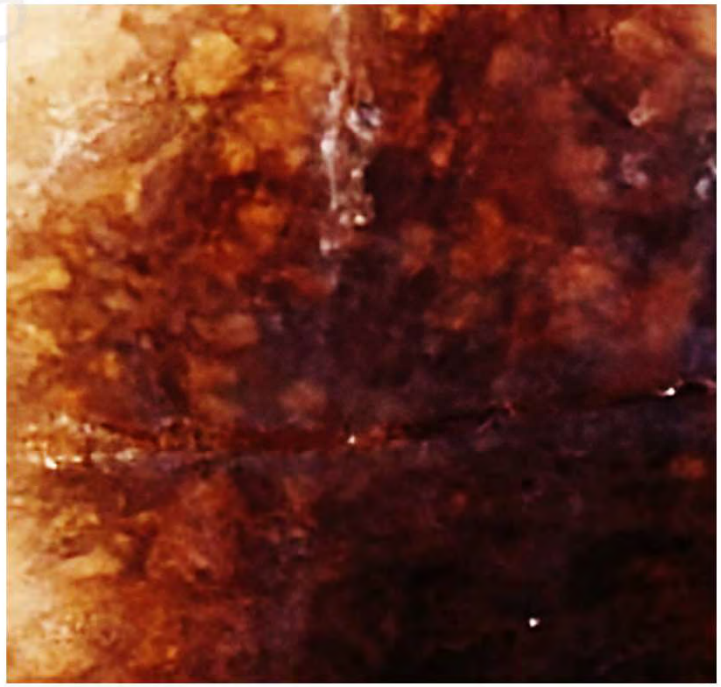

CYPRUS BSD MACROSCOPY COURSE 2023

Diffuse reticular

Patchy reticular

Peripheral reticular with central hypopigmentation



Peripheral reticular with central hyperpigmentation

Homogeneous

Peripheral globules/starburst

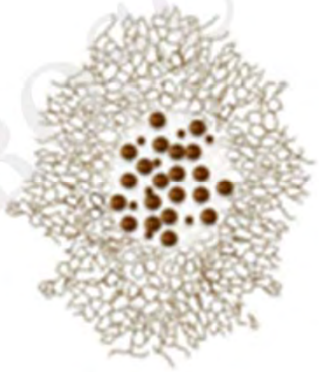

Peripheral reticular with central globules

Globular



Two components

YPS & BSP MICROSCOPY COURSE 2023

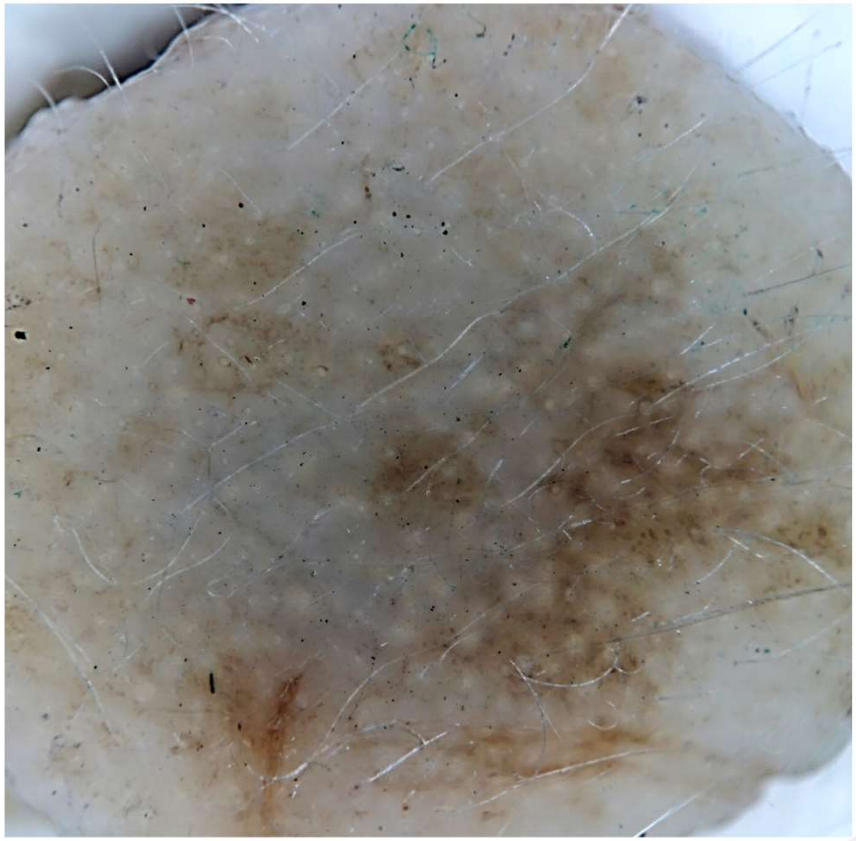

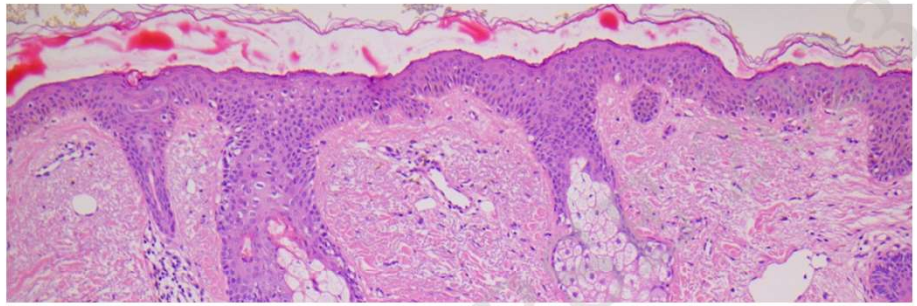

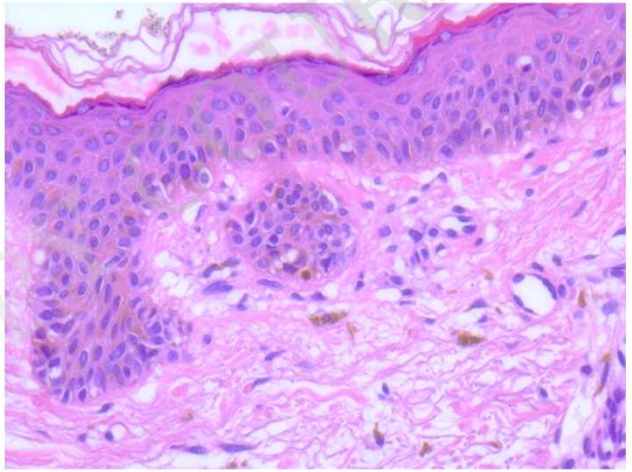

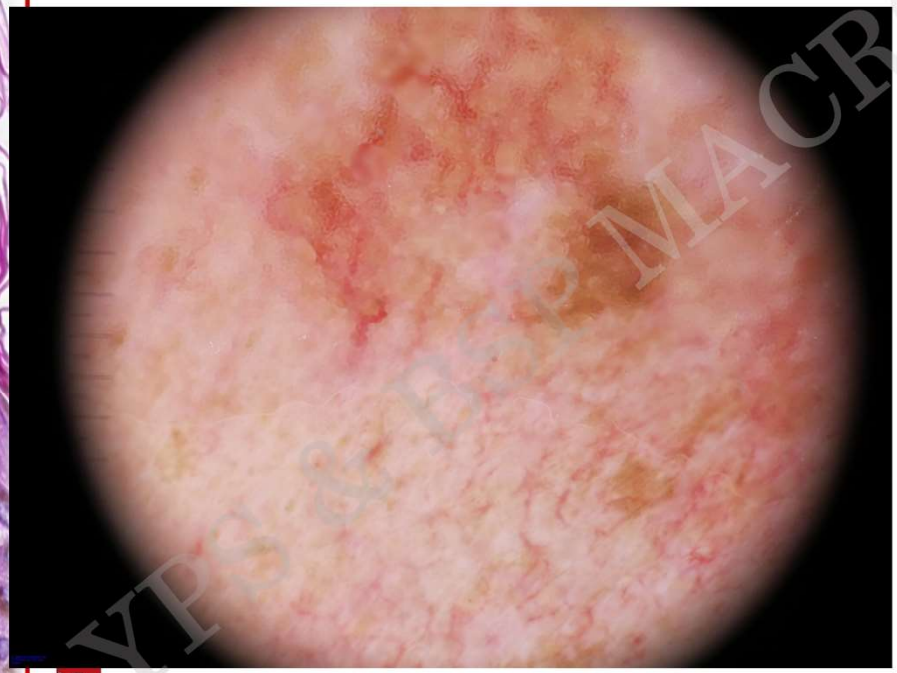

pseudonetwork



YPS & DP MACROSCOPIC

Lentigo maligna

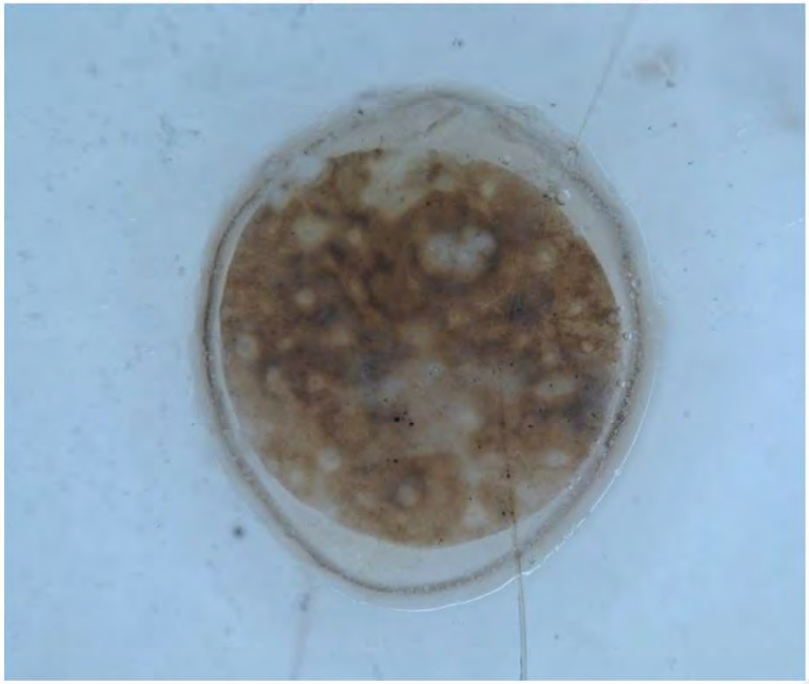



F

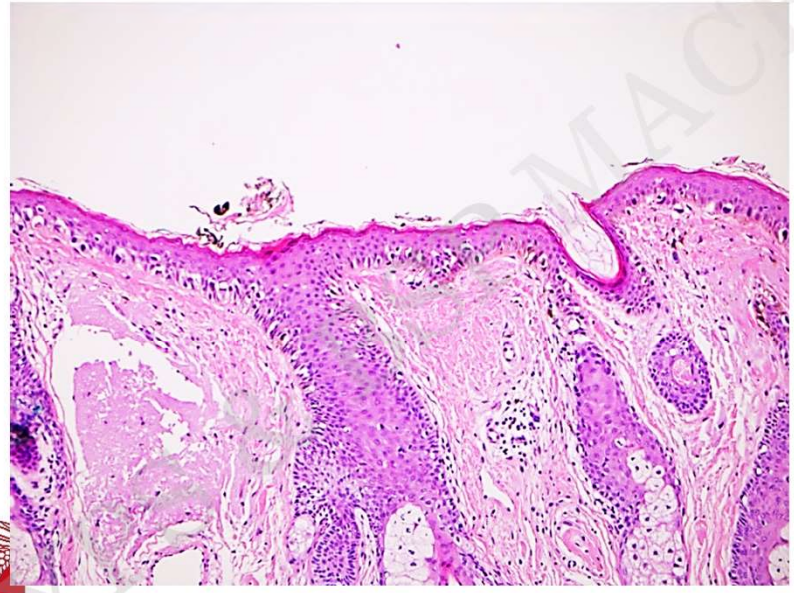

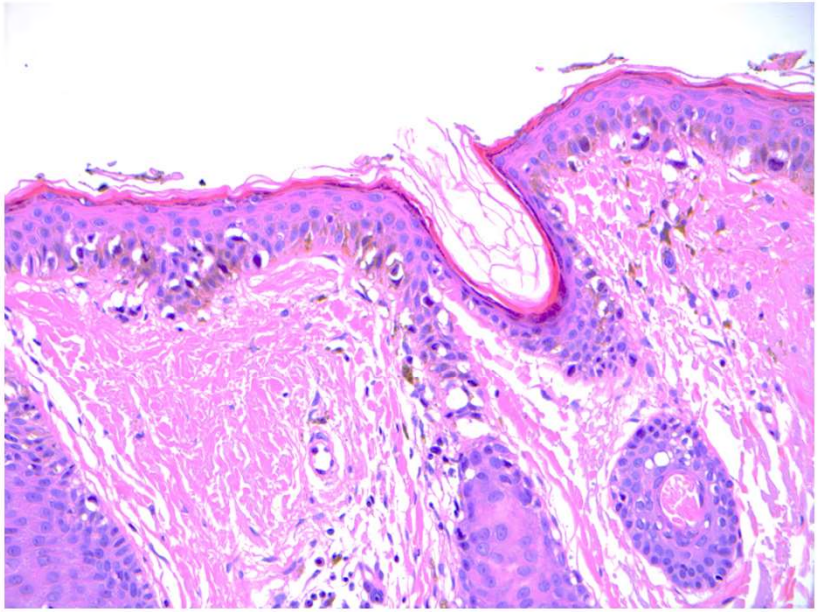

MACROSCOPY COURSE 2023

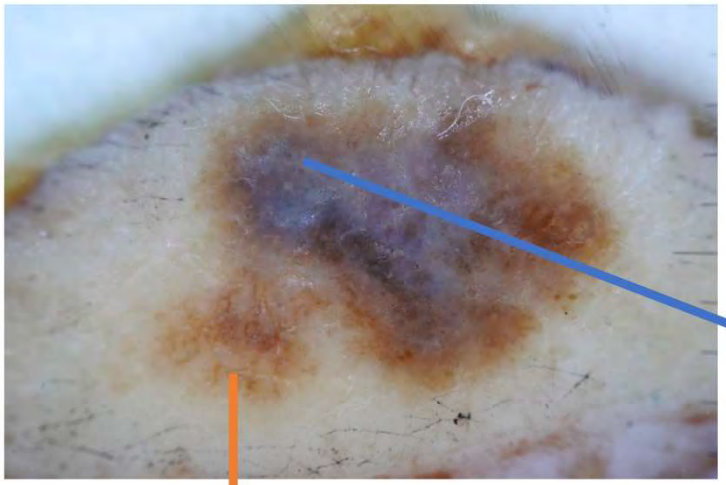

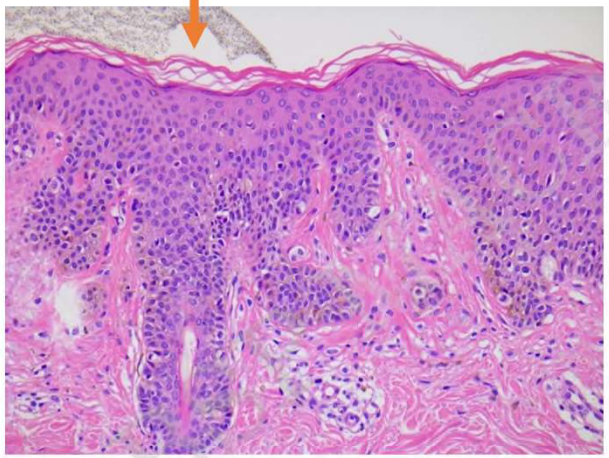

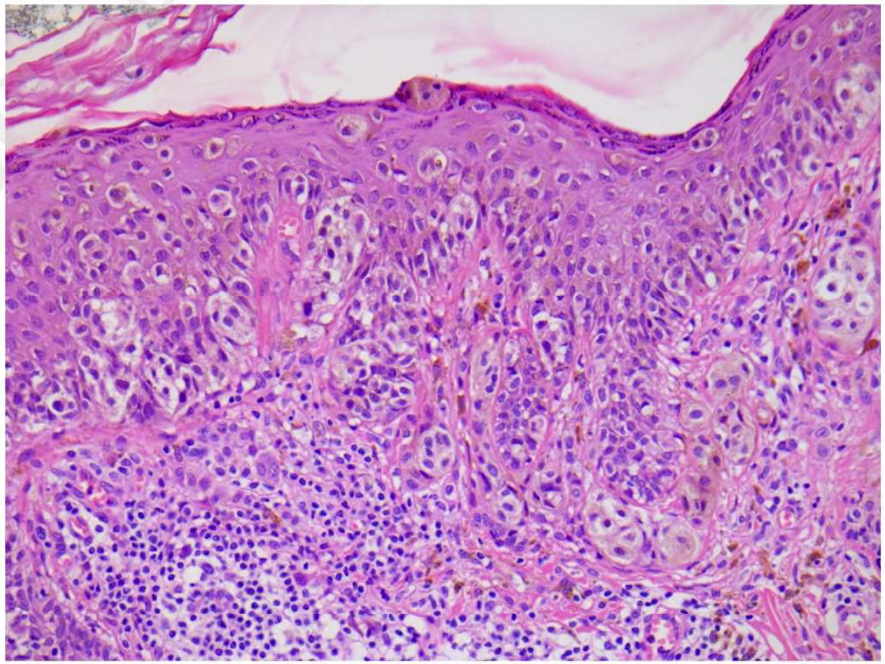

YPS & D OSCOPY COURSE 2023

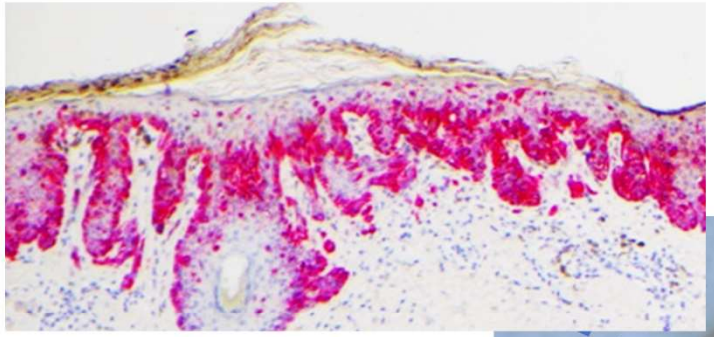

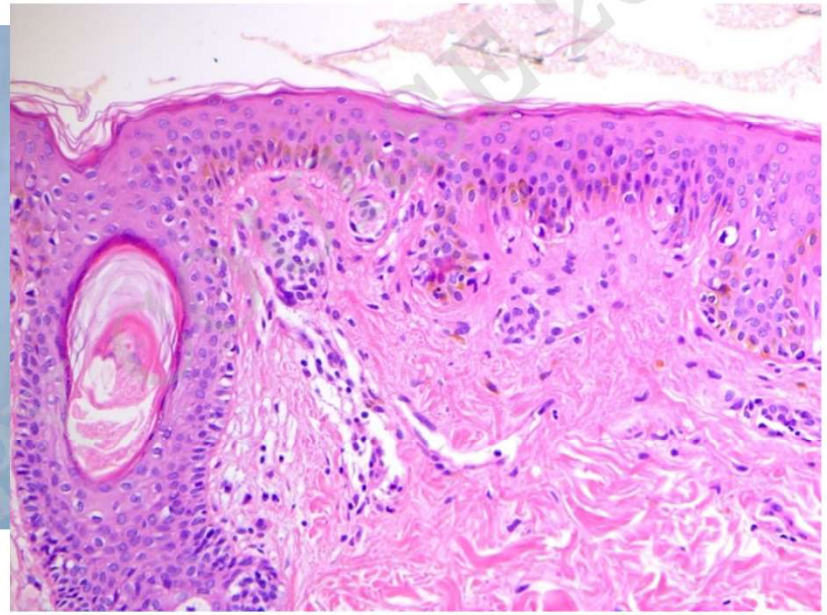

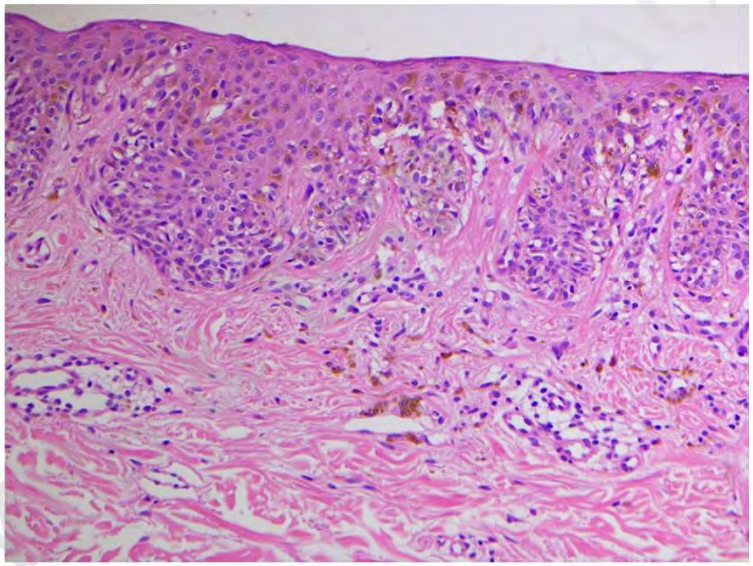

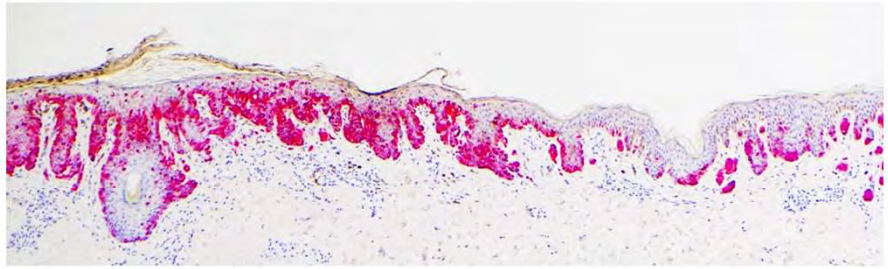

MICROSCOPE 2023

Different pathways of melanoma

Naevus-associated: 30-50%

- Separate pathway
- Thinner
- Younger
- Better prognosis
- Thorax
- Intermittent sun
- MC1R status

junctional



dermal



Melanoma de novo: 50-70%

- Older
- Thicker
- More aggressive



YPS & BSP MACROSCOPY COURSE 2023

Miescher - Unna naevi

A

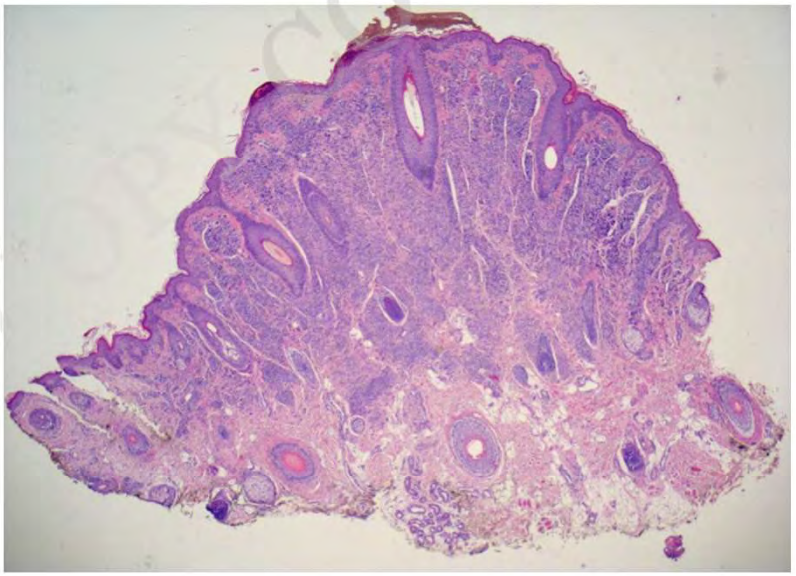

B

YPS & BSP MACROSCOPY COURSE 2023

Unna naevus

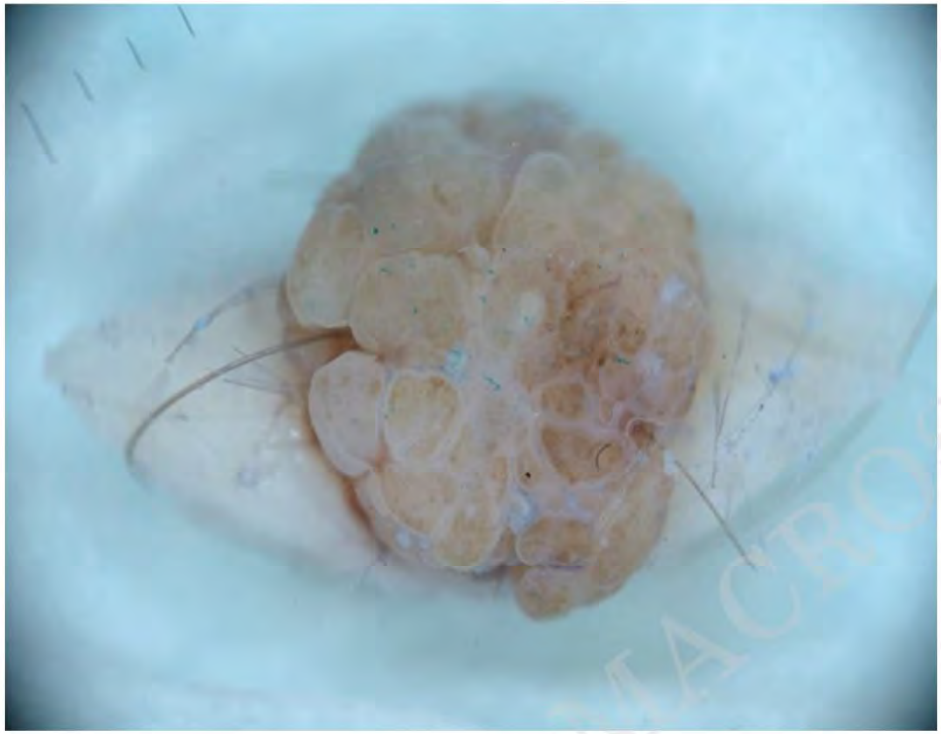

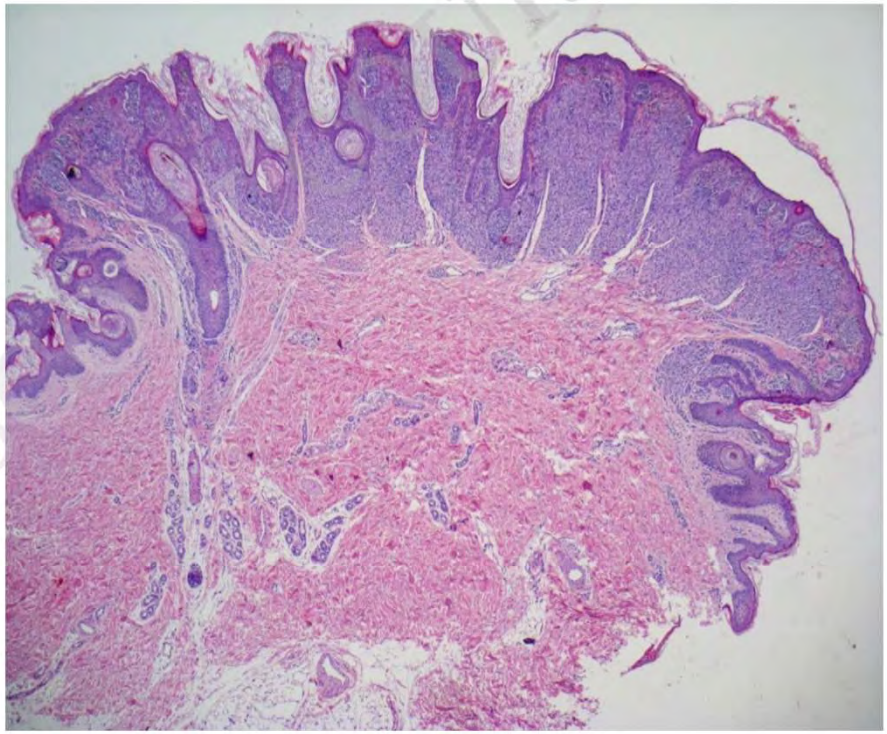

YPS & BSP MACROS COURSE 2023

YPS & BSP MACROSCOPY COURSE 2023

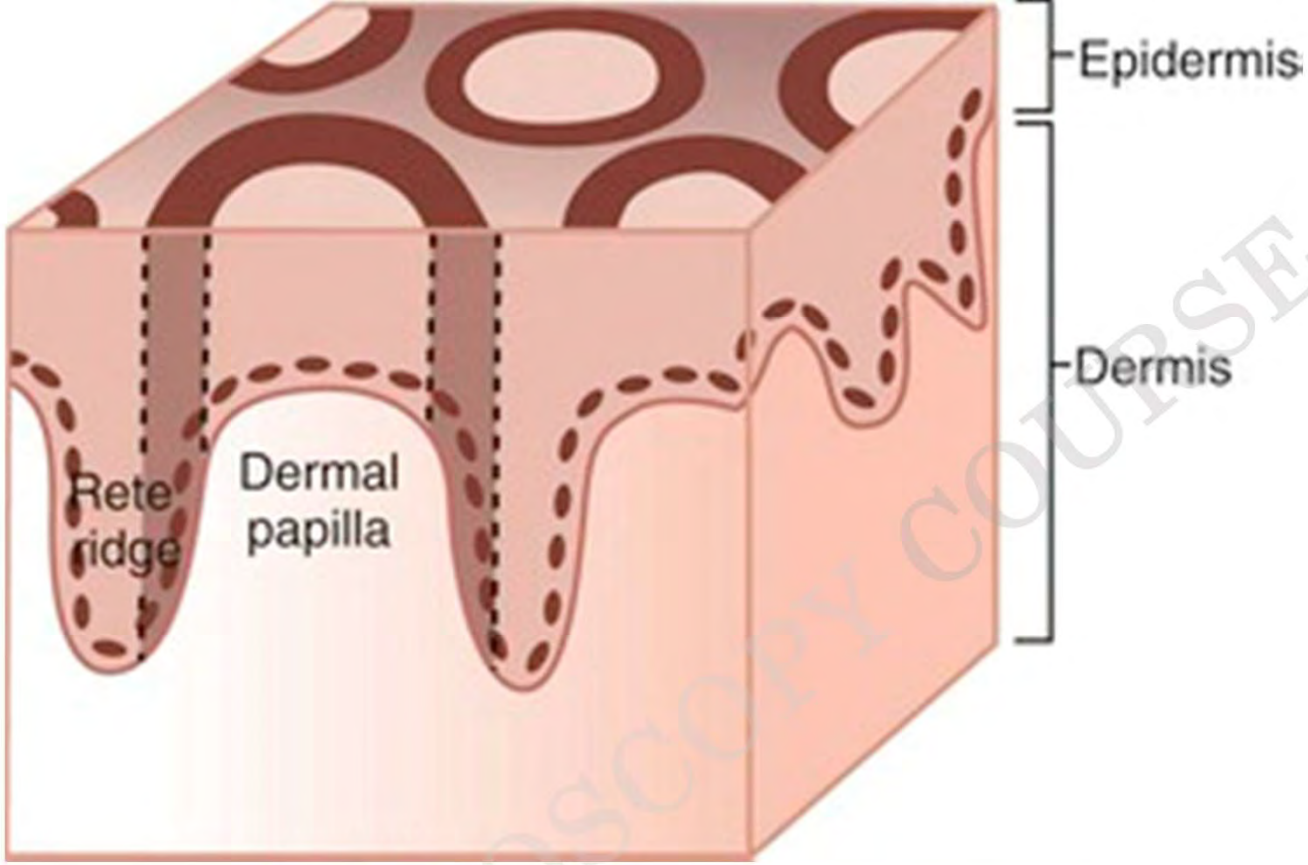

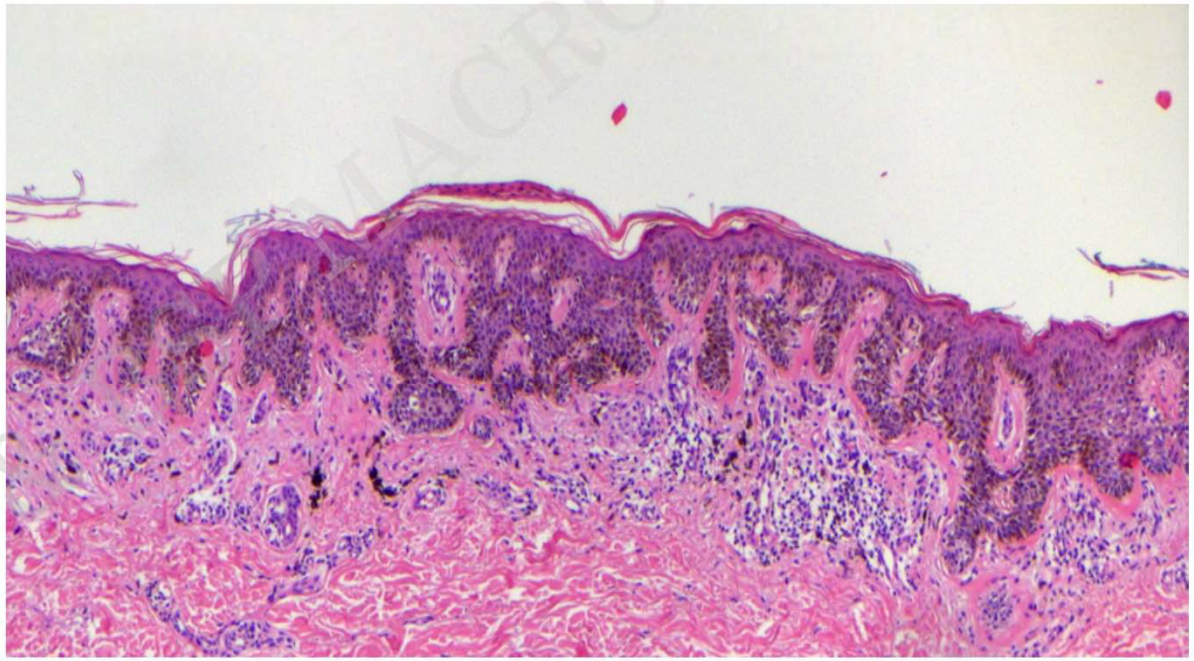

MACROSCOPY COURSE 2023

Flat reticular and hyperpigmented naevi

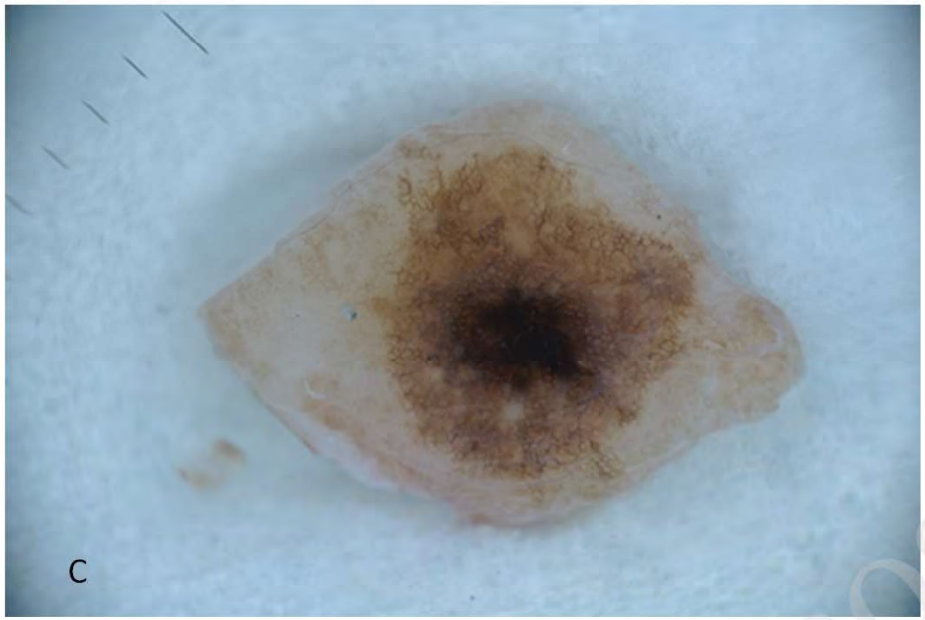
C

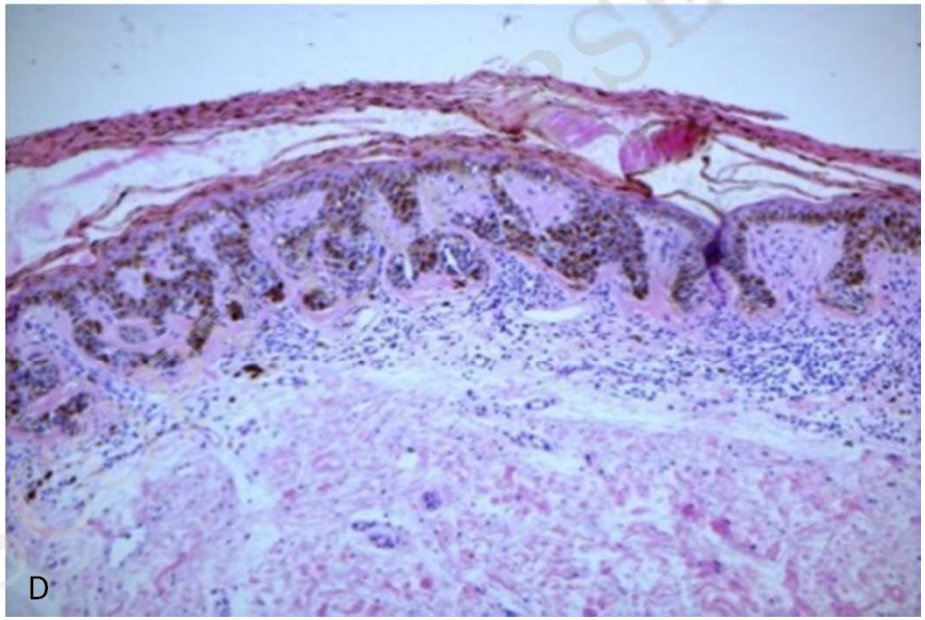
D

YPS & BSP MACROSE 2023

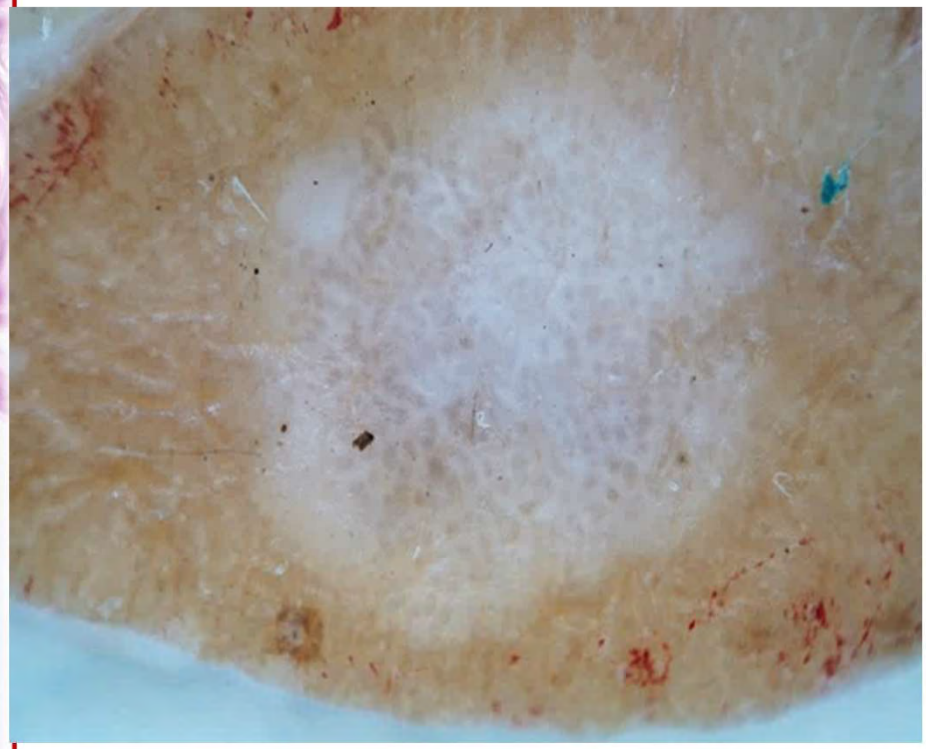

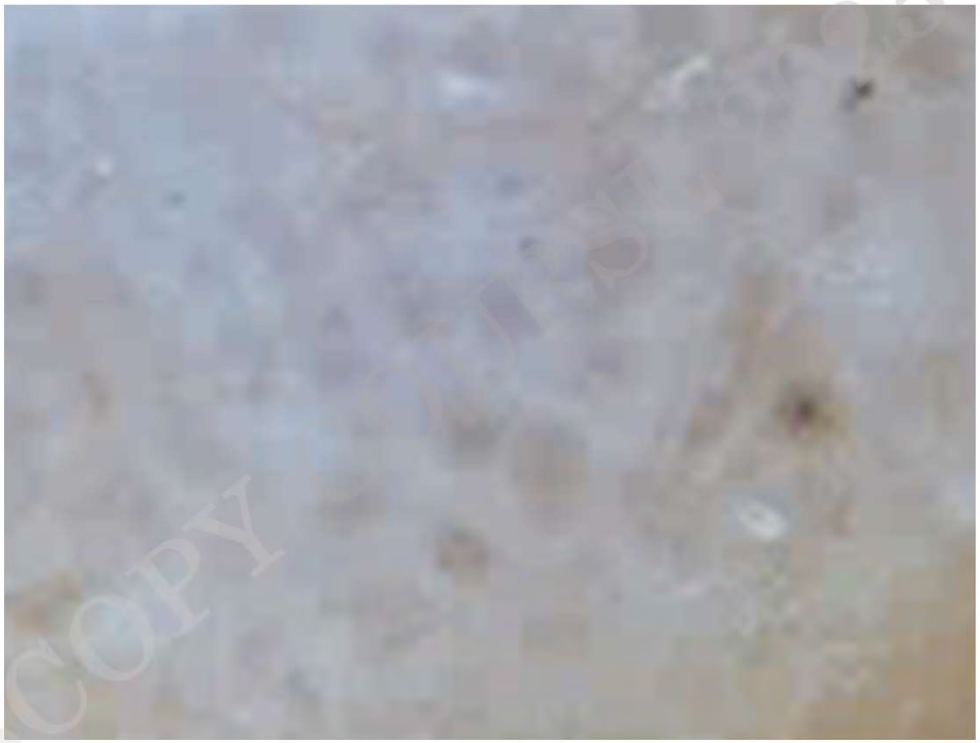

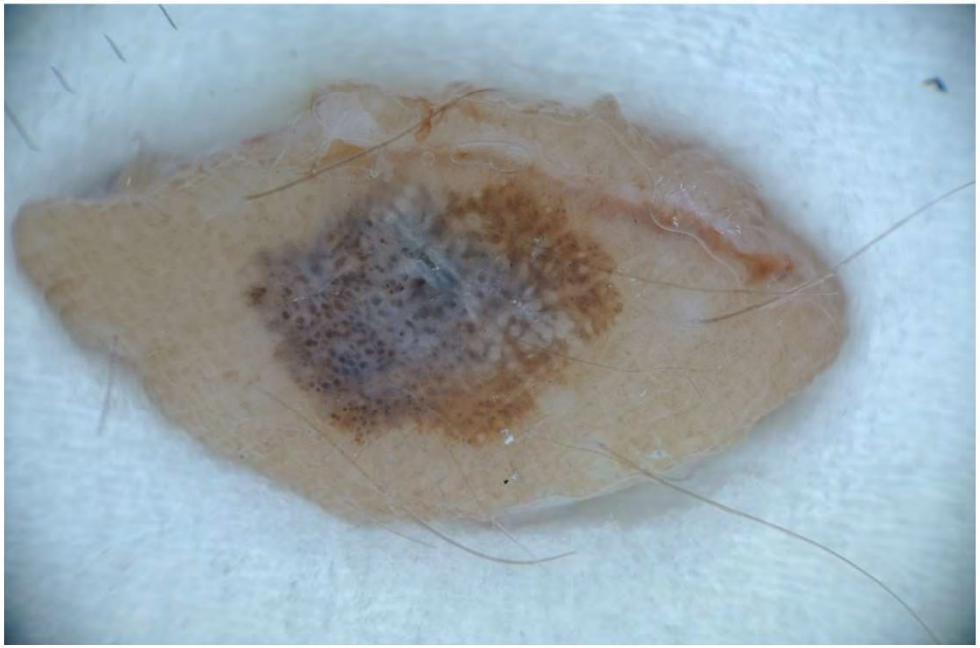

YPS & BSP MACROSCOPY

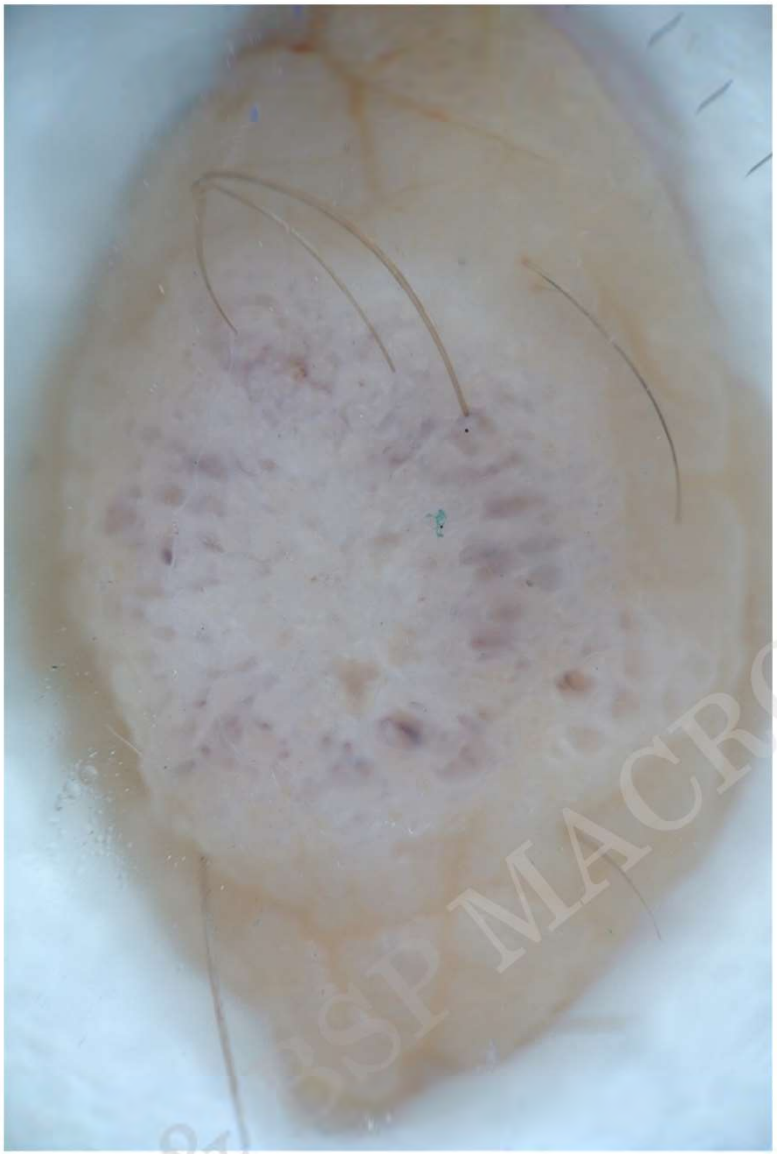

YPS & ISP MACROSCOPY COURSE 2023

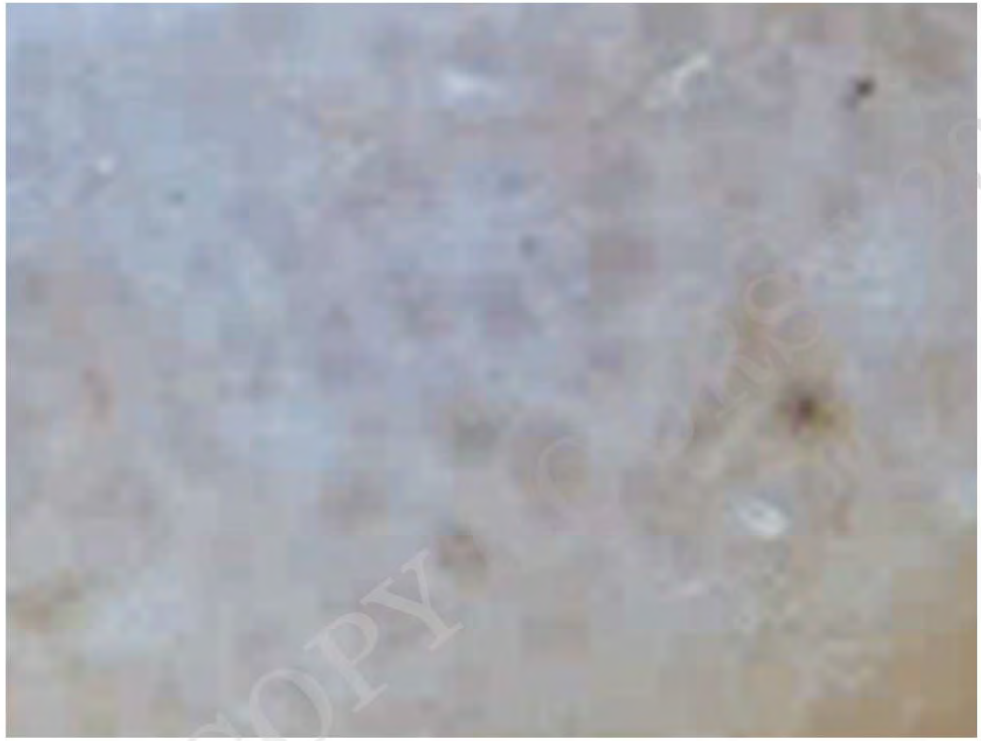

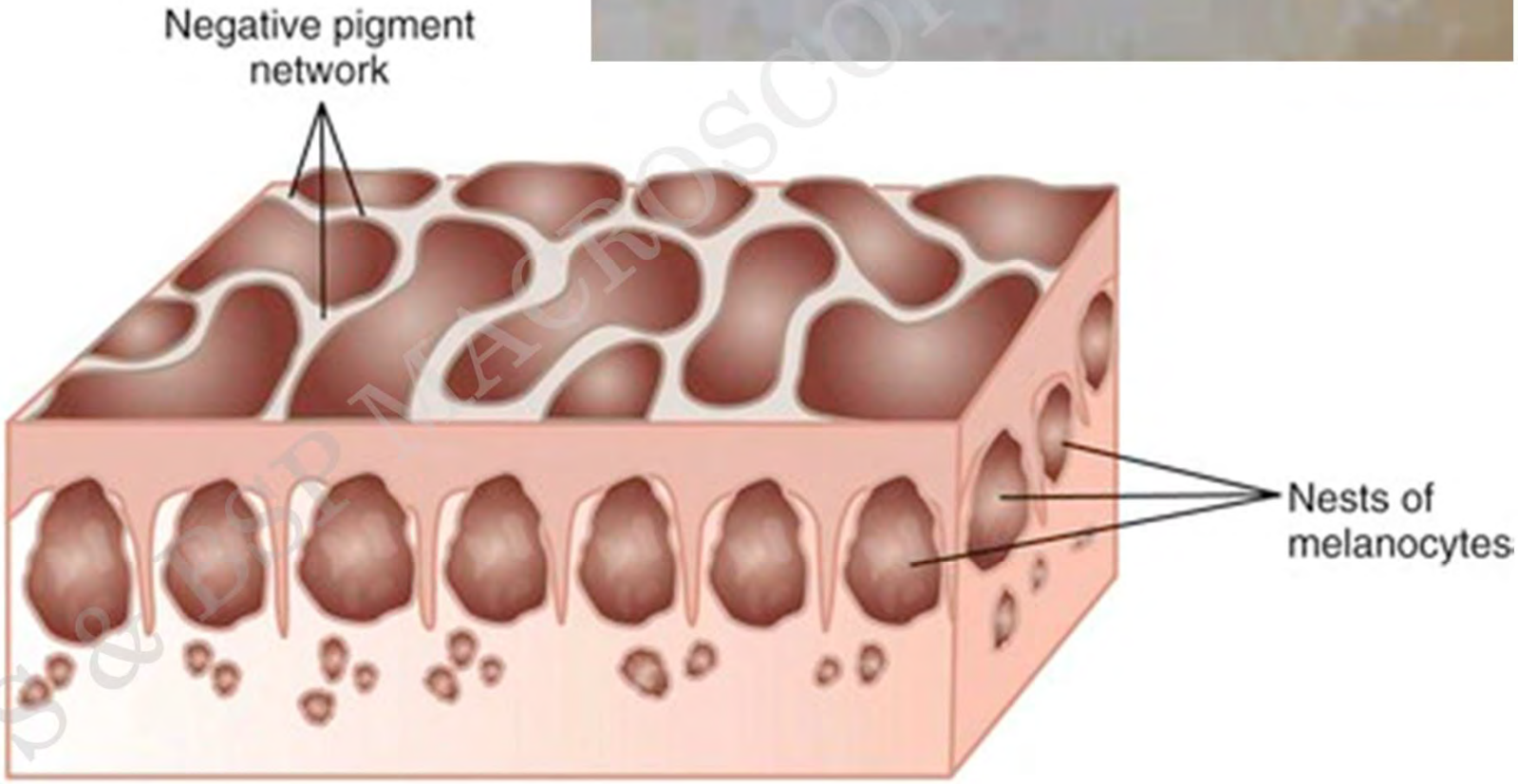

YPS & DP MACROSCOPY © 2023

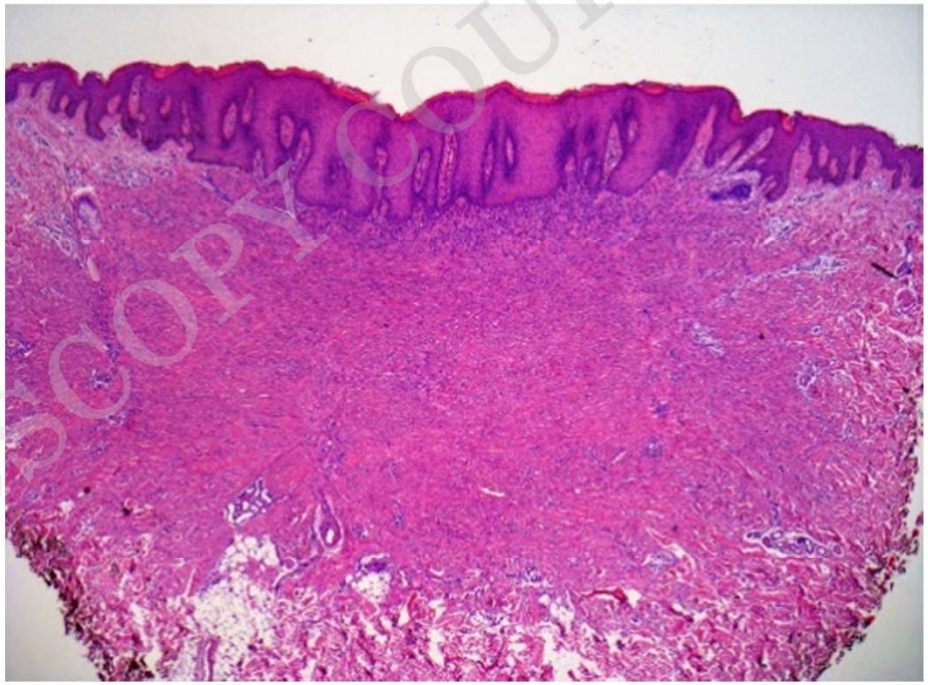

YPS & BSP MACROSCOPY COURSE 2023

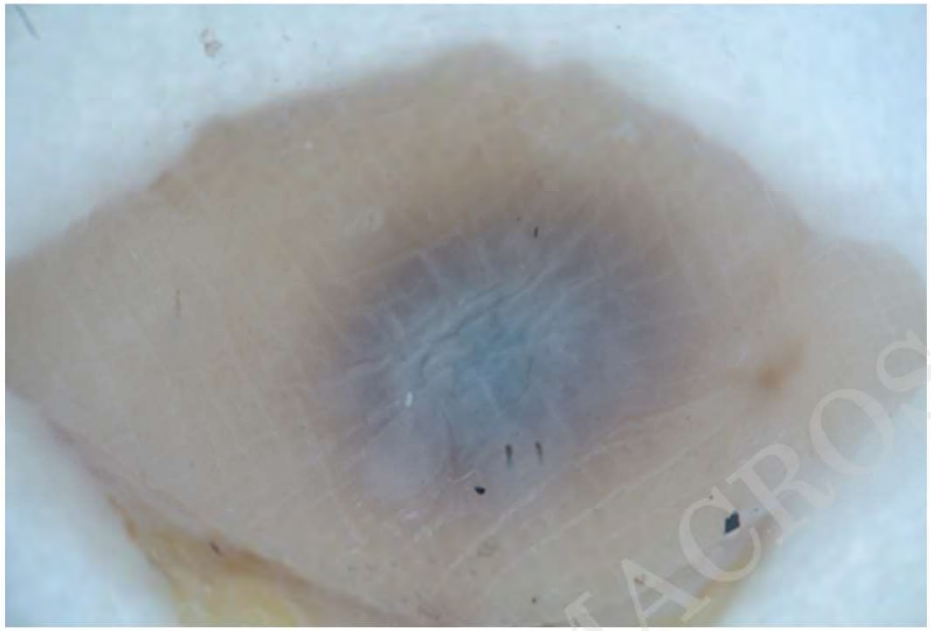

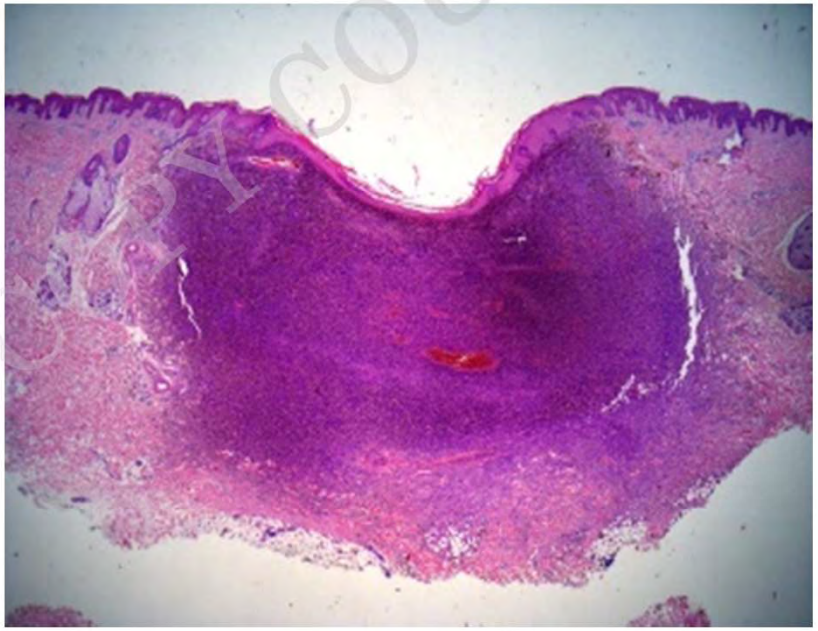

YPS & BSP MACROSCOPY COURSE 2023

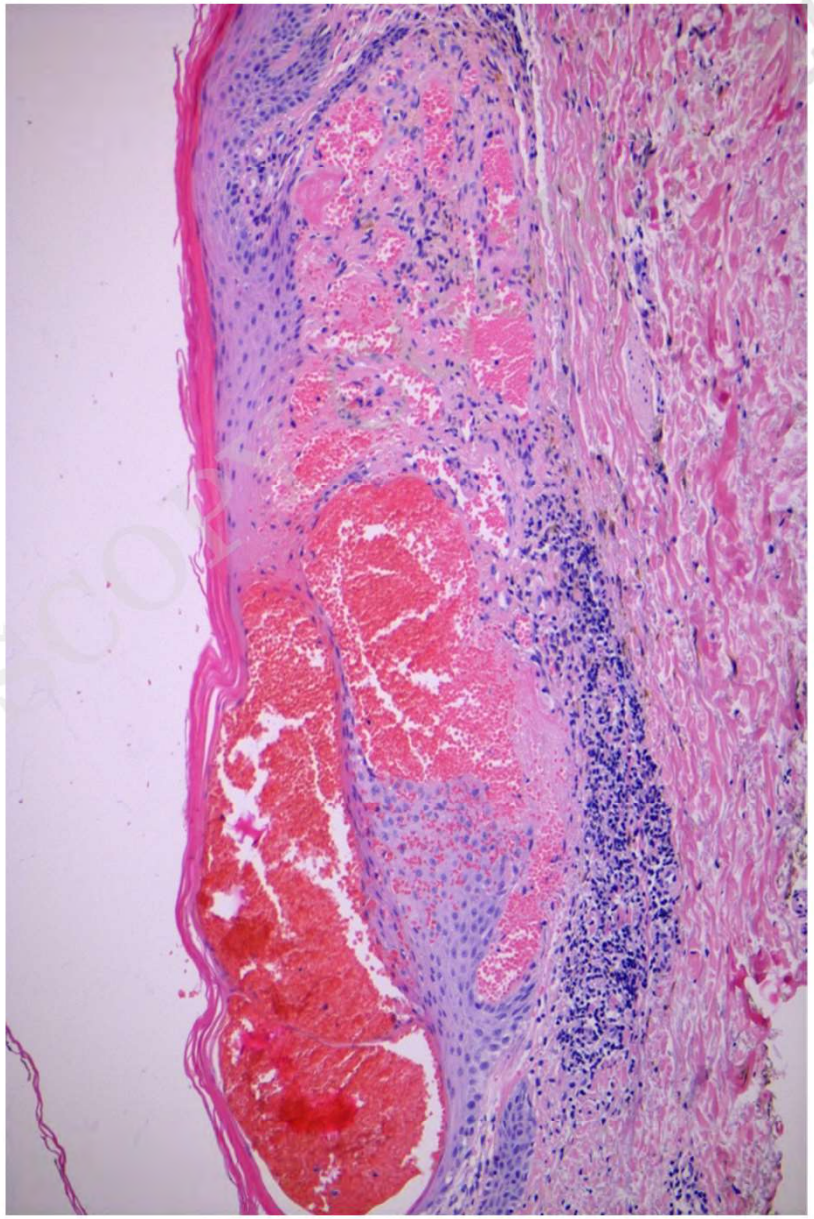

YPS & BSC MACROSCOPY 2023

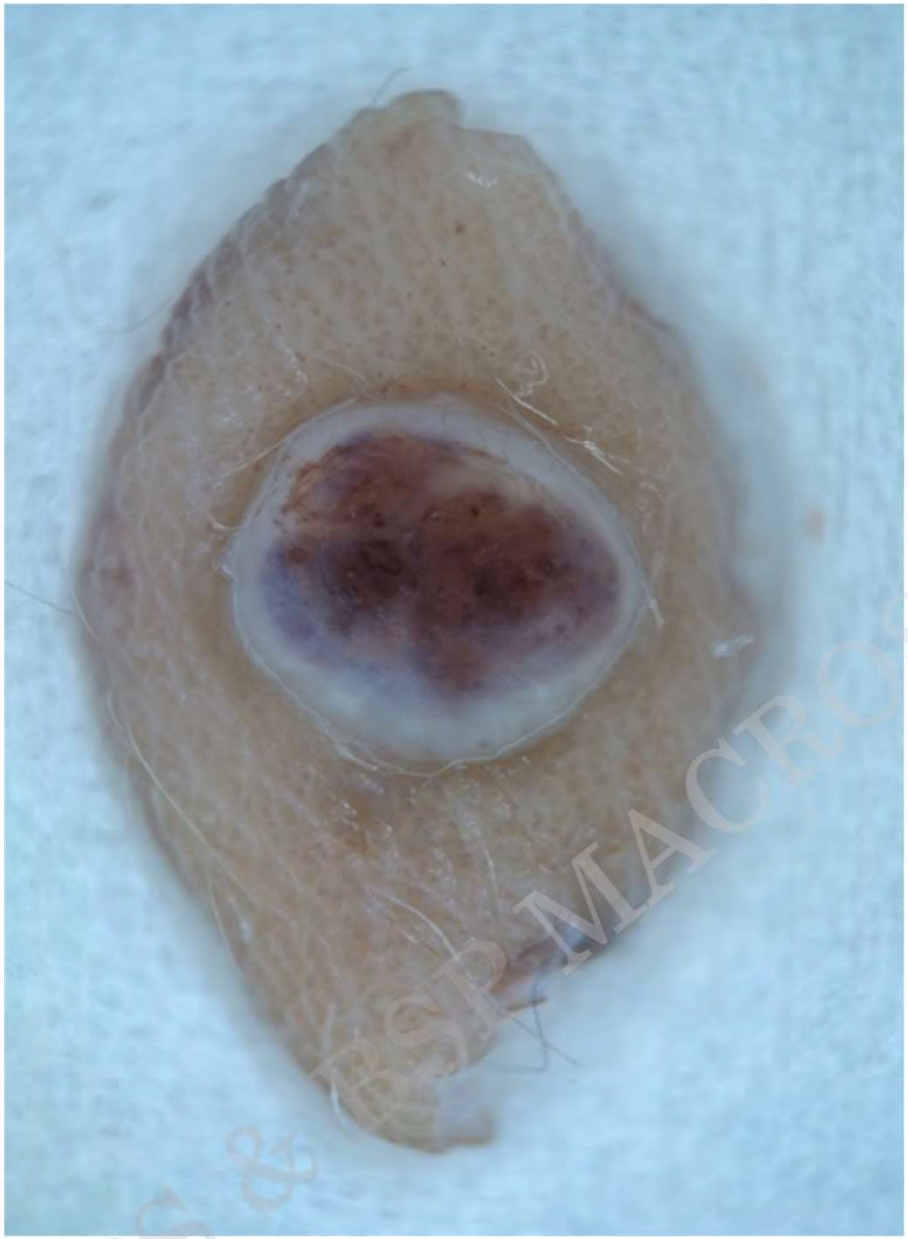

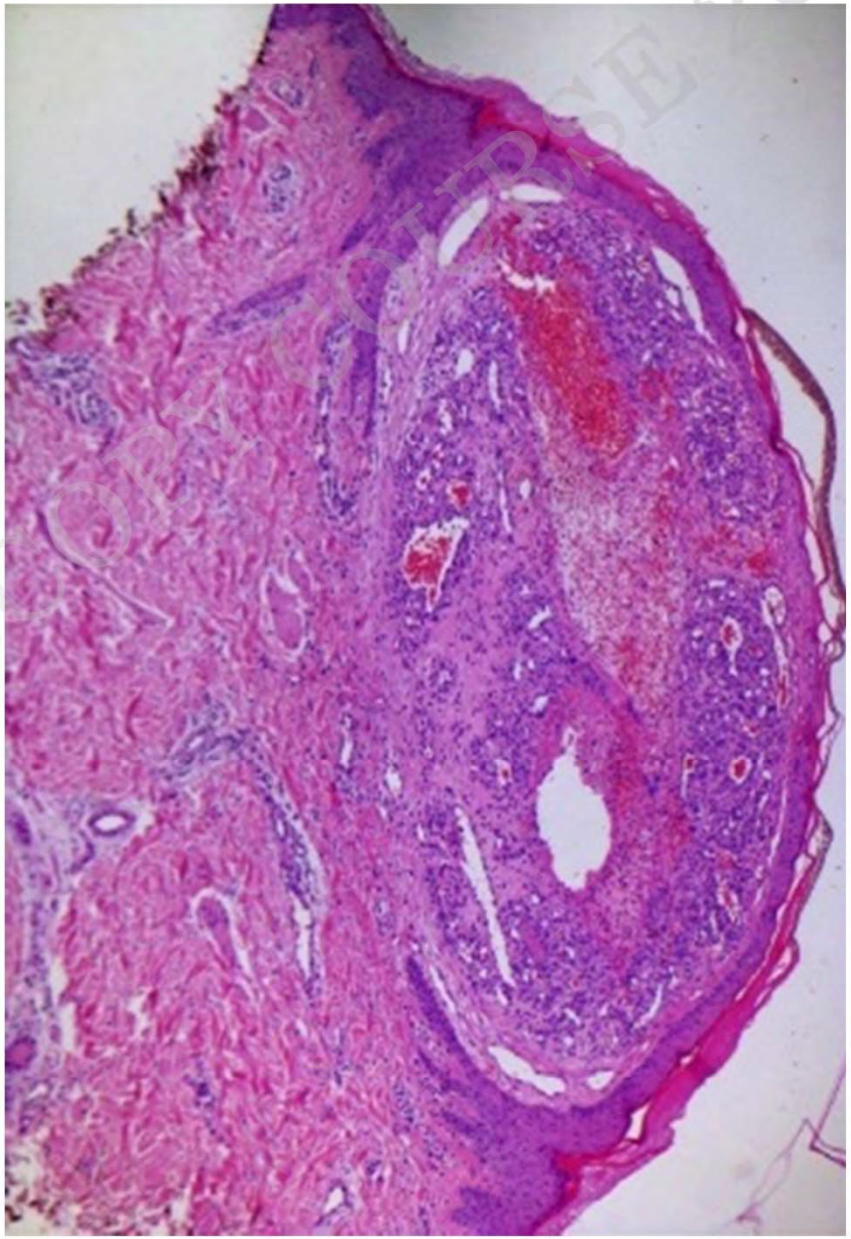

YPS & BSP MACROSCOPY COURSE 2023

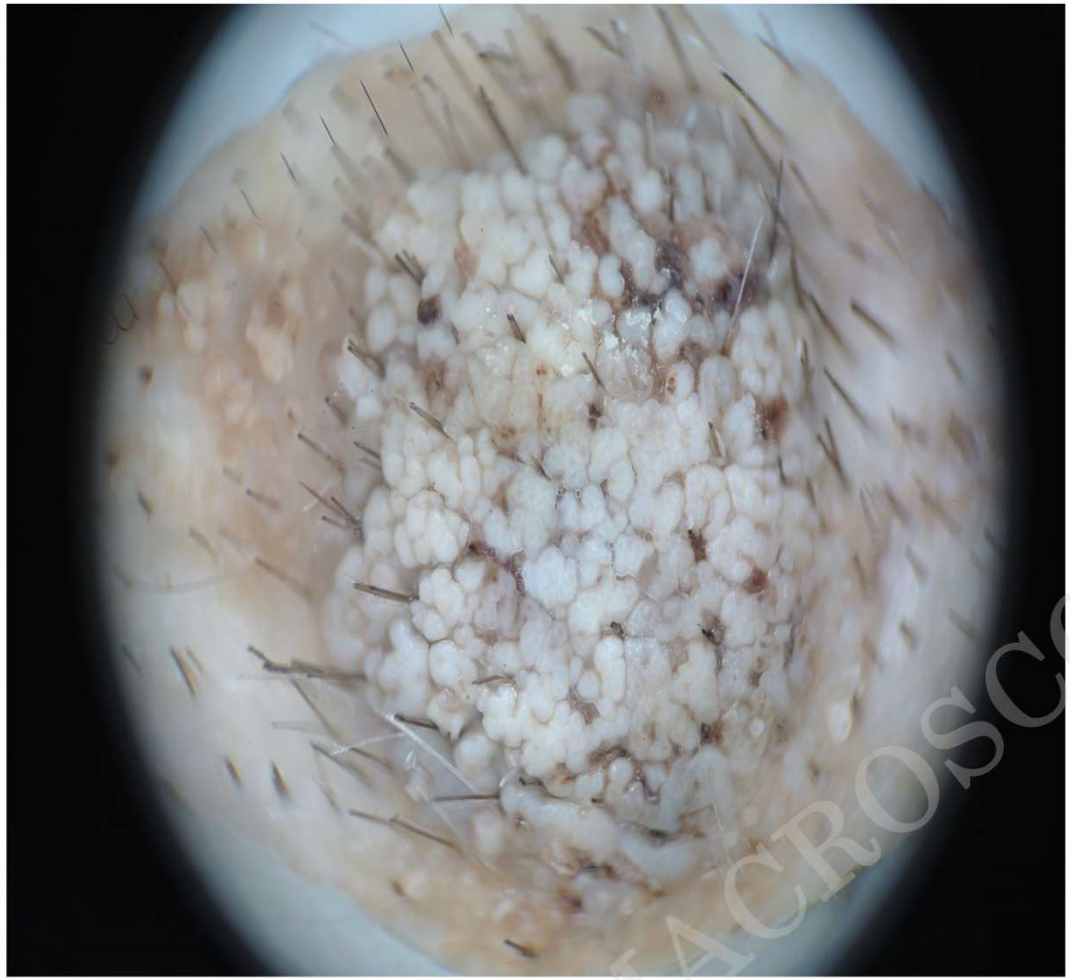

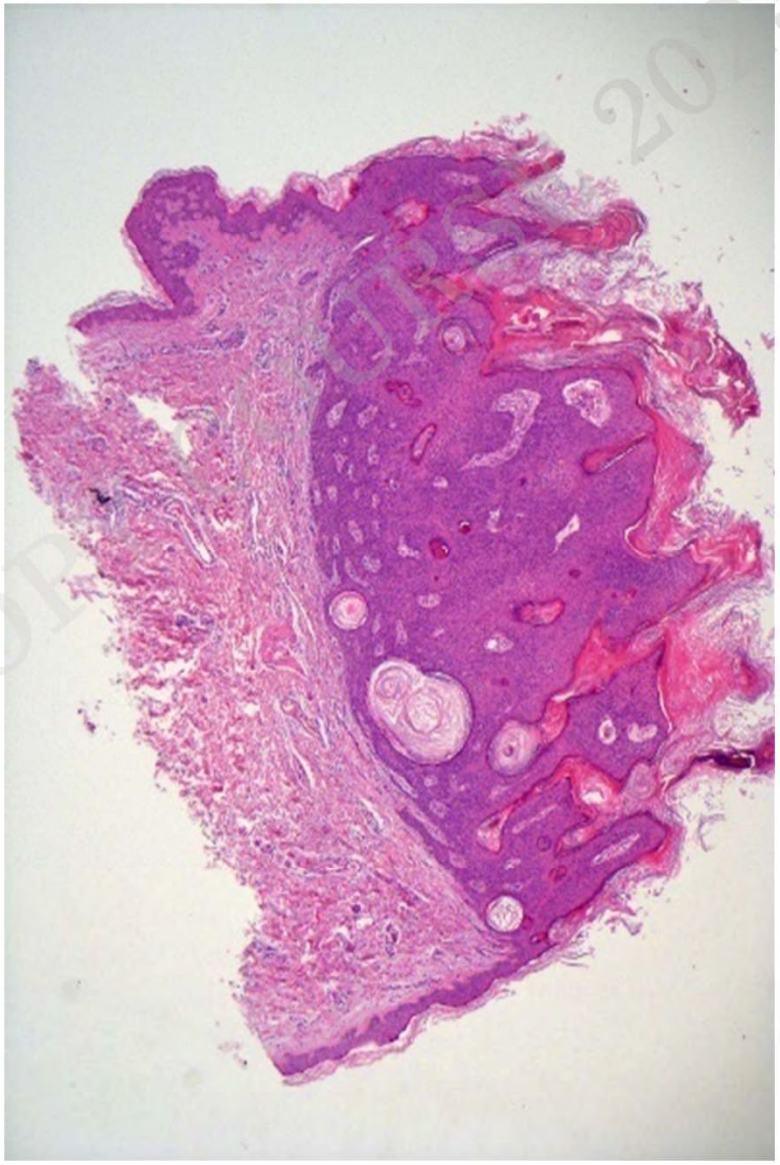

YPS & BSP MACROSCOPY COURSE 2023

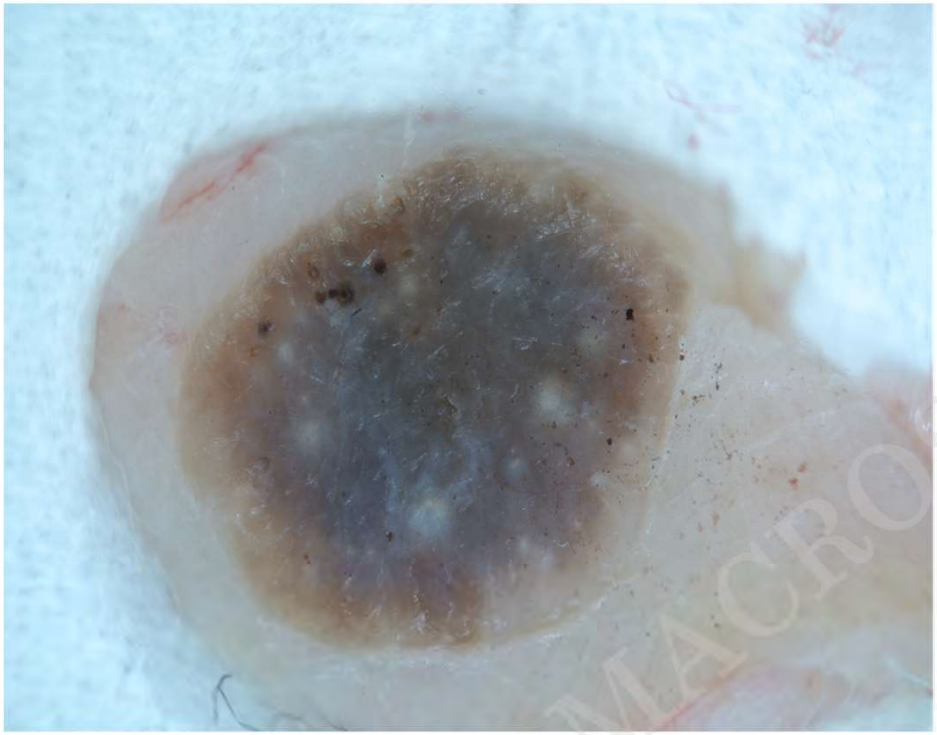

YPS & BSP MACROSCOPY COURSE 2023

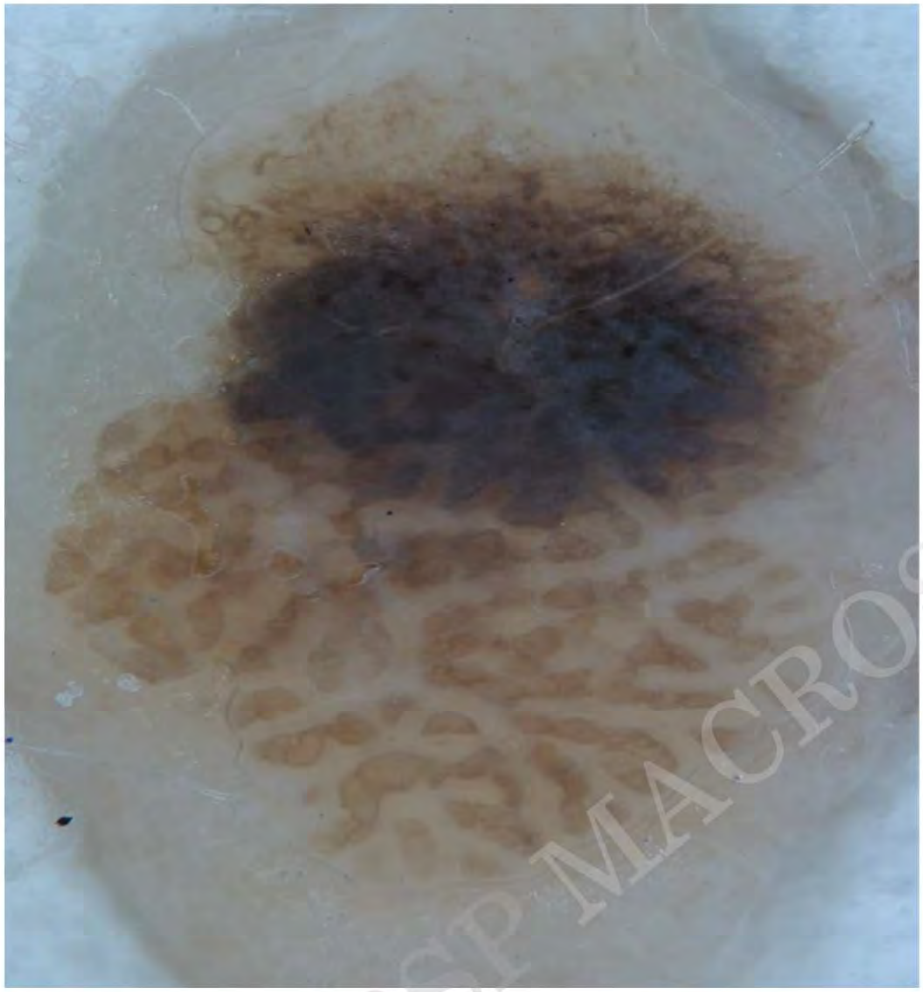

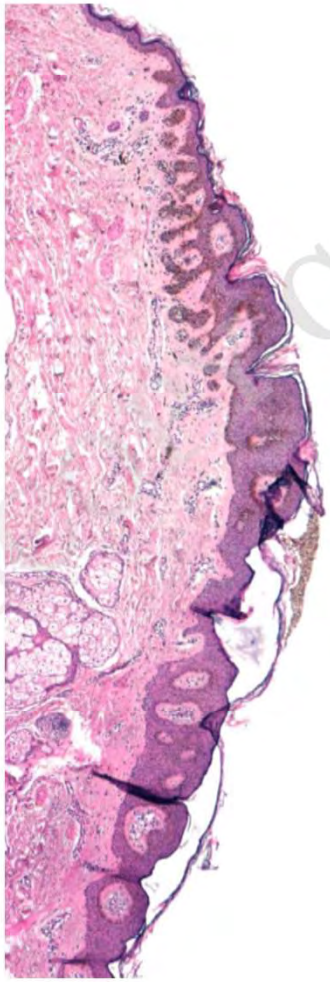

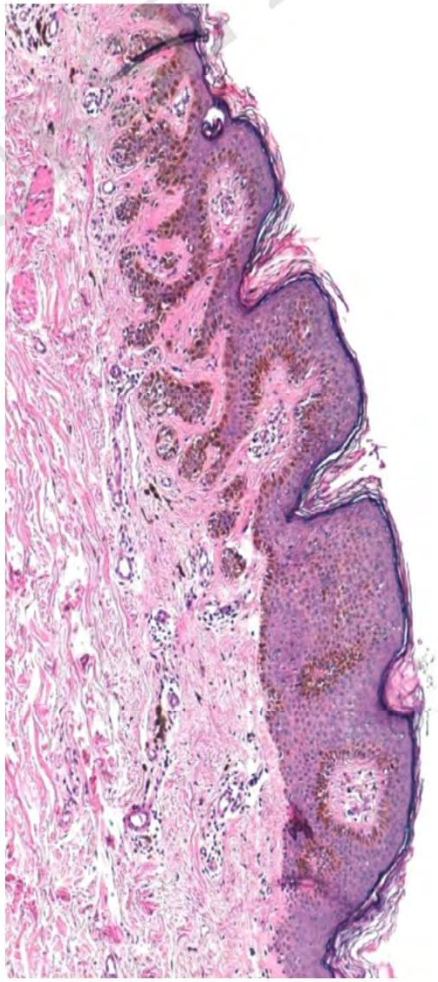

YPS & BSP MACROSCOPY COURSE 2023

Economically justifiable?

Extra macroscopy steps

Investment money and time?

YPS & BSP MACROSCOPY COURSE 2023

EVD-DD GC efficiency

- Mean # of blocks per case: **1.07**
  - Spring 2023
  - N = 13222

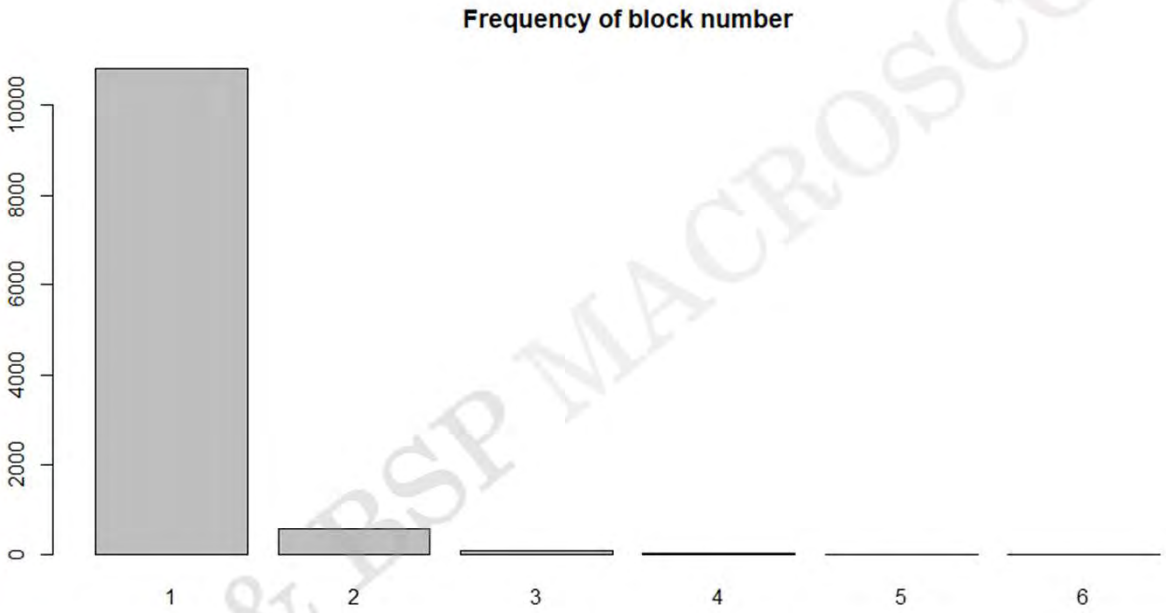

# HE's	# cases	% cases
0	41	0.31
1	12326	93.22
2	696	5.26
3	118	0.89
4	30	0.23
5	5	0.04
6	4	0.03
7	1	0.01
18	1	0.01

YPS & RSP MACROSCOPY COURSE 2023

it often is good to impressive – DEEPER SECTIONS

End of June-end of July: DS: 142/1061 cases = 13.3%

DS_type	total	perc
DS atypisch epitheliaal letsel	15	10.56
DS atypisch melanocytair letsel	75	52.82
DS fragmenten ontbreken	1	0.7
DS inflammatoir	5	3.52
DS letsel nog niet of onvoll. zichtbaar	28	19.72
DS letsel of epid tangentieel aangesn	1	0.7
DS markering niet zichtbaar	2	1.41
DS opsnijden	1	0.7
DS snedevlakken	14	9.86

DSNI: 3 cases = 0.2%

1/10 atyp epith
1/2 atyp melan
1/5 lesion?
1/50 new inform

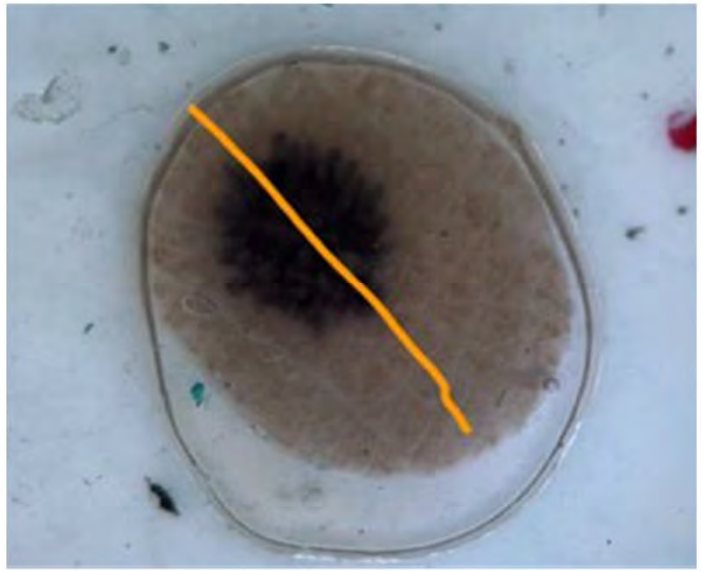

YPS & BSP MACROSCOPE COURSE 2023

Statistics: TX VERO!

YPS & BSP DERMOSCOPY COURSE 2023

EVD-DD GC efficiency

- Mean # of representative lamellae: 97%

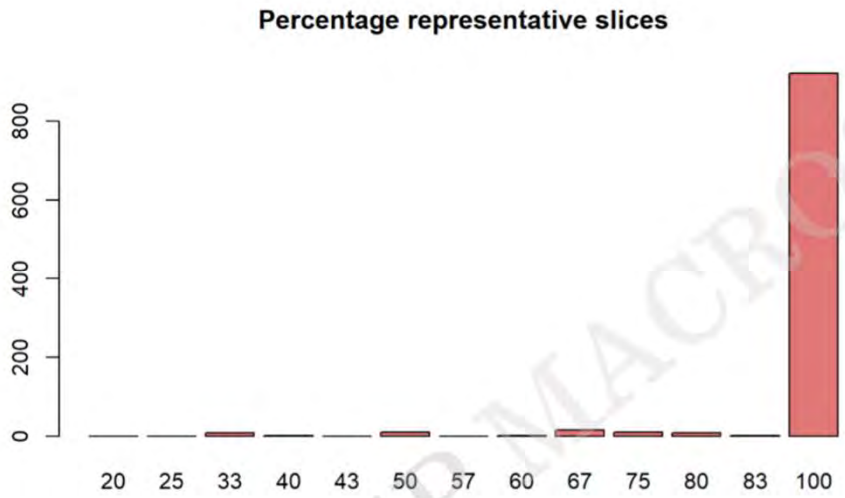

% representative lamellae	# samples	% samples
20	1	0.1
25	1	0.1
33	9	0.91
40	2	0.2
43	1	0.1
50	12	1.21
57	1	0.1
60	3	0.3
67	17	1.72
75	11	1.11
80	9	0.91
83	3	0.3
100	921	92.94

YPS & BSP MACROSCOPY COURSE 2023

Cfr. traditional method

T-nummer	lokalisatie	lengte excisie (cm)	maximale diameter letsel (cn	aantal cassettes	aantal lamellen	representatieve lamel	tumor in kapje	diepers	reden
T23-15037	abdomen	1,5 x 0,8 x 0,5	0,6	2	5	3	nee	nee	
T23-15033	onderbeen	0,8 x 0,6 x 0,3	0,5	2	4	2	nee	nee	
T23-15024	flank	2,1 x 1 x 0,6	0,8	4	6	3	nee	nee	
T23-15102	onderarm	2,0 x 0,8 x 0,3	0,5	3	7	2	nee	ja	voor de zekerheid
T23-14242	rug	2,8 x 1,4 x 1,2	1,2	3	7	4	nee	nee	
T23-13392	borst	1,7 x 1,0 x 0,8	1,0	2	5	3	nee	ja	voor de zekerheid
T23-13502	buik	1,5 x 0,8 x 0,5	1,5	3	4	3	ja	ja	snijvlak kapjes, DTO
T23-00231	buik	0,6 x 0,3 x 0,2	0,3	1	2	2	nee	nee	
T23-00214	interscapulair	1,2 x 0,9 x 0,5	0,8	2	4	4	ja	nee	
T23-00329	borst	1,5 x 0,5 x 0,8	0,5	2	4	3	ja	nee	
T23-00710	rug	1,5 x 1,0 x 0,6	0,6	2	5	4	ja	ja	snijvlak kapjes, DTO

26 bloc/11 cases =2,4 bloc/case

13328 naar 31733 blocs

1,07 2,4

Represenatief :

35/53=66%

Deeper cuts : 4/11=36%

UMC Utrecht TX

SARAH!

YPS & DSP MACROSCOPY COURSE 2023

UZ gent dermato

1,5 bloc per case

Som alle sneden	87
Som alle sneden waarin letsels	37
	0,425287
	43%

YPS & BSP MACROSCOPY COURSE 2023

	bloc	repres	deeper
Dermpat	1,07	97 %	13,3%
UZ	1,5	43%	?
UMC	2,4	66%	36%

IPS & BSP MACROSCOPY COURSE 2023

Cost efficiency EVD-DD : 13222 stalen

Direct costs

totaal kost zonder afschrijvingen en indir kosten *	
4,1	receptie
4,9	proc-macro
3,9	blok
4,6	kleuren
9	immunos
26,5	euro per staal



Number of blocs increases with 18405

18405 x 3,9 + 18405 x 4,6= 71780 + 84663 = 156443 savings in 6m

Correction more macro time from 1 min to 3 min per sample from FE
laborante : +30 000 euro / year
Savings more than 200,000 euro
Without savings on deeper cuts : van 30-50 % naar 13,3% : *30% =7000
deeper extra x 8,5^{e}= 59500 e
Total savings 250ke/year

YPS & BSP IHC CROSSOVER COURSE 2023

Time Efficiency!

Time management no screening of negative tissue
Focus, concentration on hot areas of lesion
Internal control of accuracy

YPS & BSP MACROSCOPY COURSE 2023

Digital ERA

- Area/surface/number of slides to scan and stock!
  - Double capacity of scanners



YPS & BSP MACROSCOPY COURSE 2023

Take Home

Learn dermatology and dermoscopy

Allow and upgrade technicians to participate in the diagnostic proces

Educate them in case specific clinicopathologic macro to produce slides with representative and diagnostic tissue

Resulting in a satisfied dermatologist

well sleeping pathologist with appropriate investment off his time and energy

And a happy and healthy patient





YPS & BSP MACROSCOPY COURSE 2023

THANK YOU

YPS & BSP MACRO COPY